

# ECHOCARDIOGRAPHIC MORPHOLOGICAL EVALUATION OF TETRALOGY OF FALLOT IN SULAIMANI PEDIATRIC CARDIOLOGY DEPARTMENT /KURDISTAN /IRAQ



Aso faeq Salih <sup>a</sup>, Dalya Muhammad Rashid <sup>b</sup> and Adnan M H Hamawandi <sup>a</sup>

Submitted: 23/3/2018; Accepted: 7/7/2018; Published 1/8/2018

## ABSTRACT

### *Background*

Congenital heart diseases (CHD) are the most common of all congenital malformations. Tetralogy of Fallot (TOF) is the most common of the cyanotic defects. TOF consists of four major abnormalities occurring together; subpulmonary infundibular stenosis, ventricular septal defect, aortic overrides and right ventricular hypertrophy. Classification of Tetralogy of Fallot according to the pulmonary trunk is the first study done in Sulaimani, up to our knowledge.

### *Objectives*

To determine the morphological classification of tetralogy of Fallot according to the pulmonary trunk in Sulaimani pediatrics teaching hospital – cardiology department.

### *Patients and Methods*

This is a retrospective study conducted in Pediatric teaching hospital in Sulaimani for a total 308 cases from 1<sup>st</sup> Aug 2006 - 1<sup>st</sup> Aug 2012. The source of information was the medical and echocardiography records in pediatric cardiology department, Sulaimani Teaching Hospital.

### *Results*

Among 308 cases, 109 cases were hypoplastic pulmonary branches, 185 cases were good pulmonary branches, 11 cases were unclear and 3 cases were absent pulmonary branches. Tetralogy of Fallot are common in children age groups about 205 cases, 86 cases of infants, 14 cases of adults and 3 cases of neonates. Tetralogy of Fallot had associated lesions like patent ductus atriosus (68) cases, ventricular septal defect (86) cases, atrial septal defect (26) cases, aortopulmonary collaterals (35) cases and aortic regurgitation (31) cases. 125 of 308 cases of Tetralogy of Fallot were operated.

### *Conclusions*

Good pulmonary branches are common type of Tetralogy of Fallot. Tetralogy of Fallot is common in children age groups, slightly more common in males than in females. Additional ventricular septal defect and patent ductus atriosus are common associated lesions of Tetralogy of Fallot.

**Keywords:** *Tetralogy of Fallot, Echocardiography, Associated anomaly.*

---

<sup>a</sup> Department of Pediatrics, College of Medicine, University of Sulaimani.

Correspondence: [asofaek@hotmail.com](mailto:asofaek@hotmail.com)

<sup>b</sup> Sulaimani Pediatric Teaching Hospital, Sulaimani, Iraq

## INTRODUCTION

Tetralogy of Fallot (TOF) accounts for approximately 3.5-4% of all heart malformations and is the most common of all cyanotic defects <sup>(1, 4)</sup>.

Although TOF consists of four constant abnormalities, the condition actually represents a morphologic spectrum from cases with minimal pulmonary stenosis to cases with severe pulmonary obstruction as is represented in the most extreme form of TOF, pulmonary atresia with ventricular septal defect (VSD) <sup>(4, 5)</sup>.

TOF is slightly more common in males than in females <sup>(4)</sup>. The hypertrophy of the subpulmonary infundibulum give rise to the right ventricular outflow tract obstruction (RVOTO) that is the hallmark of this condition <sup>(5)</sup>.

Abnormalities of the pulmonary arteries themselves can also occur with stenosis and hypoplasia being common. There can also be anomalous origins of one or both pulmonary arteries, usually from part of the aorta <sup>(6)</sup>.

Associated Lesions are Pulmonary atresia 12% <sup>(7)</sup>, Atrial septal defect 20% <sup>(7)</sup>, Additional VSD 5% <sup>(7, 8)</sup>, Atrioventricular septal defect (AVSD) 1-3% <sup>(5-7)</sup>, Patent ductus arteriosus (PDA) <sup>(7, 8)</sup> 4-6%, Dextrocardia <sup>(7)</sup> 2%, Right aortic arch <sup>(6, 7, 8)</sup> 15-25%, Coronary artery anomaly <sup>(9)</sup> 3%, Aberrant subclavian artery <sup>(6, 10)</sup> 3-8%, Aorto Pulmonary Collaterals (APC) <sup>(8)</sup> 2% .

The evolution of cardiac surgery has revolutionized the management of TOF. In 1944 the first Blalock-Taussig anastomosis was performed <sup>(3, 5)</sup>.

In 1954 Lillehei and colleagues performed the first successful intracardiac TOF repair <sup>(3)</sup>. The goals of intracardiac repair are to close the VSD and relieve the RVOTO <sup>(6)</sup>.

The long-term outcome of treatment of TOF depends primarily on the size and anatomy of the pulmonary arteries and whether a competent native pulmonary valve remains after operation <sup>(11)</sup>.

The aim of this study is to determine the morphological types of Tetralogy of Fallot by Echocardiography, depending on the size and development of the pulmonary trunk and its branches in Sulaimani Pediatric cardiology department.

## PATIENTS AND METHODS

This is a retrospective study conducted in Pediatric Teaching Hospital in Sulaimani. We collected 308 cases from Aug 1<sup>st</sup> 2006 – Aug 1<sup>st</sup> 2012. All children with the confirmed diagnosis of Tetralogy of Fallot were included in the study. The pediatric cardiology department in Pediatric Teaching Hospital in Sulaimani is the only and main referring center in which all other hospitals from Sulaimani around provinces send their patients. Patients that referred from the other area of Kurdistan and patient from the south of Iraq were included in the study.

The source of information was the medical and echocardiography records of the pediatric cardiology department from Sulaimani teaching hospital, all of the patient seen and evaluated by the same operator. The suspected CHD patients who showed symptoms like poor feeding, failure to thrive, respiratory problem, discrepancy in pulse, cyanosis, heart murmur, abnormal chest X-ray, or strong family history had been subjected for further clinical diagnosis like X-ray, ECG and echocardiographic examination for the conformation of the CHDs. Two dimensional and Doppler (spectral and color) echocardiography examinations were obtained for each patient using a commercial instrument with 3V2C and 7V3C MHZ transducers (adjusted according to patient chest wall thickness) Acuson Cypress, USA made, supplied by Siemens Company. The echo measurements were recorded according to the standards recommended by the American society of Echocardiography and defined accordingly, which usually allows clear demonstration of all the intracardiac anatomy.

Prevalence, age and sex specific frequency of Tetralogy of Fallot (TOF), its anatomical classification according to anatomy of pulmonary arteries and its branches was done. Associated cardiac defects such as Patent Ductus Arteriosus (PDA), Aortic incompetence (AR), and other findings recorded on sheets and the mean, standard deviation, median parameters and frequency were entered.

Patients were followed up in the department for the mentioned period of the study by scheduled visits and, assessed clinically and echocardiographically. For those patients who had surgeries, detail and types of the surgical treatment, place of operation recorded in addition to postoperative, non-operative complication and deaths recorded.

Each returned questionnaire given an identity number (ID). Prior to data entry and analysis, the questions of study coded. The data entered into a Microsoft Excel Spread sheet, after data cleaning; the data transported into SPSS (Statistical Package for the Social Sciences- version16) package software program for statistical analysis.

Descriptive statistics (numbers, and percentages) calculated for all variables, as well as analytical statistics done to find the relations between variables. By using the appropriate statistical tests such as Chi-square, and fisher exact test.

A p-value < 0.05 considered as significant.

## RESULTS

This study comprises 308 cases, 109 cases (35%) had hypoplastic pulmonary branches, 185 cases (60%) had good pulmonary branches, 11 cases (4%) had unclear pulmonary branches and three cases (1%) had absent pulmonary valve, as shown in figure (1).

Our study revealed that from the sum of 308 cases, three cases (1%) were neonates, 86 cases (27.9%) were infants, 205 cases (66.6%) were children and 14 cases (4.5%) were adults.

Among which 237 cases( 76.9%) from sulaimani governerate and 71 ( 23.1%) from out of governerate.

The study shows that 173 cases (56.2%) were males and 135 cases (43.8%) were females from the sum of 308 cases.

In this study from the sum of 308 cases, 285 cases (93%) are still a live, 13 cases (4%) passed away, and 10 cases (3%) were lost on follow up.

Several lesions can co-exist with TOF, among 308 cases, 68 cases (22.1%) had PDA; statistically P-value is 0.001, which is more significant, as shown in table (2) and (3).

86 cases (27.9%) had additional VSD; statistically P-value is 0.0001, which is more significant, as shown in table (2) and (3).

Twenty-six cases (8.4%) had ASD; statistically P-value is 0.637, which is not significant, as shown in table (2) and (3).

Thirty-one cases (10.1%) had AR; statistically P-value is 0.733, which is not significant, as shown in table (2) and (3).

Thirty-five cases (11.4%) had APC; statistically P-value is 0.001, which is more significant, as shown in table (2) and (3).

Table (4) shows the number of cases that operated on and its subtype, approaches of repair, which it showed that transannular patch is the most popular way for repair among the patched on cases.

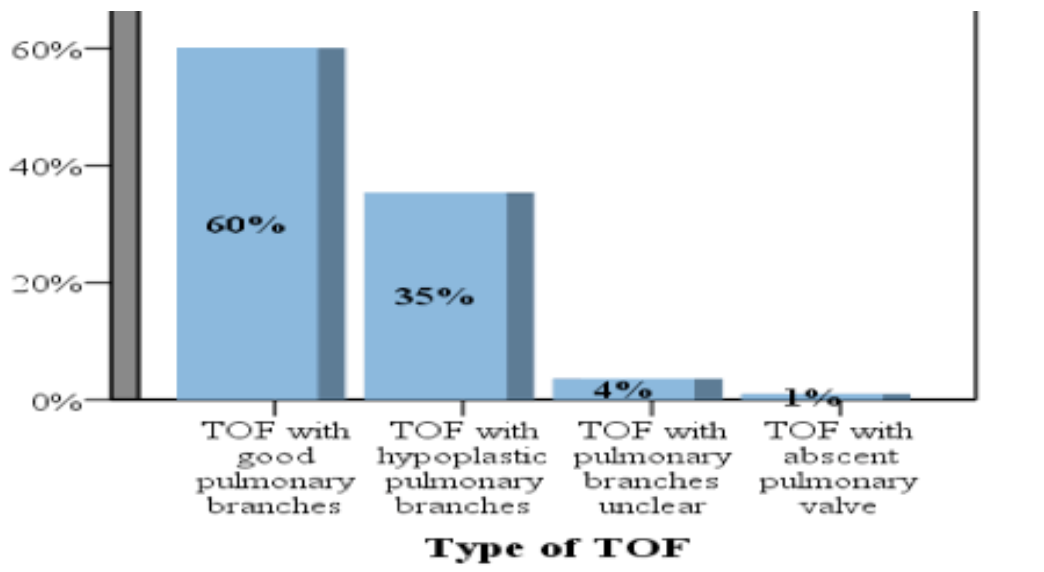


Figure 1. Shows type of TOF distribution according to pulmonary trunk and branches

Table 1. Type of TOF according to age

Variables	Type of TOF			
	TOF with hypoplastic pulmonary branches N (%)	TOF with pulmonary branches unclear N (%)	TOF with absent pulmonary valve N (%)	TOF with good pulmonary branches N (%)
<b>Age of patient</b>	P=0.243	P=0.761	P=0.107	P=0.146
<b>Neonate (1-28)days</b>	2(1.8%)	0(0.0%)	0(0.0%)	1(0.5%)
<b>Infant (1-12)Ms</b>	36(33.0%)	4(36.4%)	1(33.3%)	45(24.3%)
<b>Children (1-18)yrs</b>	66(60.6%)	6(54.5%)	1(33.3%)	132(71.4%)
<b>Adult (&gt;18)yrs</b>	5(4.6%)	1(9.1%)	1(33.3%)	7(3.8%)
<b>Total</b>	109(100%)	11(100%)	3(100%)	185(100%)

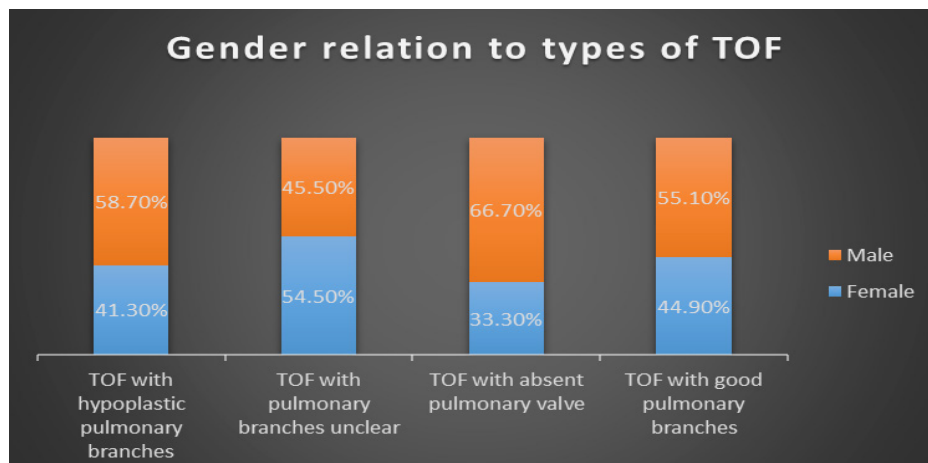


Figure 2. Type of TOF according to gender

Table 2. Show frequencies and percentages of associated lesions

Variables	Frequencies	Percentages
<b>PDA</b>	Present	68 22.1
	Not present	240 77.9
<b>Additional VSD</b>	Present	86 27.9
	Not present	222 72.1
<b>ASD</b>	Present	26 8.4
	Not present	282 91.6
<b>APC</b>	Present	35 11.4
	Not present	273 88.6
<b>AR</b>	Present	31 10.1
	Not present	277 89.9

Table 3. Show correlation of types of TOF with associated lesions

Variables	Type of TOF				P values
	TOF with hypoplastic pulmonary branches N (%)	TOF with pulmonary branches unclear N (%)	TOF with absent pulmonary valve N (%)	TOF with good pulmonary branches N (%)	
<b>PDA</b>					
Present	36(33.0%)	2(18.2%)	0(0.0%)	30(16.2%)	0.001
Not present	73(67.0%)	9(81.8%)	3(100%)	155(83.8%)	
<b>Total</b>	109(100%)	11(100%)	3(100%)	185(100%)	
<b>Additional VSD</b>					
Present	20(18.3%)	0(0.0%)	2(66.7%)	64(34.6%)	0.0001
Not present	89(81.7%)	11(100%)	1(33.3%)	121(65.4%)	
<b>Total</b>	109(100%)	11(100%)	3(100%)	185(100%)	
<b>ASD</b>					
Present	11(10.1%)	0(0.0%)	0(0.0%)	15(8.1%)	0.637
Not present	98(89.9%)	11(100%)	3(100%)	170(91.9%)	
<b>Total</b>	109(100%)	11(100%)	3(100%)	185(100%)	
<b>APC</b>					
Present	21(19.3%)	2(18.2%)	0(0.0%)	12(6.5%)	0.001
Not present	88(80.7%)	9(81.8%)	3(100%)	173(93.5%)	
<b>Total</b>	109(100%)	11(100%)	3(100%)	185(100%)	
<b>AR</b>					
Present	11(10.1%)	2(18.2%)	1(33.3%)	17(9.2%)	0.733
Not present	98(89.9%)	9(81.8%)	2(66.7%)	168(90.8%)	
<b>Total</b>	109(100%)	11(100%)	3(100%)	185(100%)	

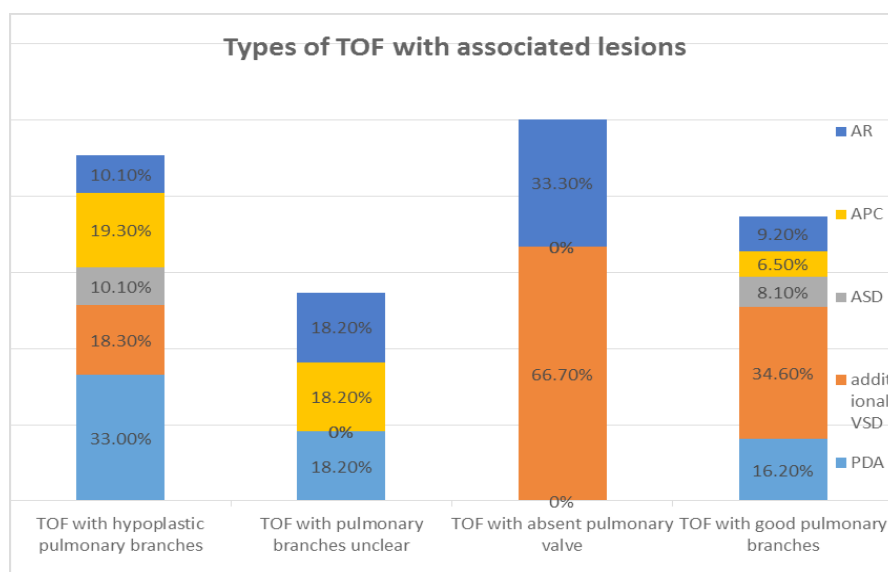


Figure 3. Shows types with associated lesions by percentage

Table 4. Correlation of TOF with type of operation

Variables	Type of TOF			
	TOF with hypoplastic pulmonary branches N (%)	TOF with pulmonary branches unclear N (%)	TOF with absent pulmonary valve N (%)	TOF with good pulmonary branches N (%)
<b>Not operated</b>	76(69.7%)	11(100%)	1(33.3%)	95(51.4%)
<b>Transannular patch</b>	22(20.2%)	0(0.0%)	1(33.3%)	57(30.8%)
<b>Infundibular patch</b>	1(0.9%)	0(0.0%)	0(0.0%)	23(12.4%)
<b>Systemic to pulmonary shunt</b>	9(8.3%)	0(0.0%)	0(0.0%)	4(2.2%)
<b>Valved conduit</b>	0(0.0%)	0(0.0%)	1(33.3%)	4(2.2%)
<b>Rastelli</b>	0(0.0%)	0(0.0%)	0(0.0%)	1(0.5%)
<b>Glenn anastomosis</b>	1(0.9%)	0(0.0%)	0(0.0%)	0(0.0%)
<b>Monocusped valve</b>	0(0.0%)	0(0.0%)	0(0.0%)	1(0.5%)
<b>Total</b>	109	11	3	185

## DISCUSSION

This study is the first study done in Sulaimani and Kurdistan up to our knowledge .

Our finding that pulmonary branches was good in (60%), hypoplastic in (35%), unclear in (4%) and absent pulmonary valve in (1%), is consistent with the study done in London, the United Kingdom which showed 22 (56%) cases had TOF with PS, 17 (44%) TOF with PA and no cases of absent pulmonary valve in a total of 39 cases<sup>(12)</sup>.

Regarding patients age, we have 3 neonates, 86 infants, 205 children and 14 of adults, in comparison to the study done in London, which showed 1 fetus, 11 infants, 14 children, and 13 adults in a total of 39 cases<sup>(12)</sup>. Both studies revealed more cases in children age groups.

Regarding gender of patients, in our research, we have 135(43.8%) female and 173 (56.2%) male. Generally no difference between male and female, were reported by some authors<sup>(13)</sup>. While other authors reported that TOF is slightly more common in males than in females<sup>(4, 10)</sup>.

In this study, additional VSD (27.9%) and PDA (22.1%) were common associations. Associated lesions reported elsewhere, a PDA might be present and common. APC is (11.4%). ASD cases are occasionally seen and other anomalies of the pulmonary arteries and aortic arch may also be seen<sup>(14)</sup>. In comparison to other study done

on 260 cases in which it showed right aortic arch in 34 (15%), additional muscular VSD vary in 13 (5.5%), Patent Ductus Arteriosus (PDA) in 11 (6%) and Major Aortopulmonary Collateral Arteries (MAPCA) in 2 (1.9%) patients<sup>(8)</sup>.

Regarding type of operation, generally transannular patch (total correction) is the most common operation, while the second option (more common in previous years) is a palliative systemic to pulmonary shunt.<sup>(14)</sup> In our research, transannular patch is common about (26%), infundibular patch is (8%) and systemic to pulmonary shunt is (4%). Transannular patching more frequent and its associated with pulmonary regurgitation<sup>(15)</sup>.

In conclusion, this study proved that the presence of good pulmonary branches are common type of TOF and Tetralogy of Fallot is common cyanotic CHD in children age groups.

According to this study, additional VSD and PDA are common associated anomalies of TOF. TOF is slightly more common in males than in female and transannular patch is common type of repair surgeries.

## REFERENCES

- Hoffman JIE, Kaplan S. The incidence of congenital heart disease. J Am CollCardiol. 2002; 39(12):1890-900.
- Apitz C, Webb GD, Redington AN. Tetralogy of fallot. Lancet.2009; 374(9699):1462-71.

3. Neill CA, Clark EB. Tetralogy of Fallot - the 1st 300 years. *Texas Heart Institute Journal*. 1994; 21(4):272-9.
4. Starr JP. Tetralogy of fallot: Yesterday and today. *World J Surg*. 2010; 34(4):658-68.
5. Gatzoulis MA, Webb GD, Daubeney PEF, editors. *Diagnosis and management of adult congenital heart disease*. Second ed. London: Churchill Livingstone; 2011.
6. Wyszynski DF, Correa-Villasenor A, Graham TP, editors. *Congenital heart defects from origin to treatment*. New York, New York 10016: Oxford University Press, Inc.; 2010.
7. Changela V, John C, Maheshwari S. Unusual cardiac associations with tetralogy of fallot-A descriptive study. *Pediatr Cardiol*. 2010; 31(6):785-91.
8. Saeed S, Hyder SN, Sadiq M. Anatomical variations of pulmonary artery and associated cardiac defects in tetralogy of fallot. *J Coll Physicians Surg*. 2009; 19(4):2114.
9. Mcmanus BM, Waller BF, Jones M, Epstein SE, Roberts WC. The case for preoperative coronary angiography in patients with tetralogy of fallot and other complex congenital heart diseases. *Am Heart J*. 1982; 103(3):451-6.
10. Ramaswamy P, Lytrivi ID, Thanjan MT, Nguyen T, Srivastava S, Sharma S, et al. Frequency of aberrant subclavian artery, arch laterality, and associated intracardiac anomalies detected by echocardiography. *Am J Cardiol*. 2008; 101(5):677-82.
11. Cho JM, Puga FJ, Danielson GK, et al. Early and long-term results of the surgical treatment of tetralogy Fallot with pulmonary atresia, with or without major aortopulmonary collateral arteries. *J Thorac Cardiovasc Surg*. 2002; 124(1):70-81.
12. Bedard E, McCarthy KP, Dimopoulos K, Giannakoulas G, Gatzoulis MA, Ho SY. *Jam collcardiol*. Structural abnormalities of the pulmonary trunk in tetralogy of fallot and potential clinical implications: a morphological study. 2009 Nov 10; 54(20):1883-90. Doi: 10.1016/j.jacc.2009.06.040.
13. Christian A, Pitz, Robert H. Anderson, and Andrew N. Redington, tetralogy of fallot with pulmonary stenosis. Robert H Anderson, Edward J Baker, Daniel Penny, Andrew N Redington, Michael L Rigby, Gil Wernovsky. *Pediatric cardiology*. Third edition, 2010 by Churchill Livingstone. Suite 1800, Philadelphia, PA 19103-2899 page (753).
14. Berustein D, tetralogy of fallot. In: Stantonk, St Geme III JW, Kliegman RM, Schor NF, Behrman RE (edc). *Nelson Textbook of pediatrics*, 19th edition. 2011. Saunders, Philadelphia, PP (1576-1577).
15. Salih A. F. et al. EARLY AND LATE OUTCOMES IN REPAIRED TETRALOGY OF FALLOT *JSMC*, 2012 .10024 (Vol 2) No. 1(57-65); DOI Link: <https://doi.org/10.17656/jsmc.10024>