

Macroscopical and Microscopical Changes of Body Organs after *E. coli* O157:H7 Inoculation in Puppies

Mustafa Salah Hasan^{1*}, Afaf Abdulrahman Yousif², Mohammed J. Alwan²

¹ Department of Internal and Preventive Vet. Medicine, College of Vet. Med., University of Fallujah, Iraq

² Department of Internal and Preventive Vet. Medicine, College of Vet. Med., University of Baghdad, Iraq

*Corresponding author: dr.mustafa.salah@uofallujah.edu.iq.

Doi: <https://doi.org/10.37940/AJVS.2020.13.1.5>

This article is licensed under a CC BY (Creative Commons Attribution 4.0)

<http://creativecommons.org/licenses/by/4.0/>.

Abstract

E. coli O157:H7 are an important pathogen of human and animals. The puppies were divided into two groups randomly, infected group: (15 puppies) were drenched once orally with 5 ml bacterial suspension of PBS containing 5×10^7 CFU, and control group: (5 puppies) drenched 5 ml PBS, then specimens from internal organs including: kidney, intestine, liver, spleen, brain and lung after sacrificed puppies at (24hrs, 48hrs, 72hrs, 6 days, 12days, 24days, and 36days) from infected and control groups were used for histopathological examination. After inoculation, all animals were examined for presence or absence of signs. The shedding patterns of *E. coli* O157:H7 in feces were started after 24hrs. after inoculation and ceased at day 14th. The results of gross lesions of internal organs revealed no gross lesions in the intestine, kidney, lung and spleen at 24, 48 and 72 hours. While at days 6, 12, 24, 36 the intestine showed congestion and hemorrhage. Also the kidneys were swollen and showed congestion. The lung showed sever hemorrhages at day 12 post infection, also the spleen showed enlargement at day 24 post infection. The results of histopathological changes showed that *E. coli* O157:H7 infection caused thrombus development, necrosis, vacuolar degeneration of epithelial lining cells and congestion of blood vessels of kidney and intestine with superficial sloughing of epithelial mucosa of intestine at 24hrs and 48hrs. post-infection at 48hrs post-infection. Also the result revealed infiltration of inflammatory cells, vacuolar degeneration appeared in the examined organs at 72hrs. At 6-day post infection the infiltration of inflammatory cells became more prominent with severe congestion of blood vessels in examined organs. At day 12 post infection, there was mucus attachment in the epithelium of intestine, congestion of blood vessels, necrosis, with infiltration of the inflammatory cells in the examined organs. The most important event at day 24 post infection is the presence of regeneration in the intestine which became more prominent at day 36 post infection. This study aimed to highlighting the gross and histopathological effect of *E. coli* O157:H7 in different organs post inoculation in puppies. In conclusion, the shiga toxin can cause damage in many body organs like liver, spleen, kidney, lung, brain and intestine.

Keywords: *E. coli*, Histopathology, Puppies, Inflammatory cells, Organs.

التغيرات العيانية والمجهريّة لأعضاء الجسم بعد الإصابة بالاشيريشيا القولونية O157:H7 في الجراء

الخلاصة

الاشيريشيا القولونية O157:H7 هي احد مسببات المهمة للإنسان والحيوانات. تم تقسيم الجراء عشوائياً الى مجموعتين: مجموعة اصابة (15 جرو) حيث جرعت مرة واحدة عن طريق الفم من معلق محلول الملحي الفسيولوجي 5 مل مع البكتيريا يحتوي على 5×10^7 CFU، ومجموعة سيطرة (5 جراء) : اعطيت محلول الملحي الفسيولوجي 5 مل فقط. ثم لوحظت العلامات السريرية يومياً لمدة 36 أيام، وتم أخذ مسحات البراز مرتين أسبوعياً من مجموعة الإصابة والسيطرة للفحص الجرثومي. واخيراً اخذت عينات من الأعضاء الداخلية بما في ذلك: الكلى والأمعاء والكبد والطحال والمخ والرئة بعد قتل الجراء في الاوقات التالية (24 ساعة، و 48 ساعة، و 72 ساعة، و 6 أيام، 12 يوماً، 24 يوماً، و 36 يوماً) من المجموعات المصابة والسيطرة لفحص التغيرات النسيجية.

بعد التجريب، كل الحيوانات فحصت للتأكد من ظهور او اختفاء العلامات. أظهرت نتائج طرح الاشريشيا القولونية O157: H7 في البراز ان طرح البكتريا قد توقف في غضون أسبوعين (يوم 14) بعد التجريب. وكشفت نتائج الآفات للأعضاء الداخلية في الأمعاء والكلى والرئة والطحال في 24 و 48 و 72 ساعة عدم وجود اي تغيرات، بينما في يوم 6، 12، 24، 36 أظهرت الأمعاء احتقان ونزف. كما كانت الكلى متورمة وأظهرت مستويات متفاوتة من الاحتقان. وأظهرت الرئة نزيف حاد في اليوم 12 بعد الإصابة، كما أظهر الطحال في يوم 24 تضخم بالحجم.

وأظهرت نتائج التغيرات النسيجية المرضية بعد الإصابة بالاشريشيا القولونية O157: H7 تطویر خثرة، تنكس فجوي في خلايا بطانة الظهارية واحتقان الأوعية الدموية في الأعضاء المفحوصة، مع انسلاخ سطحي للغشاء المخاطي الظهاري من الأمعاء في 24 ساعة بعد الإصابة. تنخر شديد، نزيف، وقد لوحظ التهاب مع ظهور المستعمرات الجرثومية في الأمعاء الغليظة في 48 ساعة بعد الإصابة. كما كشفت النتائج ارتشاح خلايا التهابية، وبدا تنكس فجوي في الاجهزة المفحوصة في 72 ساعة. في اليوم 6 بعد الإصابة، لوحظ هناك ارتشاح للخلايا الالتهابية بصورة اوضح مع احتقان شديد في الأوعية الدموية في الاجهزة المفحوصة في اليوم 12 بعد الإصابة، كانت هناك ارتباط وثيق للمخاط في ظهارة الأمعاء، احتقان الأوعية الدموية، تنخر، مع ارتشاح من الخلايا الالتهابية في الاجهزة المفحوصة. أهم حدث في يوم 24 بعد الإصابة هو وجود تجديد في الأمعاء والتي أصبحت أكثر بروزا في يوم 36 بعد الإصابة في الاجهزة المفحوصة.

Introduction

Escherichia coli O157:H7 is a closely an etiology of diarrhea in dogs and puppies (1,2,3). dogs, bats and avian species (4,5,6). Transmission pathways of STEC were the direct contact between humans and pet animals as well as fecal and urine contamination (7,8). Diarrhoeal and nondiarrhoeal dogs of all ages may be a possible human-borne source of the STEC O157:H7 multidrug resistant (9).

E. coli O157: H7 sources was obtained and analyzed in feedlots and farms in the northwest of the United States, 65 dog samples and 33 cat samples for the presence of *E. Coli*O157: H7, Results were negative and 3,1% tested positive for all cat samples. The possible source of the bacterium for the dogs on these farms may be the cattle via the rivers (10). *E. coli* has been isolated from environment (11), While (12) diagnosed the hemolytic uremic syndrome in a dog with signs of acute onset of anorexia, vomiting and hemorrhagic diarrhea, the results show that these signs were typical to the signs caused by shiga toxin producing *E. coli* (STEC).

Shiga toxin (*Stx*) producing *E. coli* (STEC) is responsible for bloody diarrhea (hemorrhagic colitis) and the hemolytic uremic syndrome (HUS)

(13). Hemolytic uremic syndrome caused by STEC is characterized by low platelet count, hemolytic anemia, and kidney failure (14,15). *Escherichia coli* O157:H7 were isolated from dogs fecal sample which has class 1 integrons and they conclude that the presence of class 1 integrons serving as reservoirs of antibiotic resistance genes (16). (17) isolated *E. coli* O157 with different H types from dogs, and their results showed That dogs can harbor pathogenic *E. Coli* O157 that do not correspond to Shiga toxin-producing strains and should not be underestimated. Pets can act as a reservoirs of STEC strains, a study of (18) was conducted to examine nine strains belonging to several serotypes which previously recovered from cats or dogs. The findings showed that animals could play a major role in human infection by STEC, which is likely to act as a vector for bovine strains in the human disease cycle and thus is essential to the health risk of owners and their families.

Shiga toxin C. *E. Coli* (STEC) O157: H7 was found in diarrhoeal and non-diarrhoeal faeces. *E. Coli* O157: H7 was found in 5 (16.1%) of 31, 17 (26.9%) of 63 non-diarrhoeal dogs, and the researcher concluded that most isolates were multi-drug resistant, also concluded that diarrhoeic and non-diarrhoeic dogs may serve as

potential sources of STEC O157:H7 transmissible to humans (9). It can also reported to cause diarrhea in dogs (19), Calves (20,21), sheep (22) and Buffalo (23).

The aim of this study was to explore the gross and pathological lesions in puppies at a different time post *E. coli* O157:H7 inoculation.

Materials and methods

1. **Bacterial isolates:** virulent *E. coli* O157:H7 isolates were obtained from University of Baghdad/ College of Veterinary Medicine /Department of internal and preventive medicine, these were isolated from diarrheic and non-diarrheic dogs found in Baghdad Province. These isolates confirmed in a previous study by (2) , which possess five virulence gene (*rfb*O157, *fliC*H7, *Stx*1, *Stx*2 and *eaeA*), these genes confirmed by conventional and real time PCR by (1).

2. **Preparation of *E. coli* O157:H7 infective dose:** To prepare the bacterial suspension of *E. coli* O157:H7 , the bacteria inoculated in 10 ml of brain heart infusion broth at 37 °C for 18 hours, then centrifuged in cold centrifuge at 8000 rpm (round per minute) for 15 minutes, the sediment washed three times with phosphate buffer saline (PBS) (pH=7.2) and re-suspended with 5 ml of PBS, then this suspension drenched once orally, which containing 5×10^7 CFU according to (24). The infective dose of bacteria was made according to (25). The infective dose was experimented on 3 puppies for insurance of the dose before using in experimental puppies.

3. **Experimental animals:** Total number of (20) puppies, aged between (35-45) days, were adjusted two weeks before starting the pumping experiment in clean and disinfected cages, fecal crops for *E. Coli* O157: H7 was made to remove natural pathogens and carriers from inoculation. Ad libitum milk was fed, then gradually adapted to chicken meat, rice and clean water.. These dogs were divided randomly into two groups as follows:

a. **Infected group:** Fifteen puppies were used as infected group and drenched 5 ml suspension containing (5×10^7) CFU of *E. coli* O157:H7 according to (24).

b. **Control group:** Five puppies were drenched orally by plastic syringe with PBS dose 5 ml.

4. **Examination of the puppies:-** All puppies were examined for the following:-

a. **Daily observation of clinical signs:** The puppies were daily monitored for presence or absence of abnormal clinical signs.

b. **Fecal examination:** Fecal swabs were taken twice weekly from all animals for confirming the presence or absence of *E. coli* O157:H7 .

c. **Post mortem examination:**

Two puppies were killed after 24hrs, 48hrs, 72hrs, 6 days, 12days, 24days, and 36 days . the post mortem includes:

1. **Macroscopic examination were done for all animals.**

2. **Microscopical Examination:** Specimens taken from intestine, both kidneys, spleen, liver, lungs as well as brain at 24hrs, 48hrs, 72hrs, 6 days, 12days, 24days and 36days from all animals for histopathology which was done according to (26).

Results and discussion

Before inoculation, all puppies showed a normal body temperature, heart rates and respiration rates. Post inoculation, the peak of infected group increased after 24, 48 and 72 hours and returned to normal at 4th and 5th days as compared with control group (Table 1) (Figure 1).

Post inoculation, the infected group showed an increase in heart rate after 24 , 48 , 72 hours in contrast to the control group which showed normal ranges within the five days Table(1) (Fig. 2). Also, Post inoculation the puppies showed an increase in the respiration rates, the infected group gave higher means of respiration rates during 24, 48 and 72 hours, while the

control group didn't show any change in respiration rates (Table 1; Figure 3). The puppies were monitored daily for development of other clinical signs such as diarrhea, dehydration and other signs. Before inoculation, all twenty puppies showed normal clinical signs, while post inoculation, after 24hrs all 15 puppies of infected group showed diarrhea (Figure 4) which persisted for 4 days post inoculation. Also puppies appeared dehydrated with varying degree (Figure 5), 6 puppies showed congested mucous membrane, also, 4 puppies showed bloody urine after 3 days post infection.

The presented study showed that infected animals exhibit different signs after 24hrs of *E. coli* O157:H7 inoculation. These results are in agreement with those recorded by (24) who showed that on the second day after E inoculation, both dogs experienced acute watery or mucoid diarrhoea. Coli O157:H7 with slightly bloody stool have also been observed reducing appetite, nausea and vomiting. Dogs also exhibit drastic loss of weight and mild to extreme exhaustion, fatigue and lethargy. In addition, 14 inoculated EPEC pups have been confirmed to have pasty-to-liquid diarrhea, without vomiting 72 hours after infecting (27). Also, (28) showed that beagle dogs had slight to severe diarrhea after inoculation with *E. coli* O157:H7. (29) concluded that both types of *E. coli* AEEC or ETEC could be considered a relevant cause of diarrhea in dogs and pups.

Shedding of *E. coli* O157:H7:

The fecal swabs were taken twice weekly from all animals. These swabs were cultured on EMB, MacConkey, Chrom and CT-SMAC agars, then the isolates were serotyped by latex agglutination test. The shedding patterns of *E. coli* O157:H7 in feces were started after 24hrs. From inoculation and ceased within two weeks (day 14th) (Table 3). The internal organs of puppies infected orally with *E. coli* O157:H7 which examined at these times (24hrs, 48hrs, 72hrs, 6, 12, 24 and 36 days

post infection), the 2 puppies were killed in each time showed the following:- No gross lesions in the intestine, kidney, lung and spleen of the puppies at 24, 48 and 72 hours after inoculation.

While at days 6, 12, 24, 36, the intestine showed congestion and hemorrhage. Also the kidneys were swollen and showed varying levels of congestion. The lung showed severe hemorrhages at day 12 post infection, also the spleen showed enlargement at day 24 post infection (Figures 6, 7, 8, 9). **B. Histopathological lesions:**

The results of histopathological changes showed that *E. coli* O157:H7 infection caused thrombus development, vacuolar degeneration of epithelial lining cells and congestion of blood vessels of kidney (Figure:10) and intestine with superficial sloughing of epithelial mucosa of intestine (Figure:11) at 24hrs post-infection. Severe necrosis, hemorrhage, inflammation were noticed with bacterial colonization in large intestine at 48hrs post-infection (Figure:12), while the kidney revealed large necrotic area with acute cellular degeneration (Figure:13). Also the result revealed infiltration of inflammatory cells, vacuolar degeneration appeared in the intestine and kidney at 72hrs (Figures:14, 15). At 6 day post infection the infiltration of inflammatory cells became more prominent with severe congestion of blood vessels in kidney, intestine, liver, brain, spleen (Figures:16, 17, 18, 19, 20, 21, 22). At day 12 post infection, there was mucus attachment in the epithelium of intestine, congestion of blood vessels, necrosis, with infiltration of the inflammatory cells in the examined organs (Figures:23, 24). The most important event at day 24 post infection is the presence of regeneration in the intestine which became more prominent at day 36 post infection in examined organs, while the other organs showed a mild regeneration especially at day 36 (figures: 25, 26, 27). This study showed different histopathological changes in different organs at different times 24hrs, 48hrs, 72hrs, 6days, 12days, 24days and 36days.

The inflammatory reaction in the intestine in the current study may indicate that this strain can survive in gastrointestinal environment, attachment, colonization of intestinal epithelial cells and stimulate the phagocytic cells to produce pro inflammatory cytokines that were responsible for inflammatory reaction, this investigation is agreed with (32) who explained that STEC can survive in GIT environment and they colonized in the intestinal tissues .

The current study showed moderate pathological changes in the kidney during 24hrs post infection, this result may indicate that the local isolated strain of *E. coli* O157:H7 can survive and colonize the intestine and disseminate to main target organs especially the kidney post secret the toxins during these period through overcome the cellular and humoral innate immune system. This observation is in agreement with (33) who found that *E. coli* produced StcE that play an important role in regulating classical complement pathway via destroying serpinC1 esterase which are encoded on PO17 plasmid.

The result of this study revealed neutrophils infiltration in the kidney, this result may indicate that Stxs may reach the kidney from the intestine and stimulate production of IL 8 that attracted the neutrophils to injury site, this evidence is agreed with (34) who found that the inflammatory reaction induced impair function of intestinal barrier that facilitated the cross of Stxs from intestinal lumen to sub mucosa and systemically disseminated.

The pathological changes increased in the intensity with progressive time, at 48hr post infection, it was reported severe lesions in the intestine characterized by the presence of bacterial colonies in clear round spaces in the epithelial layer of the large intestine with focal erosion of epithelial cells and inflammatory cells infiltration in the lamina propria, this result may indicate development of attaching and effacing

lesions which are the main intestinal lesions inducing by *E. coli* O157:H7 particularly intimin eaeA positive strain, this observation is in consistency with result of PCR assay in the current study, also the above idea agrees with (35) who demonstrated that eae positive *E. coli* strain can form AE lesions on epithelial cells of the intestine. The eae positive STEC O157:H7 induced AE lesion may be due to their possessing locus of enterocyte effacement (LEE) which encodes a type III secretion apparatus, outer membrane protein called intimin (eae) (*E. coli* attaching and effacing protein) and translocated intimin receptor (TIR) (36), in addition to effector protein, this protein transported by secretion apparatus, a syringe molecule extended from inside the bacterial cells through inner and outer membrane to the cytoplasm of the host cells (37). this protein (TIR) acts as a receptor for intimin. TIR and other protein can cause reorganization of cytoskeletal of intestinal epithelial cells lead to accumulated these cytoskeletal protein under the bacteria which were intracellular proliferation and produced Stxs in the AE lesion (38 ; 39). This lesion can protect the bacteria from phagocytic cells and remove the bacteria by diarrhea (40).

The present finding demonstrated that the severe lesions in examined organs were recorded during six to 12 days post infection, the severity of the lesions induced by *E. coli* O157:H7 was dependent on virulence factors of these pathogens particularly Stxs, however, the severity of the lesions in intestine coincides with marked inflammatory reaction in the intestine, this result may support an idea said that, the inflammatory reaction play roles in exaggerated cytotoxic effects of shiga toxin produced by these bacteria, this idea agrees with (41) reported that Stxs can promote production of IL8 that facilitated paving neutrophils to endothelial cells.

At this time, the severe lesions in the intestine are coincident with severe diarrhea expressed by infected animals in the present study, this result is

in agreement with that of (42) who revealed that *E. coli* O157:H7 can induced severe diarrhea and renal failure in infected host (human and animals).

Overproduction of mucin in the intestine at 12 days post infection, may be indicate a defense mechanism against bacterial infection. This result is compatible with (43;44) who showed that mucus secretion is considered one of intestinal barrier against pathogen infection, in addition to acetate in which inhibited transmission of shiga toxin to the tissue from the lumen of infected intestine. Normally mucin can prevent imbalance between intestinal epithelial cells and *E. coli* and other commensal bacteria (45;46).

This results showed a severe hemorrhagic inflammation in the lung. These result may indicate that in the dogs the pulmonary vascular endothelial cells are rich with Stxs receptors (47). (48) mentioned that there are two receptors for shiga toxin include neutral glycolipid globotriosylceramide GB3 and globotetraosylceramide Gb4. (49) demonstrated Stxs receptors in the certain cells including enterocytes, renal, brain and lung endothelial cells as well as platelets and RBCs. However, hemorrhagic pneumonia in the dog experimentally infected with *E. coli* O157:H7 was considered the first observation in this study.

The intestinal lesions in the current study are in agreement with clinical signs that revealed certain infected experimental dogs, showed bloody or no bloody diarrhea, this observation is in consistency with (50) who recorded that the lesion of AE was not frequently associated with bloody diarrhea and HUS in humans and they considered EHEC eae positive strain are a risk for HUS, also these results are in agreement with observation of (51) who demonstrated that, *E. coli* serotype, O157:H7, a non invasive pathogen, can either induce sporadic or outbreaks of diarrhea associated with hemorrhagic colitis and HUS in human. Stxs can bind to vascular endothelial cells

of GIT causing destroying these cells (52).

Thrombus formation in the blood vessels of kidney may be due to bacterial LPS and Stxs that may activate platelets and cause damage endothelial cells with inducing deposition of fibrin networks as discussed by (49).

At 24 days post infection, the result investigated that the body immune system started to eradicate the bacterial infection, in this period, low intensity of pathological lesions were recorded, and regeneration processes were initiated in the intestine, this may be due to activate innate immune cells, this idea is in consistency with (53) who recorded that activated innate immunity was considered one important defense mechanism against bacterial infection.

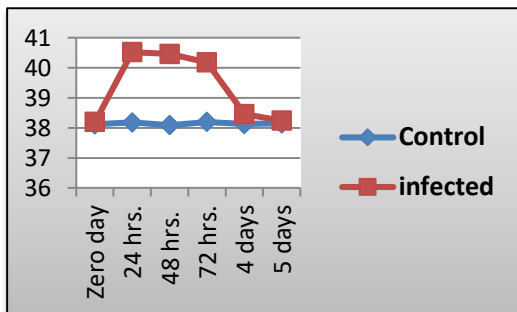
This eradication mechanism was discussed by many researchers like (54) who found that immune responses against bacterial colonization such as *E. coli* started through interaction between bacterial antigen with immune receptors which expressed by intestinal epithelium such as TLRs and activating these receptors leads to recruitment of neutrophils and other phagocytic cells to site of infection and eliminate the bacterial infection, in addition to adapt immune reaction that provided other protective mechanism against invading pathogens.

Conclusion

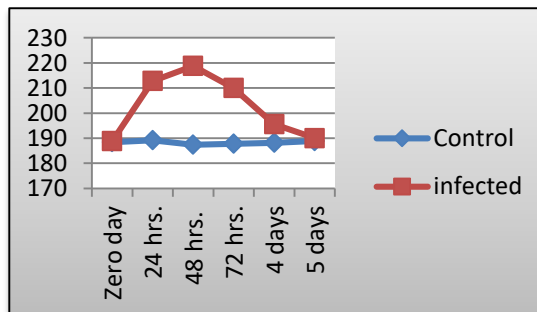
E. coli O157:H7 can causing different signs such as diarrhea, dehydration and other related signs. The shiga toxin can cause damage in many body organs like liver, spleen, kidney, lung, brain and intestine, also, the histopathological examination showed that the regeneration of tissue especially intestine started after 24days post infection, while the other organs showed regeneration at 36days post infection.

Table (1). Body temperature, heart rates and respiration rates in the control and infected groups at different periods

Time		Temperature(°C)		Heart rate/M		Respiration/M	
		Control group	Infected group	Control group	Infected group	Control group	Infected group
Zero day	Range	37.6-38.7	37.8-38.6	182-196	180-198	18-26	19-24
	(Mean)	(38.12)	(38.24)	(188.4)	(188.8)	(22)	(21.6)
24 hrs.	Range	37.8-38.5	40 -40.9	186-194	206-220	20-23	34-39
	(Mean)	(38.18)	(40.52)	(189.2)	(212.8)	(21.5)	(36.4)
48 hrs.	Range	37.8-38.4	40.3-40.6	178-198	214-224	19-23	36-41
	(Mean)	(38.09)	(40.46)	(187.4)	(218.8)	(21.8)	(38.8)
72 hrs.	Range	37.9-38.5	40-40.4	184-192	208-212	20-24	34-38
	(Mean)	(38.2)	(40.18)	(187.8)	(210)	(22)	(36)
4 days	Range	37.7-38.6	38.3-38.6	186-192	192-200	21-24	22-26
	(Mean)	(38.13)	(38.46)	(188.2)	(195.6)	(22.4)	(24)
5 days	Range	37.9-38.3	37.9-38.5	184-196	186-194	21-22	19-26
	(Mean)	(38.15)	(38.24)	(188.9)	(190)	(21.4)	(22.2)



Figure(1): Body temperature in the control and infected groups.



Figure(2): Heart rates in the control and infected groups.

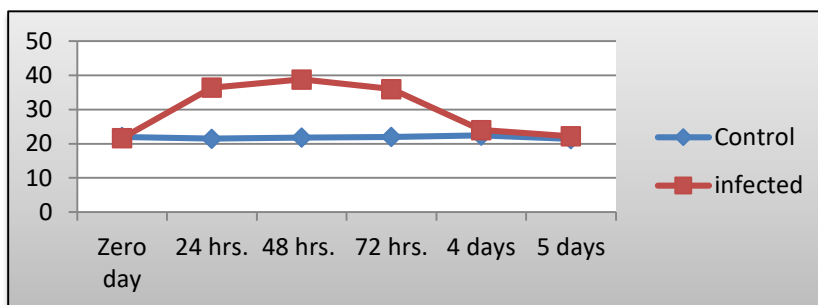


Figure (3): Respiration rates in the control and infected groups

Table 2. Other clinical signs of infected group after inoculation

No. of puppies	Diarrhea		Dehydration				Congested mucous membrane	Bloody urine
	With blood	Without blood	Less than 7%	7%	10%	More than 10%		
1		<input checked="" type="checkbox"/>				<input checked="" type="checkbox"/>	<input checked="" type="checkbox"/>	<input checked="" type="checkbox"/>
2		<input checked="" type="checkbox"/>				<input checked="" type="checkbox"/>	<input checked="" type="checkbox"/>	
3	<input checked="" type="checkbox"/>				<input checked="" type="checkbox"/>		<input checked="" type="checkbox"/>	<input checked="" type="checkbox"/>
4		<input checked="" type="checkbox"/>			<input checked="" type="checkbox"/>		<input checked="" type="checkbox"/>	
5		<input checked="" type="checkbox"/>			<input checked="" type="checkbox"/>		<input checked="" type="checkbox"/>	
6		<input checked="" type="checkbox"/>			<input checked="" type="checkbox"/>		<input checked="" type="checkbox"/>	<input checked="" type="checkbox"/>
7		<input checked="" type="checkbox"/>			<input checked="" type="checkbox"/>			
8		<input checked="" type="checkbox"/>			<input checked="" type="checkbox"/>			
9	<input checked="" type="checkbox"/>			<input checked="" type="checkbox"/>				<input checked="" type="checkbox"/>
10		<input checked="" type="checkbox"/>		<input checked="" type="checkbox"/>				
11		<input checked="" type="checkbox"/>		<input checked="" type="checkbox"/>				
12		<input checked="" type="checkbox"/>		<input checked="" type="checkbox"/>				
13		<input checked="" type="checkbox"/>		<input checked="" type="checkbox"/>				
14	<input checked="" type="checkbox"/>		<input checked="" type="checkbox"/>					
15		<input checked="" type="checkbox"/>	<input checked="" type="checkbox"/>					



Fig. 4 puppy with diarrhea (2 days after inoculation)

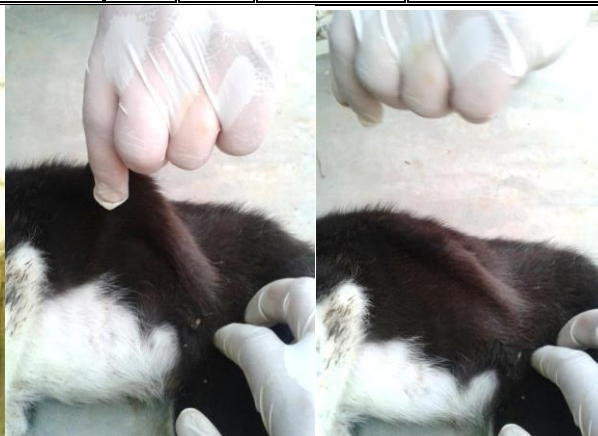


Fig. 5 puppy with 10% degree of dehydration (Fourteen days after inoculation)

Table (3) Shedding of *E. coli* O157:H7 at different days of experiment

Times of fecal swab	Positive result	Negative result
Zero day		<input checked="" type="checkbox"/>
24 hrs.	<input checked="" type="checkbox"/>	
day 7th	<input checked="" type="checkbox"/>	
day 10th	<input checked="" type="checkbox"/>	
day 14th		<input checked="" type="checkbox"/>
day 17th		<input checked="" type="checkbox"/>
day 21st		<input checked="" type="checkbox"/>
day 24th		<input checked="" type="checkbox"/>
day 28th		<input checked="" type="checkbox"/>
day 31st		<input checked="" type="checkbox"/>
day 35 th		<input checked="" type="checkbox"/>

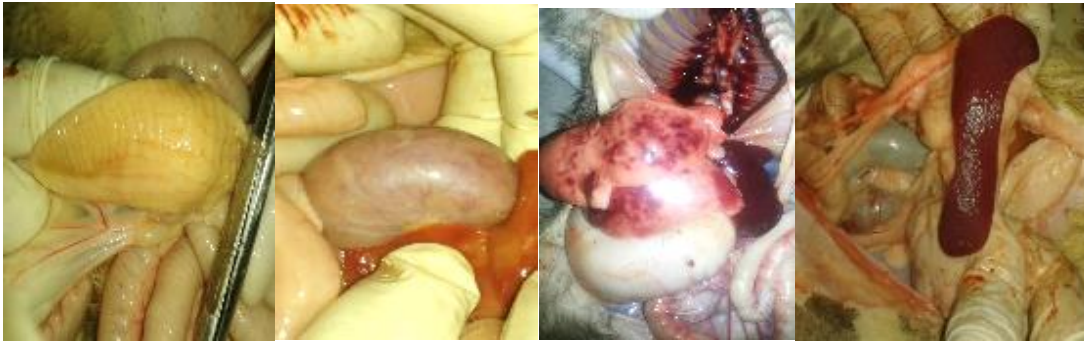

Figure (6) intestine with streaks of hemorrhage after 6 days post infection

Figure (7) kidney with capillary congestion after 6 post infection

Figure (8) lungs with sever hemorrhages after 12 days post infection

Figure (9) spleen showed enlargement after 24 days post infection

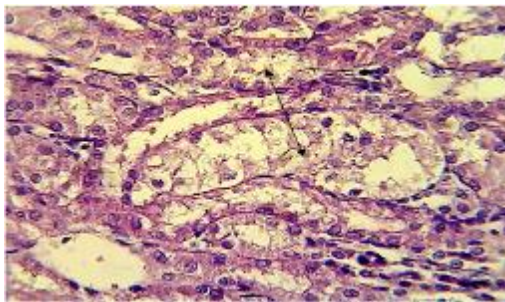


Figure:10. Histological section in the kidney of animal at 24hr post infection shows focal necrosis and vacuolar degeneration of epithelial cells of renal tubules with neutrophils in the blood vessels (H&E stain 400X)

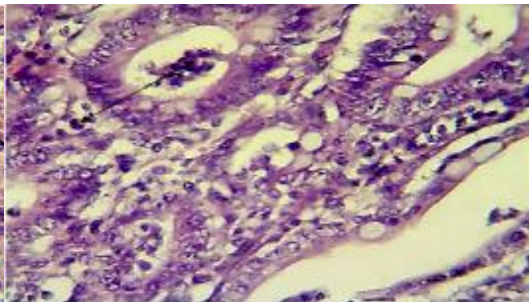


Figure:11.Histological section in the large intestine of animal at 24hrs post infection showed inflammatory cells particularly neutrophils in lumen and around of mucosal glands (H&E stain 400X)

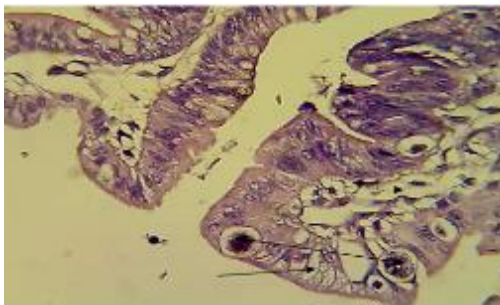


Figure:12. histopathological ological section in the large intestine of animal at 48hrs post infection shows bacterial colonies in clear round spaces in the epithelial layer with vacuolation of epithelial cells and the edema in LP (H&E stain 400X)

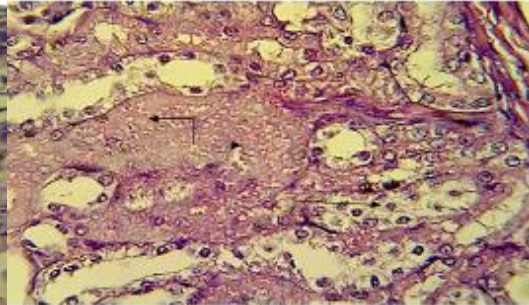


Figure:13. Histological section in the kidney of animal at 48hrs post infection shows large necrotic area with acute cellular degeneration in epithelial cells of renal tubules (H&Estain 400X)

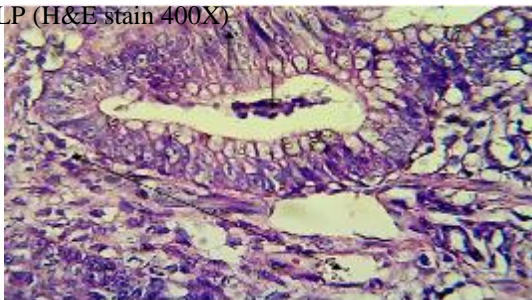


Figure:14. Histological section in the large intestine of animal at 72hrs post infection shows neutrophils in the lumen of hyperplastic epithelial cells (H&E stain 400X)

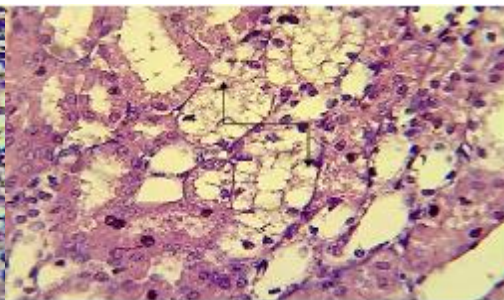


Figure:15.Histopathological section in the kidney of animal at 72hrs post infection shows marked vacuolation, desquamation epithelial lining cells of renal tubules (H&Estain 400X)

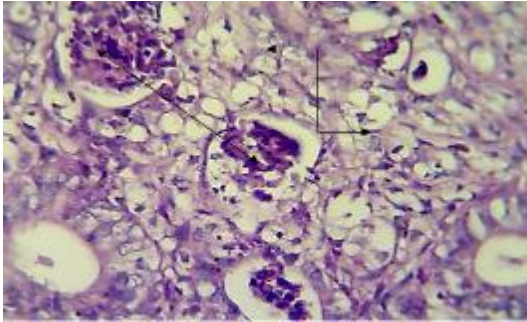


Figure:16. Histopathological section in large intestine of animal at day six post infection shows the lumen of dilated mucosal gland filled with neutrophils and cellular debris with edema (H&E stain 400X)

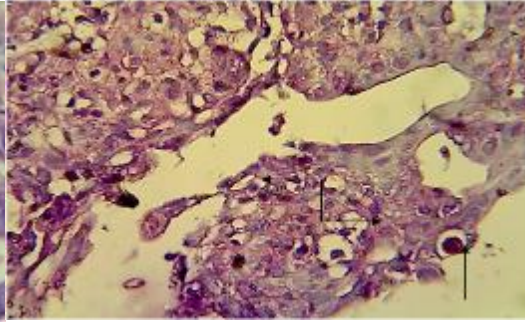


Figure:17. Histological section in the large intestine of animal at six days post infection shows atrophy of villi characterized by rounded, fused together with high cellular of wide LP, in addition to bacterial colonies in clear round space in epithelial cells (H&E stain 400X)

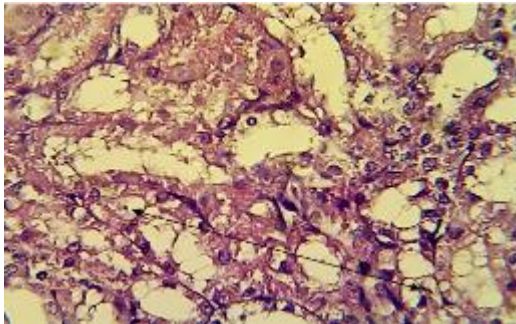


Figure:18. Histological section in these kidney of animal at six days post infection shows vacuolar degeneration and sloughing of epithelial cells of renal tubules (H&E stain 400X)

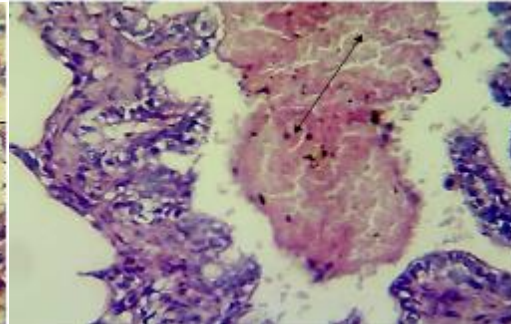


Figure:19. Histological section in the lung of animal at six days post infection shows accumulation of RBCs with neutrophils in the lumen of the bronchiole (H&E stain 400X)

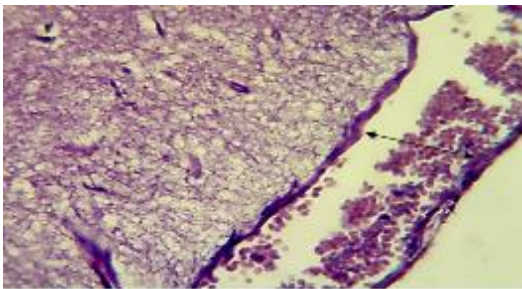


Figure:20. Section in the brain of infected animal at six days post infection shows congested blood vessels in pia mater (H&E stain 400X)

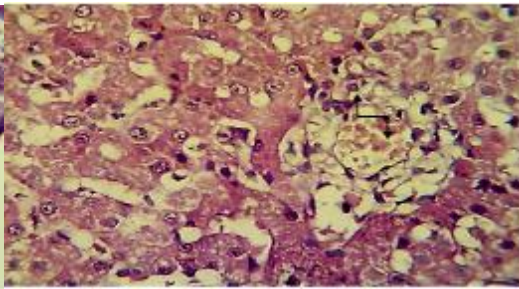


Figure:21. Section in the liver of infected animal at six days post infection shows pericentral necrosis of hepatocytes and congested central vein (H&E stain 400X)

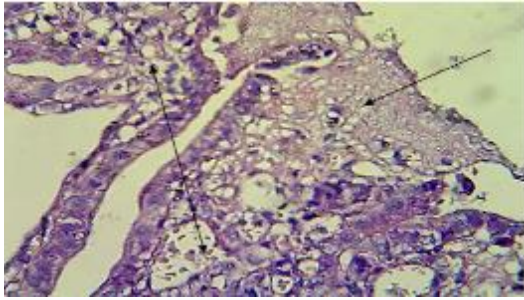


Figure:22. Histological section in the large intestine of animal at 12 days post infection shows mucin attachment to epithelial cells with PMN cells in congested blood vessels (H&Estain400X)

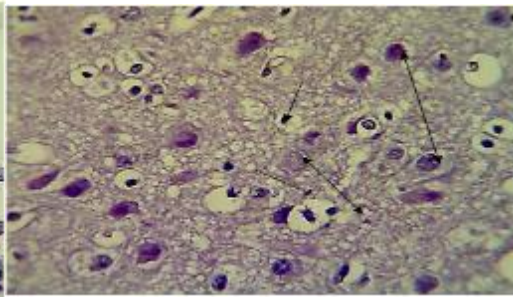


Figure:23. Section in the brain of infected animal at 12 days post infection shows proliferation and enlargement of astrocytes, proliferation of oligodendrocytes and microglial cells (H&E stain 400X)

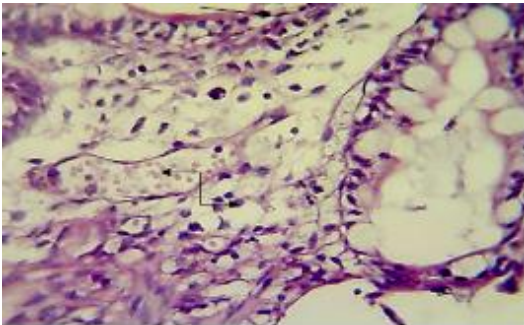


Figure:24. Histological section in the large intestine of animal at 24 days post infection shows inflammatory cells particularly neutrophils and mononuclear cells and congested blood vessels and in LP with start regeneration of epithelial cells (H&Estain400X)

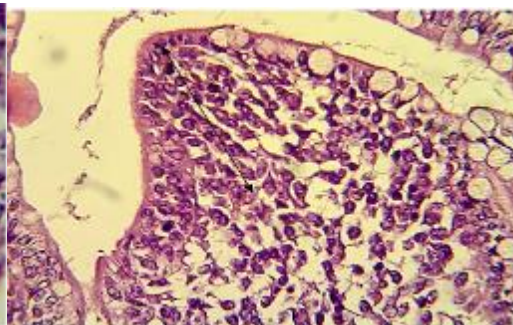


Figure:25. Histological section in the large intestine of animal at thirty six days post infection shows regeneration of epithelial cells with moderate hypercellularity of LP (H&Estain400X)

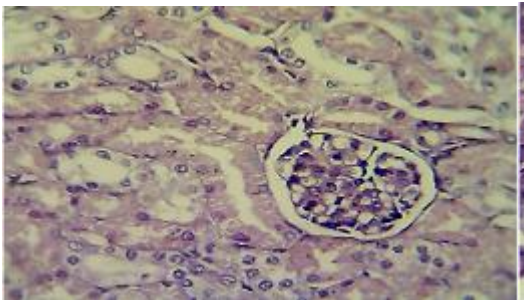


Figure:26. Histological section in the kidney of animal at thirty six days post infection shows no clear lesions (H&E stain 400X)

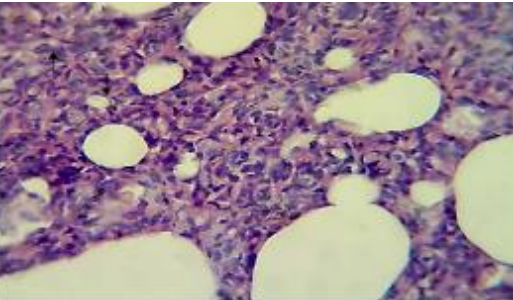


Figure:27. Section in the lung of infected animal at thirty six days post infection shows marked mononuclear cells infiltration in the interstitial tissue leading to narrow of alveolar space (H&E stain 400X)

References

1. Yousif AA, Hasan MS, Alwan MJ. Clinical and molecular study of *E. coli* O157: H7 isolated from Diarrheic and non-diarrheic dogs. *Mirror of Research in Veterinary Sciences and Animals*. 2016;5(2):1-0.
2. Hasan MS, Yousif AA, Alwan MJ. Detection of virulent genes in *E. coli* O157: H7 isolated from puppies and adult dogs by polymerase chain reaction. *Res. J. Vet. Pract*. 2016;4(1):1-6.
3. Yousif A, Hasan M, Najim T, Hussein M. Detection of virulence and antimicrobial susceptibility testing of *Escherichia coli* O157:H7 isolated from pets and stray dogs. *Journal of Entomology and Zoology Studies*. 2017; 5(4):573-578.
4. Ojo OE, Ajuwape AT, Otesile EB, Owoade AA. Detection of shiga toxin-producing *Escherichia coli* in poultry birds in Abeokuta, Nigeria. *Tropical Veterinarian*. 2010a;28(4):1-0.
5. Ojo OE, Ajuwape AT, Otesile EB, Owoade AA, Oyekunle MA, Adetosoye AI. Potentially zoonotic shiga toxin-producing *Escherichia coli* serogroups in the faeces and meat of food-producing animals in Ibadan, Nigeria. *International journal of food microbiology*. 2010b 15;142(1-2):214-21.
6. Italia JT, Rovira HG, Masangkay JS, Yoshikawa Y, Perez MT, Reyes AW, Baticados WN. Conventional isolation and polymerase chain reaction assay for detection of *Escherichia coli* O157: H7 from intestines of philippine bats. *Veterinarski arhiv*. 2012 Apr 27;82(3):283-94.
7. Johnson JR, Stell AL, Delavari P. Canine feces as a reservoir of extraintestinal pathogenic *Escherichia coli*. *Infection and immunity*. 2001 Mar 1;69(3):1306-14.
8. Bentancor A, Rumi MV, Gentilini MV, Sardoy C, Irino K, Agostini A, Cataldi A. Shiga toxin-producing and attaching and effacing *Escherichia coli* in cats and dogs in a high hemolytic uremic syndrome incidence region in Argentina. *FEMS microbiology letters*. 2007 Feb 1;267(2):251-6.
9. Ojo O, Bello A, Amosun E, Ajadi R. Multidrug resistant verocytotoxin-producing *Escherichia coli* O157: H7 in the faeces of diarrhoeic and non-diarrhoeic dogs in Abeokuta, Nigeria. *Veterinarski arhiv*. 2014 Feb 13;84(1):63-73.
10. Hancock DD, Besser TE, Rice DH, Ebel ED, Herriott DE, Carpenter LV. Multiple sources of *Escherichia coli* O157 in feedlots and dairy farms in the northwestern USA. *Preventive veterinary medicine*. 1998 Apr 16;35(1):11-9.
11. AlMahdawy MMA, Al-Karboly MYA. A Study of sensitive *S. aureus*, *E.coli* and *Ps. aeruginosa* for chlorhexidin and sodium hypochlorite in Ramadi Teaching Hospital. *Al-Anbar Journal of Veterinary Sciences*, 2015; 8(2):1-19.
12. Dell'Orco M, Bertazzolo W, Pagliaro L, Roccabianca P, Comazzi S. Hemolytic-uremic syndrome in a dog. *Veterinary clinical pathology*. 2005 Sep;34(3):264-9.
13. Ibarra C, Amaral MM, Palermo MS. Advances in pathogenesis and therapy of hemolytic uremic syndrome caused by shiga toxin-2. *IUBMB life*. 2013 Oct 1;65(10):827-35.
14. Koochakzadeh A, Badouei MA, Mazandarani E, Madadgar O. Survey on O157: H7 enterohemorrhagic *Escherichia coli* (EHEC) in cattle in Golestan province, Iran. *Iranian journal of microbiology*. 2014 Aug;6(4):276.
15. Mahon CR, Lehman DC, Manuselis Jr G. *Textbook of diagnostic microbiology-E-Book*. Elsevier Health Sciences; 2015: 445.
16. Yang H, Byelashov OA, Geornaras I, Goodridge LD, Nightingale KK, Belk

- KE, Smith GC, Sofos JN. Characterization and transferability of class 1 integrons in commensal bacteria isolated from farm and nonfarm environments. *Foodborne pathogens and disease*. 2010 Dec 1;7(12):1441-51.
17. Bentancor A, Vilte DA, Rumi MV, Carbonari CC, Chinen I, Larzabal M, Cataldi A, Mercado EC. Characterization of non-Shiga toxin-producing *Escherichia coli* O157 strains isolated from dogs. *Revista Argentina de microbiologia*. 2010;42(1):46-8.
18. Bentancor A, Rumi MV, Carbonari C, Gerhardt E, Larzábal M, Vilte DA, Pistone-Creydt V, Chinen I, Ibarra C, Cataldi A, Mercado EC. Profile of Shiga toxin-producing *Escherichia coli* strains isolated from dogs and cats and genetic relationships with isolates from cattle, meat and humans. *Veterinary microbiology*. 2012 May 4;156(3-4):336-42.
19. AL-Kubaisi SM, Saed OA, Suleiman JM, Hasan MS, Owain MS, Jarad AS. Isolation and Identification of Facultative Anaerobic Bacteria from Feces of Pet Dogs. *Medico Legal Update*. 2020 Apr 9;20(1):783-7.
20. Suleiman JM, Saed OA, AL-Kubaisi SM, Hasan MS, Owain MS, Hussein MA, Jarad AS. Molecular characterization of Eae and Stxs genes for *E. coli* O157: H7 isolates from Calves. *Medico Legal Update*. 2020 Apr 9;20(1):788-91.
21. Hasan MS, Hussein MA, Yousif AA. Confirmatory Detection of *Escherichia coli* O157: H7 in Diarrhoeic and Non-Diarrhoeic Calves by using real time PCR with Studying the Antimicrobial Susceptibility of these bacteria. *Research Journal of Pharmacy and Technology*. 2019;12(1):245-50.
22. Jarad AS, AL-Kubaisi SM, Abdulkhalik RJ, Hasan MS. Bacteriological and Pathological Study on Kidneys of Slaughtered Sheep in Fallujah City. *Indian Journal of Forensic Medicine & Toxicology*. 2020 Jan;14(1):665.
23. Al-Mafraji AM. Detection of *E. coli* K99 and Rota virus antigens in diarrheic and healthy buffalo of Babil Province, Iraq. *Al-Anbar Journal of Veterinary Sciences*. 2014;7(1):17-21.
24. Wang JY, Wang SS, Yin PZ. Haemolytic-uraemic syndrome caused by a non-O157: H7 *Escherichia coli* strain in experimentally inoculated dogs. *Journal of medical microbiology*. 2006 Jan 1;55(1):23-9.
25. Miles AA, Misra SS, Irwin JO. The estimation of the bactericidal power of the blood. *Epidemiology & Infection*. 1938 Nov;38(6):732-49.
26. Luna LG. *Manual of histologic staining methods of the Armed Forces Institute of Pathology*, Blakiston Division, 3rd ed. McGraw-Hill Book Co, New York, NY. 1968: p 38–39.
27. Gouveia EM, Silva IS, Nakazato G, Araujo FR, Chang MR. Experimental infection with enteropathogenic *Escherichia coli* identified by PCR using enteric-coated capsules in boxer pups. *Acta cirurgica brasileira*. 2011 Apr;26(2):144-8.
28. Kuribayashi T, Seita T, Matsumoto M, Furuhashi K, Tagata K, Yamamoto S. Bovine colostral antibody against verotoxin 2 derived from *Escherichia coli* O157: H7: resistance to proteases and effects in beagle dogs. *Comparative medicine*. 2009 Apr 15;59(2):163-7.
29. Drolet R, Fairbrother JM, Harel J, Helie P. Attaching and effacing and enterotoxigenic *Escherichia coli* associated with enteric colibacillosis in the dog. *Canadian Journal of Veterinary Research*. 1994 Apr;58(2):87.
30. Jonsson ME, Eriksson E, Boqvist S, Urdahl AM, Aspán A. Experimental infection in calves with a specific subtype of verocytotoxin-producing *Escherichia coli* O157: H7 of bovine

- origin. *Acta Veterinaria Scandinavica*. 2009 Dec 1;51(1):43.
31. Allen KJ, Rogan D, Finlay BB, Potter AA, Asper DJ. Vaccination with type III secreted proteins leads to decreased shedding in calves after experimental infection with *Escherichia coli* O157. *Canadian journal of veterinary research*. 2011 Apr 1;75(2):98-105.
32. Steele M, Ziebell K, Zhang Y, Benson A, Konczyk P, Johnson R, Gannon V. Identification of *Escherichia coli* O157: H7 genomic regions conserved in strains with a genotype associated with human infection. *Appl. Environ. Microbiol.*. 2007 Jan 1;73(1):22-31.
33. Latham WW, Grys TE, Witowski SE, Torres AG, Kaper JB, Tarr PI, Welch RA. StcE, a metalloprotease secreted by *Escherichia coli* O157: H7, specifically cleaves C1 esterase inhibitor. *Molecular microbiology*. 2002 Jul;45(2):277-88.
34. Hurley BP, Thorpe CM, Acheson DW. Shiga toxin translocation across intestinal epithelial cells is enhanced by neutrophil transmigration. *Infection and immunity*. 2001 Oct 1;69(10):6148-55.
35. Kaper JB, Nataro JP, Mobley HL. Pathogenic *Escherichia coli*. *Nature reviews microbiology*. 2004 Feb;2(2):123-40.
36. Spears KJ, Roe AJ, Gally DL. A comparison of enteropathogenic and enterohaemorrhagic *Escherichia coli* pathogenesis. *FEMS microbiology letters*. 2006 Feb 1;255(2):187-202.
37. Barba J, Bustamante VH, Flores-Valdez MA, Deng W, Finlay BB, Puente JL. A positive regulatory loop controls expression of the locus of enterocyte effacement-encoded regulators Ler and GrlA. *Journal of bacteriology*. 2005 Dec 1;187(23):7918-30.
38. Frankel G, Phillips AD. Attaching effacing *Escherichia coli* and paradigms of Tir-triggered actin polymerization: getting off the pedestal. *Cellular microbiology*. 2008 Mar;10(3):549-56.
39. Müller D, Benz I, Liebchen A, Gallitz I, Karch H, Schmidt MA. Comparative analysis of the locus of enterocyte effacement and its flanking regions. *Infection and immunity*. 2009 Aug 1;77(8):3501-13.
40. DeVinney R, Stein M, Reinscheid D, Abe A, Ruschkowski S, Finlay BB. Enterohemorrhagic *Escherichia coli* O157: H7 produces Tir, which is translocated to the host cell membrane but is not tyrosine phosphorylated. *Infection and immunity*. 1999 May 1;67(5):2389-98.
41. Guessous F, Marcinkiewicz M, Polanowska-Grabowska R, Kongkhum S, Heatherly D, Obrig T, Gear AR. Shiga toxin 2 and lipopolysaccharide induce human microvascular endothelial cells to release chemokines and factors that stimulate platelet function. *Infection and immunity*. 2005 Dec 1;73(12):8306-16.
42. Ibrahim OO. Food borne pathogen *Escherichia coli* O157: H7 history, sources of transmission, symptoms, detection and prevention. *EC Microbiol*. 2015;21:2.
43. Fukuda S, Toh H, Hase K, Oshima K, Nakanishi Y, Yoshimura K, Tobe T, Clarke JM, Topping DL, Suzuki T, Taylor TD. Bifidobacteria can protect from enteropathogenic infection through production of acetate. *Nature*. 2011 Jan;469(7331):543-7.
44. Fukuda S, Toh H, Taylor TD, Ohno H, Hattori M. Acetate-producing bifidobacteria protect the host from enteropathogenic infection via carbohydrate transporters. *Gut microbes*. 2012 Sep 20;3(5):449-54.
45. Bergstrom KS, Kisoos-Singh V, Gibson DL, Ma C, Montero M, Sham HP, Ryz N, Huang T, Velcich A, Finlay BB, Chadee K. Muc2 protects against lethal infectious colitis by disassociating pathogenic and commensal bacteria from the colonic mucosa. *PLoS pathogens*. 2010 May;6(5).

46. Johansson ME, Hansson GC. Preservation of mucus in histological sections, immunostaining of mucins in fixed tissue, and localization of bacteria with FISH. In *Mucins 2012* (pp. 229-235). Humana Press.
47. Boyd B, Tyrrell G, Maloney M, Gyles C, Brunton J, Lingwood C. Alteration of the glycolipid binding specificity of the pig edema toxin from globotetraosyl to globotriaosyl ceramide alters in vivo tissue targeting and results in a verotoxin 1-like disease in pigs. *The Journal of experimental medicine*. 1993 Jun 1;177(6):1745-53.
48. Betz J, Bielaszewska M, Thies A, Humpf HU, Dreisewerd K, Karch H, Kim KS, Friedrich AW, Müthing J. Shiga toxin glycosphingolipid receptors in microvascular and macrovascular endothelial cells: differential association with membrane lipid raft microdomains. *Journal of lipid research*. 2011 Apr 1;52(4):618-34.
49. Meyers KE, Kaplan BS. Many cell types are Shiga toxin targets. *Kidney international*. 2000 Jun 1;57(6):2650-1.
50. Ethelberg S, Olsen KE, Scheutz F, Jensen C, Schiellerup P, Engberg J, Petersen AM, Olesen B, Gerner-Smidt P, Mølbak K. Virulence factors for hemolytic uremic syndrome, Denmark. *Emerging infectious diseases*. 2004 May;10(5):842.
51. DuPont HL, Ericsson CD, Farthing MJ, Gorbach S, Pickering LK, Rombo L, Steffen R, Weinke T. Expert review of the evidence base for self-therapy of travelers' diarrhea. *Journal of travel medicine*. 2009 May 1;16(3):161-71.
52. Naylor SW, Low JC, Besser TE, Mahajan A, Gunn GJ, Pearce MC, McKendrick IJ, Smith DG, Gally DL. Lymphoid follicle-dense mucosa at the terminal rectum is the principal site of colonization of enterohemorrhagic *Escherichia coli* O157: H7 in the bovine host. *Infection and immunity*. 2003 Mar 1;71(3):1505-12.
53. Jones RM, Neish AS. Recognition of bacterial pathogens and mucosal immunity. *Cellular microbiology*. 2011 May;13(5):670-6.
54. Kamada N, Seo SU, Chen GY, Núñez G. Role of the gut microbiota in immunity and inflammatory disease. *Nature Reviews Immunology*. 2013 May;13(5):321-35.