

Ultra-Sonographic Evaluation and Growth Factors Measurement of Using Tendon Derived Hydrogel and Hyaluronic Acid in Tendon Repair in Rams

Omar Tariq Hammoodi^{1*} and Serwa I. Salih²

¹Department of Obstetrics and Surgery, College of Veterinary Medicine, University of Fallujah, Iraq.

²Department of Obstetrics and Surgery, College of Veterinary Medicine, University of Baghdad, Iraq.

*Corresponding author : omar.hammoodi@gmail.com

Doi: <https://doi.org/10.37940/AJVS.2019.12.2.2>

This article is licensed under a CC BY (Creative Commons Attribution 4.0)

<http://creativecommons.org/licenses/by/4.0/>.

Abstract

The present study was planned to evaluate the efficacy of tendon derived hydrogel and hyaluronic acid in repair of experimentally induced superficial digital flexor tendon defect in rams, ultrasonographically with detection of vascular endothelial growth factor (VEGF) and basic fibroblast growth factor (bFGF) in blood. Thirty six adult rams were divided randomly into three equal groups: First group (control group) rams were subjected to partial removal of the superficial digital flexor tendon (SDFT), second group (tendon derived hydrogel group): rams were subjected to the same procedure as mentioned in first group except that the tendon defect was filled with tendon derived hydrogel directly, while third group (hyaluronic acid group): same procedure as in first group but the tendon defect was filled with hyaluronic acid directly. Clinically there was no pain, no infection, no signs of rejection and all wounds had healed completely in all rams, normal body temperature, except for the swelling which appeared in the first group in one ram at 30 days post operatively and two rams in third group at 60 days post operatively, all animals were able to stand and showed normal gait. Ultrasonographic results at 120th day post operation in first group showed, hypoechoic to hyperechoic regions at the site of the defect. At the same period for the second group the sonogram showed, well-aligned echoic tendon structure, while in the third group at the same period there were hypoechoic areas at the site of the defect. The results of bFGF and VEGF detection showed significant differences between the periods in first group at $P \leq 0.05$, while in second and third groups there were significant differences at $P \leq 0.01$ for bFGF. The results of detection VEGF showed, significant differences in the mean values among the periods at $P \leq 0.01$ in first group, also second group there was significant differences at $P \leq 0.01$. And in third group there was a significant difference at $P \leq 0.05$. Also there were significant differences among all groups $P \leq 0.01$ in at 60th day postoperatively. In conclusion the tendon derived hydrogel matrix and the hyaluronic acid have a regenerative effect in repair of tendons injuries, but the superiority is for tendon derived hydrogel matrix.

Keywords: Tendon, Growth factors, Tendon derived hydrogel, ultrasound of tendon, Hyaluronic acid.

التقييم بالامواج فوق الصوتية وقياس عوامل النمو لاستخدام الهلام المائي المستمد من الوتر وحمض الهيالورونيك في اصلاح الوتر في الكباش

الخلاصة

صممت الدراسة لتقييم كفاءة الهلام المائي المستمد من الوتر وحمض الهيالورونيك في اصلاح العيب المحدث تجريبيا في وتر القابضة الاصبعية السطحية في الكباش عن طريق الفحص بالامواج فوق الصوتية والكشف عن عاملي النمو في الخلايا الليفية الاساسية ونمو الاوعية الدموية البطانية في الدم. تم تقسيم ست وثلاثون كبشا بالغاً عشوائياً الى ثلاثة مجاميع متساوية، المجموعة الاولى (مجموعة السيطرة)، اخضعت لازالة جزء من وتر القابضة الاصبعية السطحية، اما المجموعة الثانية (مجموعة الهلام المائي المستمد من الوتر) فقد اخضعت لنفس الاجراء السابق باستثناء ملاً العيب المحدث بالهلام المائي المستمد من الوتر، والمجموعة الثالثة (مجموعة حمض الهيالورونيك) ايضا اخضعت لنفس الاجراء الجراحي الا ان العيب المحدث في الوتر قد ملاً بحمض الهيالورونيك.

اظهرت نتائج الفحص السريري عدم وجود ألم، او خمج وعدم وجود علامات رفض، والتئمت كل الجروح بشكل كامل في كل الكباش، درجات حرارة الجسم كانت طبيعية، باستثناء التورم الذي ظهر في المجموعة الاولى في كبش واحد بعد 30 يوم من العملية الجراحية، وفي كبشين في المجموعة الثالثة بعد 60 يوم من العملية وكانت جميع الحيوانات قادرة على الوقوف واظهرت مشية طبيعية. أظهرت نتائج الفحص بالامواج فوق الصوتية في اليوم 120 في مجموعة السيطرة مناطق تتراوح بين قليلة الصدى و مفرطة الصدى في منطقة الاذى، بينما خلال نفس الفترة اظهرت نتائج الامواج فوق الصوتية في مجموعة الهلام المائي المستخلص من الوتر منطقة سقالة صدوية بشكل جيد، أما في مجموعة الهيالورونيك وفي نفس الفترة كانت هناك مناطق قليلة الصدى في منطقة الخلل في الوتر. بين التحليل الاحصائي لنتائج الكشف عن عامل نمو الخلايا الليفية الاساسية (bFGF) وعامل نمو الاوعية الدموية البطانية (VEGF) في مصل الدم لكل الكباش في المجاميع الثلاثة. ان هناك فروقات معنوية بين الفترات في مجموعة السيطرة عند مستوى ($P \leq 0.05$)، كذلك في مجموعة الهلام المائي المستخلص من الوتر و مجموعة المعالجة بحمض الهيالورونيك كانت هناك فروقات معنوية عند مستوى ($P \leq 0.01$) هذا بالنسبة للعامل الاول (bFGF). اما بالنسبة لعامل النمو الثاني (VEGF) فقد كانت هناك فروقات معنوية في معدل جميع القيم بين الفترات عند مستوى ($P \leq 0.01$) في مجموعة السيطرة، وايضا في مجموعة المعالجة بالهلام المائي المستخلص من الوتر كانت هناك فروقات معنوية عند مستوى ($P \leq 0.01$)، وفي المجموعة المعالجة بحمض الهيالورونيك كانت هناك فروقات معنوية عند مستوى ($P \leq 0.05$)، و كذلك وجدت فروقات معنوية بين المجاميع الثلاثة عند مستوى ($P \leq 0.01$) عند اليوم 60 بعد العملية. نستنتج من هذه الدراسة ان سقالة الهلام المائي المستخلصة من الوتر وحمض الهيالورونيك لهما تأثير ايجابي في علاج اصابات الاوتار الا ان الافضلية للهلام المائي المستخلص من الوتر.

Introduction

Tendon Injuries can be either intrinsic in the form of strain or extrinsic in the form of percutaneous injuries. Skin lacerations are associated with the latter, while overstrain injuries resulting from sudden structure overloading (1). The emerging field of Tissue Engineering and Regenerative Medicine is increasingly being employed to design strategies for the repair of tendon tissue. These strategies are focused on the activation and enhancement of the body's own repair system by using a combinatory approach that may include the application of cells, stimulatory factors, genes, and scaffolds (2). The published researches describe the production of decellularized scaffolds from non-homologous anatomical sites such as using of small intestine submucosa (3-4), Bovine Urinary Bladder Sub-mucosa (5), and pericardium and platelet-rich fibrin matrix (PRFM) (6). In the last decade researches had also shown the efficacy of extracellular matrix hydrogels derived from the tissue targeted for treatment of tendon injuries (7-8). Several attempts had been made to prepare Tendon derived hydrogel for augmentation of tendon repair (8-9).

The release of growth factors in specific time is necessary to achieve tendon healing; these growth factors are promoted the healing of tendon when applying them in optimal doses. There are five growth factors important in tendon healing, these are: vascular endothelial growth factor (VEGF), basic fibroblast growth factor (bFGF) insulin-like growth factor (IGF), platelet-derived growth factor (PDGF) and transforming growth factor (TGF), (10-11). Physiologically, they are synthesized and secreted by platelets, fibroblasts, inflammatory cells and vascular endothelial cells. These growth factors are bind to the external receptors and influences cellular mitogenesis and thus the healing cascade (12). Tendon injury stimulates the release of growth factors at different stages of tendon healing (13) resulting in increased cellularity and tissue volume (14). Growth factors expressions are increased in the early phases of tendon healing (15-16).

Hydrogels consist of natural biomaterials such as collagen, hyaluronic acid, fibrin alginate, and proteins from extra cellular matrix which appropriate materials for applications in biomedical field due to their good biocompatibility, high water content, interaction with living tissues, and elastic consistency (17). Tissue derived hydrogels are better matching

with the original tissue as they contains the compositions of the extracellular matrix, in addition to the biological and chemical cues inherent to these components of the matrix (7;18;19). The solution of extracellular matrix with suitable viscosity can be delivered by injection, and then conform to the 3D space following deposition (8). The thermos responsive performance assist the polymerization process and form a gel at the temperature of body, producing a structure suitable for host cell infiltration and remodeling (20). The aim of this study is to evaluate tendon derived hydrogel and hyaluronic acid in repair of experimentally induced superficial digital flexor tendon defect in rams ultrasonographically and with detection of VEGF and bFGF in blood.

Materials and Methods

Thirty six apparently healthy local breed rams were recruited for this study. These were between (1-2) years of age and weighed (30-40) Kg. All animals were evaluated clinically before initiation of the experiment. They were housed in the animal farm of the College of Veterinary Medicine, University of Baghdad and they were precondition in the animal's house for 21 days before operation. All rams were housed in pairs in (3x2.5) meters pens for the entire experiment and were numbered. All rams were vaccinated by Co- Baghdad (Syva- Bax) ® against enterotoxaemia in a dose of 5ml. subcutaneously and also dewormed with Ivermectin (Evanomic, Spain) 0.2 mg/Kg B.W. subcutaneously. The present study was approved by the Animal Welfare and Ethics Committee and Faculty of Veterinary Medicine/ University of Baghdad.

Tendon Decellularization and Processing was carried out according to Pridgen *et al.*, (21) and the Formation of the gel according to Zhang *et al.*, (22).

Pre- operative considerations

The food was held for 24hrs. , and water restricted for 12 hours before operation. The

animal was restrained in right lateral position after light sedation by using Xylazine (Bayer-Germany) 2% in a dose rate of 0.2 mg / Kg B.W intramuscular (22). The left forelimb was prepared for surgical operation starting from the carpal joint downward to the fetlock joint and tourniquet was applied directly above the carpal joint for the controlling of bleeding during the operation. The site of operation was anesthetized by ring block using 2% lidocaine hydrochloride at a dose of 4 mg / Kg B.W. (23-24).

Surgical technique

Slightly lateral to site of the superficial digital flexor tendon (SDFT) a straight incision approximately 5cm. long was made through the skin covering the flexor tendons of the left forelimb, then passed down to the subcutaneous tissues. The edges of the skin were reflected laterally to expose the dorsal surface of the SDFT. Separation of the SDFT from the corresponding DDFT was performed by blunt dissection and then a curved artery forceps was introduced beneath the SDFT to expose it. Parallel incisions were made in the tendon 0.2 cm apart and 1 cm long, and then with a fine surgical scissor the scored section was removed to create a partial defect in the mid substance (Figure 1 A,B,C). These steps were conducted similarly in the three groups with exception of application of normal saline in the first group, tendon derived hydrogel in the second group directly and hyaluronic acid was applied in the defect in the third group (Figure 1D). Subcutaneous tissues were closed using 4-0 absorbable suture material (Vicryl) with simple continuous pattern, and then the skin was sutured using non absorbable suture material (silk No. 0) with interrupted horizontal mattress. The operated limb was immobilized with External fixation device (backslab) to limit the motion.

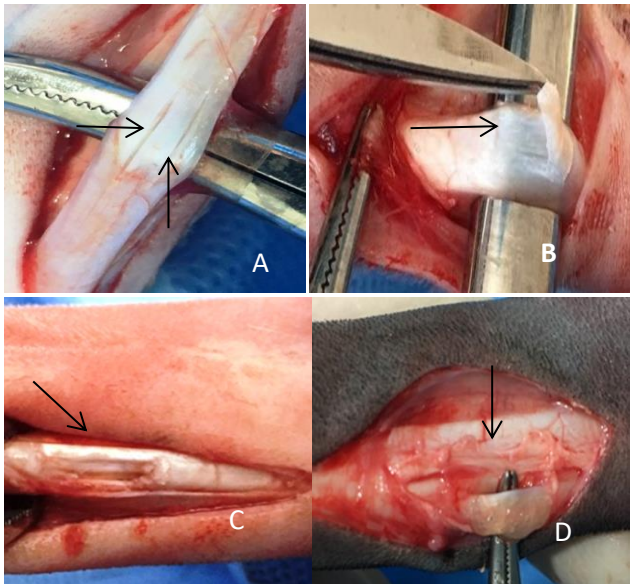


Figure (1): shows (A) Parallel longitudinal incisions. (B) Removal of part of the tendon's structure. (C) The created defect in SDFT. (D) The application of hydrogel.

Each animal was housed individually in confined pen to restrict its activity, monitor the wound until the removal of skin stitches on the 10th day post-surgery. Pencillin streptomycine in a dose rate of 10000 I.U and 5mg /Kg B.W respectively were injected IM for 5 consecutive days. Skin incisions were checked daily till complete wound healing at the time of stiches removal after 10 days. The external fixation device was re applied for fifteen days and then removed. A complete clinical examination was performed on all animals, (24 and 48) hours after creation of injury, on day of treatment, and daily for the first 4weeks and twice weekly for the remaining period to evaluate and monitoring the local heat and pain this was closely monitored by palpation during the post- operative period. Complete clinical follow up, growth factors evaluation in serum to detect VEGF and bFGF basic fibroblast growth factor at (5,15, 30, 60, and 120 days), ultrasonographical examination were performed for each group at (30, 60, and 120 days) post-surgical repair.

The blood samples were collected aseptically from the jugular vein of each rams in

a test tube without anticoagulant or serum separator by using a vacutainer needle 20-gauge by one-inch and a vacutainer. After that it was left to allow the formation of blood clot at room temperature for 15–30 minutes then centrifuged at 3000 rpm for 10 minutes to remove the clot and then the serum were transferred into 0.5 Eppendorf tube and stored at -20°C according to Barger and Macneill, (25). The serum samples were analyzed by enzyme-linked immunosorbent assay technique (ELISA) with using of specific sheep vascular endothelial growth factor (VEGF) and sheep basic fibroblast growth factor (bFGF) ELISA kits (My Bio Source, USA) for detection the value of these growth factors at (0,5,15,30,60 and 120 days).

The tendons were evaluated using WellD Ultrasonographic Machine (WED-9618V, China) with a linear (7.5) MHz transducer, for monitoring the tendons at (30, 60, and 120 days) postoperative. Ultrasonography were recorded prior to creation of tendon defect were served as control images. All the ultrasonographical examinations of palmar metacarpal regions were done with the animals sedated and restrained. Longitudinal images were obtained to the echogenicity and the fibers alignment at the site of the defect.

The Statistical Analysis System- SAS (2012) program was used for statistical analysis in the present study. One way analysis of variance (ANOVA) was used to test differences between groups. Least Significant Difference-LSD test at $P \leq 0.05$ and $P \leq 0.01$ were used to test mean of the groups.

Results and Discussion

Clinical examination of the operation site revealed no pain, no infection, no signs of rejection and all wounds had healed completely in all rams, normal body temperature, Except for the swelling which appeared in the first group in one ram at 30 days and two rams in third group at

60 days. All animals were able to stand and showed normal gait.

The detection results of bFGF mean values showed nonsignificant differences at zero time among the three groups. In first group there were decreased in the levels at 5th day, then showed increased at both 15th and 30th day in which reached to the peak, after that at 60th and 120th day it showed gradual decrease in the mean values until reached near to the baseline before surgery at 120th day. In second group the detection results showed increased in the mean values at 5th day, the decreased at both 15th and 30th day, after that at 60th day posttreatment showed increased in the values which peaked at this time, and then decreased to reach near the baseline at zero time. In third group there were increased in the mean values starting from 5th day and reached the peak at 30th day, then decreased gradually at 60th and 120th day at which reached near to the baseline.

The results of detection bFGF in the three groups were reflected by the mean values of bFGF (pg/ml) in table (1). There were significant differences between the periods in first group at $P \leq 0.05$, and reached the peak (63.51 ± 13.54) at 30th day postoperatively. Also in second group there were significant differences at $P \leq 0.01$ but reached the peak (108.77 ± 24.6) at 60th day posttreatment. While in third group the significant differences among the period at $P \leq 0.01$ and reached to the peak (62.28 ± 8.58) at 30th day posttreatment.

The result of detection VEGF showed non-significant differences among the three groups at zero time. The mean values of VEGF were increased starting from 5th day to 30th in which reached to the peak in all groups, then decreased at 60th and 120th day and reached to the base line of the VEGF level preoperatively. The results of detection VEGF of all rams in the three groups were reflected by the mean values of VEGF (pg/ml) in table (2). There were significant

differences in the mean values among the periods at $P \leq 0.01$ in first group, which reached to the peak (843.0 ± 138.5) at 30th day postoperatively, also second group there were significant differences at $P \leq 0.01$ and peaked (781.4 ± 105.8) at 30th day posttreatment and in third group the peaked (893.5 ± 132.2) at 30th day with significant differences at $P \leq 0.05$. Also there are significant differences among all groups $P \leq 0.01$ in at 60th day postoperatively.

The ultrasonography images showed, anechoic to hypoechoic area at the site of defect and presence of swelling 30 days post operation in first group (Figure 2), while in third group there was no swelling at the site of operation, and wide area of hypo to hyper echogenicity, 30 days posttreatment (Figure 3), and in second group the longitudinal ultrasonography of the SDFT showed, clear area of hypo to hyper echogenicity with the superiority of hyper echogenicity at the site of the defect 30 days posttreatment (Figure 4). On the 60th day post operation the ultrasonography showed, disappearance of swelling with presence of limited anechoic area in addition to hypo echogenicity in first group, 60 days post operation (Figure 5). In third group the ultrasonography showed, hypo to hyper echogenicity at the site of the defect 60 days posttreatment (Figure 6). While in second group the sonogram showed, hyper echogenicity at the site of the defect at the same period (Figure 7).

At 120 days postoperatively in first group, the ultrasonography images showed, hypo to hyper echogenicity at the site of the defect (Figure 8), while in third group the resulted ultrasonography images showed limited area of hypo echogenicity, wide area of hyper echogenicity and presence signs of tendon regeneration which can be detected through the tendon fibers alignment at the site of the defect (Figure 9), also in second group at the same period the ultrasonography images showed that the tendon restore the normal architecture which

noticed by the appearance of clear area, normal echogenicity, and well fibers alignment at the site of the defect (Figure 10).

In the present study, the result of growth factors evaluation in serum to detect bFGF showed no significant changes between the values of the bFGF in all groups at 0 day (pre-surgery). These results were used as a baseline for the value of the bFGF in each group. In first group there were decreased in the levels at 5th day, then showed increased at both 15th and 30th day in which reached to the peak, after that at 60th and 120th day it showed gradual decrease in the mean values until reached near to the baseline before surgery at 120th day.

On the 5th day postoperatively the result of bFGF in the second group showed increased in the value, and then appeared with gradual decrease in both 15 and 30 days, while in 60 days it reached to the peak which presented with more than double of the baseline value. On 120 days the value retracted toward the baseline. The elevated of bFGF in first week of healing process, possibly in response to the inflammation after trauma, and as the healing progress, the expression of bFGF declined rapidly after the first week of healing, this might be due to the inflammation which resolved at this time and then increased again strongly, probably reflecting remodeling and scar formation in the late stages of tendon healing. These results agree with Wurgler-Hauri *et al.*, (15); Heisterbach *et al.*, (16) and Farnebo *et al.* (26).

The results of bFGF in the third group showed gradual increase of the values from the 5th day to the 30th day, these are due to the presence of inflammatory cells at this time of healing, and then bFGF decreased on both 60th and 120th day, related to the decrease of the inflammatory cells. These results come in agreement with Dean *et al.*, (27) who found that local application of hyaluronic acid causes release of endogenous bFGF which resulting in faster cell proliferation

during early stages of tendon healing and agree with Chang and Hsu; Kobayashi *et al.*, (28-29) who showed that bFGF is upregulated in the tendon wound environment, and upregulated in tenocytes as well as in tendon sheath fibroblasts and inflammatory cells. The results of bFGF in the present study showed increased the value in second group earlier than first group and third group, suggesting that tendon derived hydrogel has the ability to attract the inflammatory cells to the site of the defect. This is parallel to the study of Chen *et al.*, (9).

VEGF is effective in stimulating angiogenesis and increasing endothelial cell proliferation and cell migration and increases collagen deposition at tendon injury site (30-31). Angiogenesis is important in both, tendon degeneration in cases of impaired blood supply, and in regeneration, for which the best possible capillary permeability is desirable (32). The activity of VEGF rises after the inflammatory phase, especially during the proliferative and remodeling phases (33).

In the present study, the result of growth factors evaluation in serum to detect VEGF showed no significant changes between the values of the VEGF in all groups at 0 times (pre-surgery). These results were used as a baseline for the value of in each group. In first group the results showed increased the mean values of VEGF starting from 5th day (515 ± 69.2) to 30th day (843.0 ± 138.5) in which reached to the peak and then decreased at 60th and 120th day and reached to the base line of the VEGF level preoperatively. In second group showed slight increase of the mean value on the 5th day (600.0 ± 132.4) postoperatively and reached to the peak on the 30th day (781.4 ± 105.8), then downregulated toward the baseline from the 60th to 120th day postoperatively. These results agree with Boyer *et al.* (34); Petersen *et al.*, (35); and Lipman *et al.*, (36) they found that VEGF promotes angiogenesis in tendon healing; it is most active during the proliferation and

remodeling phases. The increases in VEGF after the inflammatory phase, especially during the proliferation and remodeling phases of tendon healing, parallel to subsequent vascular ingrowth from epitendinous and intratendinous blood vessels toward the area of tendon injury. This neovascularization serves to provide nutrients and additional growth factors to the injured site.

The results of VEGF in third group showed upregulation in the value at 5th, 15th, and peaked on 30th day postoperatively, and then downregulation appeared at 60 days to the end time of experiment at 120 days. These results agree with studies by Thomopoulos *et al.* (37) who found an increase in vessel length and density starting from third post-operative day, which peaked at four weeks, and was followed by a decrease in vessel density at six week on the canine flexor tendon. Also comes in agreement with study of Petersen *et al.*, (35) who found that increased expression of VEGF accompanied by a high vascular density during the first 12 weeks of tendon graft remodeling.

In the present study, the ultrasonography of the normal SDFT was highly echogenic and this result is similar to that found by Hans *et al.*, (38) who verified that normal tendon tissue is highly echogenic because of its composition of longitudinally arranged densely packed structures such as collagen fibrils. Sonogram assessment of the surgical induced defect in SDFT in all groups of the present study at 30th day postoperatively revealed that the core lesion was characterized by decreased or absence of normal tendon echogenicity with complete loss of the normal characteristic of longitudinal aligned fiber pattern. The same findings were observed by the study of Schramme *et al.*, (39) and Zandim *et al.*, (40). The changes observed within the core lesions could be attributed to intratendinous edema, hemorrhage, mechanical rupture of tendon fibers and the action of inflammatory exudate. The same findings were reported by Zandim *et al.*, (40).

The longitudinal ultrasonographies of the first group and third group resulted from this study at 60th day postoperatively showed the defect still existed with variable echogenicity at the site of defect and presence of mixed echoic density alongside the tendon structure. These findings agreed with Roger and Smith (41). The chronic pathology of the SDFT is characterized by a heterogeneous pattern of variable amounts of hypo echogenicity and hyper echogenicity. Poor tendon border definition has been suggested to be a sign of adhesions. While, at the same period in the treated group with tendon derived hydrogel the sonogram was showed, the presence of hyperechoic areas at the site of the tendon defect, which Indicates the improvement of tendon echogenicity become faster in second group. This finding comes in agreement with Nezhir *et al.*, (42) and Mostafa *et al.*, (43). Improvement in echogenicity and fiber alignment occurred during tendon repair reflects the presence of immature granulation tissue with active fibrogenesis and collagen production associated with increased in the acoustic density (43).

On 120th day post-operation, the ultrasonographies showed the presence of hypoechoic and hyperechoic regions alongside of SDFT with echoic lines in first group. While, in third group, the ultrasonography showed limited area of hypo echogenicity, wide area of hyper echogenicity and presence signs of tendon regeneration which can be detected through the tendon fibers alignment at the site of the defect. While, the sonogram of second group were showed, the tendon restore the normal architecture which noticed by the appearance of clear area of normal echogenicity, and well fibers alignment at the site of the defect. These come in agreement with the result of AL-Bayaty *et al.*, (44) who found that ultrasonography of the treated groups at 16 weeks showed infiltration of more echogenic foci, increased echogenicity and the fibers appeared more parallel and more organized. Also the result of present study agrees

with Zwingenberger *et al.*, (45) who verified that the healed tendon in the remodeling phase will be normal to hyperechoic in appearance, narrowed, reorganization or realignment of the tendon fibers within the area of the injury. In addition, the tendon sonogram at remodeling stage could not be distinguished from normal tendons.

The progressive increasing of lesions echogenicity, gradual fiber alignment observed in the present study were considered as evidences of better quality tendon repair as investigated by the study of Bosch *et al.*, (46) and Zuffova *et al.*, (47). They stated that improvement in echogenicity and fiber alignment attributed to early granulation formation, cellular proliferation and

differentiation, gradual arrangement of tendon fibers bundle, and minimized scar tissue and adhesions.

Conclusion

In conclusion, the results of this study confirmed that there was synchronization between the results of different parameters. They were appeared that the tendons treated by TDH compare to HA-treated and control groups have best clinical appearance, well tendon tissues architecture ultrasonography, less adhesion macroscopically, highly vascularity and collagen fibers alignment detected histopathologically which supported by effective level of bFGF and VEGF gene level.

Table (1): Shows the mean values of (bFGF) (pg/ml).

Group	Period						P-value
	0	5	15	30	60	120	
C	45.56 ± 4.01	41.75 ± 12.43	52.52 ± 21.23	63.51 ± 13.54	49.81 ± 6.86 b	43.37 ± 2.42 b	0.020 *
T	50.4 ± 18.91	63.33 ± 29.61	62.74 ± 28.64	54.73 ± 23.62	108.7 ± 24.6 a	51.02 ± 10.96 a	0.001 **
H	43.06 ± 5.34	49.26 ± 3.81	51.30 ± 10.37	62.28 ± 8.58	46.05 ± 3.31 b	44.33 ± 1.85 b	0.001 **
P-value	0.444 ^{ns}	0.064 ^{ns}	0.473 ^{ns}	0.484 ^{ns}	0.001 **	0.010 **	

®One way ANOVA were used to test between groups and periods. Least significant differences (LSD) were used to compare means. *(P≤0.05), ** (P≤0.01), NS: Non-significant. **a,b** = Means that do not share a letter vertically are significantly different between groups

Table (2): Shows the mean values of (VEGF) (pg/ml).

Group	Period						P-value
	0	5	15	30	60	120	
C	515 ± 69.2	692.7 ± 223.9	767.5 ± 129.5	843.0 ± 138.5	764.73 ± 21.8 a	511.58 ± 9.86	0.001**
T	524.3 ± 161.3	600.0 ± 132.4	619.6 ± 190.8	781.4 ± 105.8	553.0 ± 71.2 b	530.55 ± 48.4	0.004 **
H	538.7 ± 97.3	703.9 ± 74.8	751.4 ± 104.1	893.5 ± 132.2	801.8 ± 108.8 a	545.6 ± 68.2	0.032*
P-value	0.910 ^{ns}	0.319 ^{ns}	0.082 ^{ns}	0.190 ^{ns}	0.001 **	0.704 ^{ns+}	

®One way ANOVA were used to test between groups and periods. Least significant differences (LSD) were used to compare means. *(P≤0.05), ** (P≤0.01), NS: Non-significant. **a,b**= Means that do not share a letter vertically are significantly different between groups

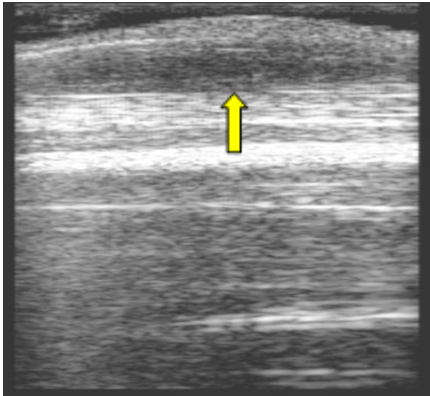


Figure (2): longitudinal ultrasonography of the SDFT shows, swelling at the site of operation due to fluid accumulation (anechoic to hypoechoic) (arrow) in first group, 30 days post operation

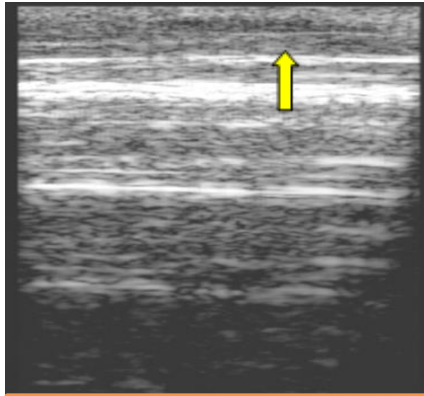


Figure (3): longitudinal ultrasonography of the SDFT shows, no swelling at the site of operation, no tendon fibers damage, and wide area of hypo to hyper echogenicity in third group, 30 days posttreatment.

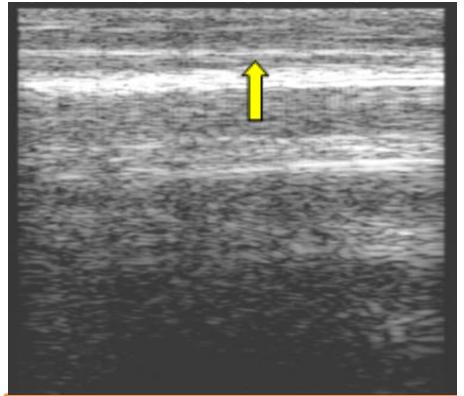


Figure (4): longitudinal ultrasonography of the SDFT shows, clear area of hypo to hyper echogenicity with the superiority of hyper echogenicity (Arrow) in second group, 30 days posttreatment

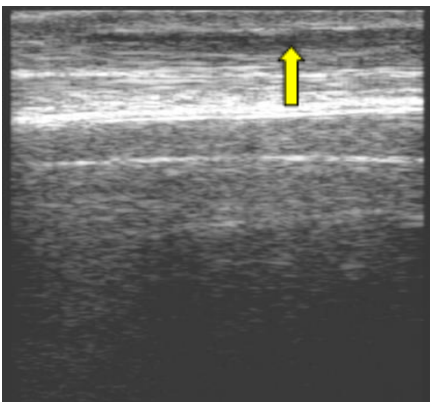


Figure (5): longitudinal ultrasonography of the SDFT shows, disappearance of swelling with presence of limited anechoic area in addition to hypo echogenicity (Arrow) in first group, 60 days post operation.

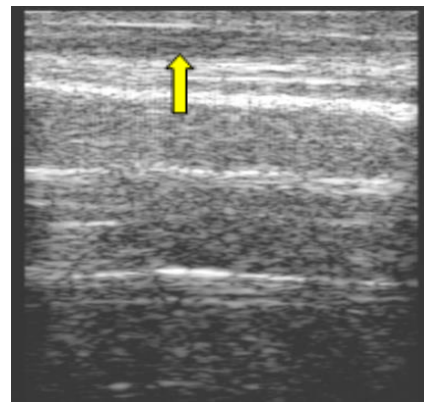


Figure (6): longitudinal ultrasonography of the SDFT shows, hypo to hyper echogenicity at the site of the defect in third group, 60 days posttreatment.

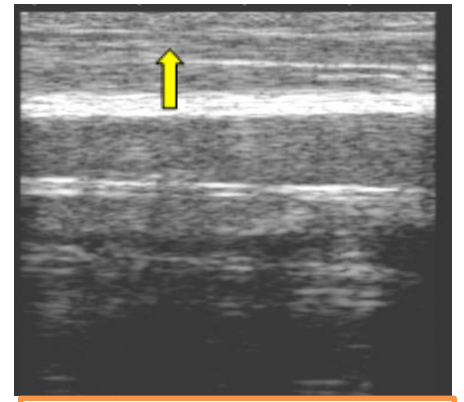


Figure (7): longitudinal ultrasonography of the SDFT shows, hyper echogenicity at the site of the defect in second group, 60 days posttreatment.

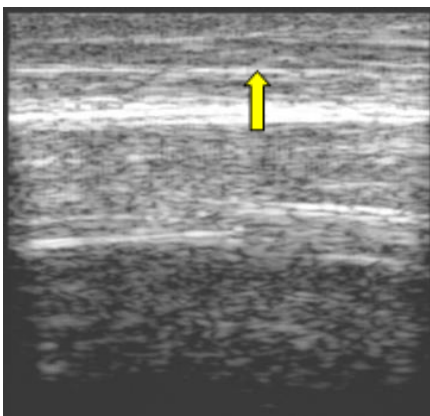


Figure (8): longitudinal ultrasonography of the SDFT shows, hypo to hyper echogenicity at the site of the defect (Arrow) in first group, 120days post operation.

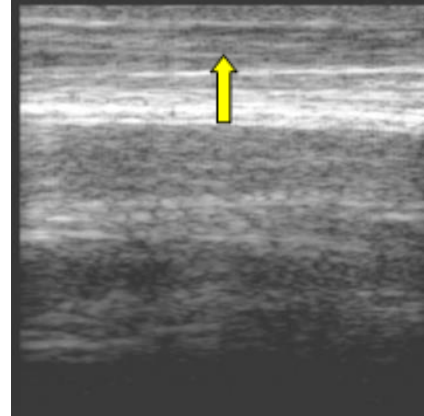


Figure (9): longitudinal ultrasonography of the SDFT shows, limited area of hypo echogenicity and wide area of hyper echogenicity and presence signs of tendon regeneration which can be detected through the tendon fibers alignment at the site of the defect (Arrow) in third group, 120 days posttreatment.

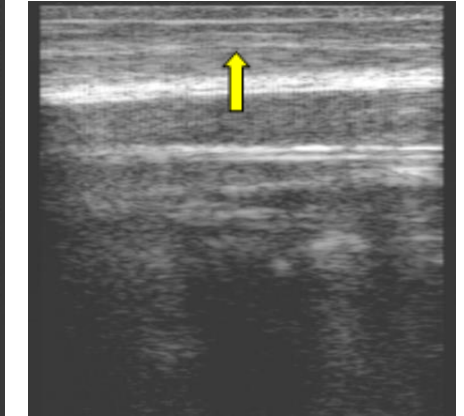


Figure (10): longitudinal ultrasonography of the SDFT shows, the tendon restore the normal architecture which noticed by the appearance of clear area, normal echogenicity, and well fibers alignment at the site of the defect in second group, 120 days posttreatment

References

1. Mienaltowski MJ, Birk DE. Structure, physiology, and biochemistry of collagens. In *Progress in heritable soft connective tissue diseases 2014* (pp. 5-29). Springer, Dordrecht.
2. Moshiri A, Oryan A. Tendon and ligament tissue engineering, healing and regenerative medicine. *J Sports Med Doping Stud.* 2013;3(2):126.
3. Salih, SI, AL-Falahi NH, and Hammoodi OT. Using of small intestine submucosa in the healing of digital flexor tendon in goat. 9th conference of the college of Veterinary Medicine University Of Baghdad, 2009.
4. Mohammed FM. Using of ovine small intestinal submucosa for repairing experimental defect of Achilles tendon in indigenous dogs. *Al-Anbar Journal of Veterinary Sciences.* 2015;8(2):54-64.
5. AL-Abedi AJ, and AL-Bayati AH. Effect of Bovine Urinary Bladder Sub-mucosa on Tendon Reconstruction in Equine Species. Ph.D. thesis. College of Veterinary Medicine- University of Baghdad. –Iraq, 2013.
6. AL-Falahi NH, Salih SI. A comparative histopathological study of repaired tendons wrapped with two biological matrices in bucks. *Adv. Anim. Vet. Sci.* 2016;4(3):145-52.
7. Wolf MT, Daly KA, Brennan-Pierce EP, Johnson SA, Carruthers CA, D'Amore A, Nagarkar SP, Velankar SS, Badylak SF. A hydrogel derived from decellularized dermal extracellular matrix. *Biomaterials.* 2012 Oct 1;33(29):7028-38.
8. Kim MY, Farnebo S, Woon CY, Schmitt T, Pham H, Chang J. Augmentation of tendon healing with an injectable tendon hydrogel in a rat Achilles tendon model. *Plastic and reconstructive surgery.* 2014 May 1;133(5):645e-53e.
9. Chen Z, Rui Y, Xu Y, Zhang Q, Sun Z, Zhou J, Chen X. Effect of tendon hydrogel on healing of tendon injury Retraction in/10.3892/etm. 2018.6022. *Experimental and therapeutic medicine.* 2017 Nov 1;14(5):3955-60.
10. Molloy T, Wang Y, Murrell GA. The roles of growth factors in tendon and ligament healing. *Sports medicine.* 2003 Apr 1;33(5):381-94.
11. Branford OA, Klass BR, Grobbelaar AO, Rolfe KJ. The growth factors involved in flexor tendon repair and adhesion formation. *Journal of Hand Surgery (European Volume).* 2014 Jan;39(1):60-70.
12. Oliva F, Via AG, Maffulli N. Role of growth factors in rotator cuff healing. *Sports medicine and arthroscopy review.* 2011 Sep 1;19(3):218-26.
13. Yang G, Rothrauff BB, Tuan RS. Tendon and ligament regeneration and repair: clinical relevance and developmental paradigm. *Birth defects research part C: embryo today: reviews.* 2013 Sep ;99 (3):203-22.
14. Sharma P, Maffulli N. Biology of tendon injury: healing, modeling and remodeling. *Journal of musculoskeletal and neuronal interactions.* 2006 Apr; 6 (2):181.
15. Würzler-Hauri CC, Dourte LM, Baradet TC, Williams GR, Soslowsky LJ. Temporal expression of 8 growth factors in tendon-to-bone healing in a rat supraspinatus model. *Journal of shoulder and elbow surgery.* 2007 Sep 1; 16 (5) :S198-203.
16. Heisterbach PE, Todorov A, Flückiger R, Evans CH, Majewski M. Effect of BMP-12, TGF- β 1 and autologous conditioned serum on growth factor expression in Achilles tendon healing. *Knee Surgery, Sports Traumatology, Arthroscopy.* 2012 Oct 1;20(10):1907-14.
17. Claudio-Rizo JA, Rangel-Argote M, Castellano LE, Delgado J, Mata-Mata JL, Mendoza-Novelo B. Influence of residual composition on the structure and properties of extracellular matrix derived hydrogels. *Materials Science and Engineering: C.* 2017 Oct 1;79:793-801.
18. Johnson TD, Lin SY, Christman KL. Tailoring material properties of a nanofibrous extracellular matrix derived hydrogel. *Nanotechnology.* 2011 Nov 21;22(49):494015.

19. DeQuach JA, Lin JE, Cam C, Hu D, Salvatore MA, Sheikh F, Christman KL. Injectable skeletal muscle matrix hydrogel promotes neovascularization and muscle cell infiltration in a hindlimb ischemia model. *European cells & materials*. 2012 Jun 5;23:400.
20. Freytes DO, Martin J, Velankar SS, Lee AS, Badylak SF. Preparation and rheological characterization of a gel form of the porcine urinary bladder matrix. *Biomaterials*. 2008 Apr 1;29(11):1630-7.
21. Pridgen BC, Woon CY, Kim M, Thorfinn J, Lindsey D, Pham H, Chang J. Flexor tendon tissue engineering: acellularization of human flexor tendons with preservation of biomechanical properties and biocompatibility. *Tissue Engineering Part C: Methods*. 2011 Aug 1;17(8):819-28.
22. Zhang AY, Bates SJ, Morrow E, Pham H, Pham B, Chang J. Tissue-engineered intrasynovial tendons: Optimization of acellularization and seeding. *Journal of Rehabilitation Research & Development*. 2009 Apr 1;46(4).
23. Fish R, Danneman PJ, Brown M, Karas A, editors. *Anesthesia and analgesia in laboratory animals*. Academic press; 2011 Apr 28.
24. Skarda RT. Local and regional anesthesia in ruminants and swine. *Veterinary Clinics: Food Animal Practice*. 1996 Nov 1;12(3):579-626.
25. Barger AM, MacNeill AL, editors. *Clinical pathology and laboratory techniques for veterinary technicians*. John Wiley & Sons; 2015 Oct 12.
26. Farnebo S, Farnebo L, Kim M, Woon C, Pham H, Chang J. Optimized repopulation of tendon hydrogel: synergistic effects of growth factor combinations and adipose-derived stem cells. *Hand*. 2017 Jan;12(1):68-77.
27. Dean BJ, Snelling SJ, Dakin SG, Murphy RJ, Javaid MK, Carr AJ. Differences in glutamate receptors and inflammatory cell numbers are associated with the resolution of pain in human rotator cuff tendinopathy. *Arthritis research & therapy*. 2015 Dec;17(1):176.
28. Hsu C, Chang J. Clinical implications of growth factors in flexor tendon wound healing. *The Journal of hand surgery*. 2004 Jul 1;29(4):551-63.
29. Kobayashi M, Itoi E, Minagawa H, Miyakoshi N, Takahashi S, Tuoheti Y, Okada K, Shimada Y. Expression of growth factors in the early phase of supraspinatus tendon healing in rabbits. *Journal of shoulder and elbow surgery*. 2006 May 1;15(3):371-7.
30. Chen CH, Cao Y, Wu YF, Bais AJ, Gao JS, Tang JB. Tendon healing in vivo: gene expression and production of multiple growth factors in early tendon healing period. *The Journal of hand surgery*. 2008 Dec 1;33(10):1834-42.
31. Oryan A, Moshiri A. Recombinant fibroblast growth protein enhances healing ability of experimentally induced tendon injury in vivo. *Journal of tissue engineering and regenerative medicine*. 2014 Jun;8(6):421-31.
32. Fenwick SA, Hazleman BL, Riley GP. The vasculature and its role in the damaged and healing tendon. *Arthritis Research & Therapy*. 2002 Jun;4(4):252.
33. Zhang F, Liu H, Stile F, Lei MP, Pang Y, Oswald TM, Beck J, Dorsett-Martin W, Lineaweaver WC. Effect of vascular endothelial growth factor on rat Achilles tendon healing. *Plastic and reconstructive surgery*. 2003 Nov 1;112(6):1613-9.
34. Boyer MI, Watson JT, Lou J, Manske PR, Gelberman RH, Cai SR. Quantitative variation in vascular endothelial growth factor mRNA expression during early flexor tendon healing: an investigation in a canine model. *Journal of Orthopaedic Research*. 2001 Sep;19(5):869-72.
35. Petersen W, Unterhauser F, Pufe T, Zantop T, Südkamp NP, Weiler A. The angiogenic peptide vascular endothelial growth factor (VEGF) is expressed during the remodeling of free tendon grafts in sheep. *Archives of orthopaedic and trauma surgery*. 2003 May 1;123(4):168-74.
36. Lipman K, Wang C, Ting K, Soo C, Zheng Z. Tendinopathy: injury, repair,

- and current exploration. Drug design, development and therapy. 2018;12:591.
37. Thomopoulos S, Das R, Sakiyama-Elbert S, Silva MJ, Charlton N, Gelberman RH. bFGF and PDGF-BB for tendon repair: controlled release and biologic activity by tendon fibroblasts in vitro. *Annals of biomedical engineering*. 2010 Feb 1;38(2):225-34.
38. Schie HT, Bakker EM, Jonker AM, Weeren PV. Ultrasonographic tissue characterization of equine superficial digital flexor tendons by means of gray level statistics. *American journal of veterinary research*. 2000 Feb 1;61(2):210-9.
39. Schramme M, Hunter S, Campbell N, Blikslager A, Smith R. A surgical tendonitis model in horses: Technique, clinical, ultra-sonographic and histological characterisation. *Veterinary and Comparative Orthopaedics and Traumatology*. 2010;23(04):231-9.
40. Zandim BM, de Souza MV, Frassy LN, Vilória MI, Maia L, Fonseca CC, Valente FL, Moreira JD, Magalhães PC. Immunohistochemistry of factor VIII, histology and morphometry in equine tendon treated with platelet-rich plasma. *Brazilian Journal of Veterinary Medicine*. 2013 Jun 30;35(2):169-84.
41. Smith RK. Tendon and ligament injury. *Proc 54th Ann Conv Am Assoc Eq Pract*. 2008;54:475-501.
42. Sungur N, Uysal A, Koçer U, Karaaslan Ö, Gümüş M, Sökmensüer LK, Sökmensüer C. Prevention of tendon adhesions by the reconstruction of the tendon sheath with solvent dehydrated bovine pericard: An experimental study. *Journal of Trauma and Acute Care Surgery*. 2006 Dec 1;61(6):1467-72.
43. Mostafa MB, Al-Akraa AM, Khalil AH. Ultrasonographic assessment of superficial digital flexor tendon (SDFT) core lesion treated with platelet rich plasma (PRP) in donkeys (*Equus Asinus*). *Benha Veterinary Medical Journal*. 2015 Dec 1;29(2):274-82.
44. AL-Bayat, AH, Saleh SI, Al-Asadi RN, and Hussein SM (2011). *Harnessing of Mesenchymal Stem Cells for Treatment and Rehabilitation of Inducing Tendonitis in Equine Species*. Ph.D. thesis. College of Veterinary Medicine- University of Baghdad. -Iraq.
45. Mattoon JS, Nyland TG. *Small Animal Diagnostic Ultrasound-E-Book*. Elsevier Health Sciences; 2014 Dec 2.
46. Bosch G, Van Weeren PR, Barneveld AB, van Schie HT. Computerised analysis of standardised ultrasonographic images to monitor the repair of surgically created core lesions in equine superficial digital flexor tendons following treatment with intratendinous platelet rich plasma or placebo. *The Veterinary Journal*. 2011 Jan 1;187(1):92-8.
47. Zuffova K, Krisova S, Zert Z. Platelet rich plasma treatment of superficial digital flexor tendon lesions in racing Thoroughbreds. *Veterinarni Medicina*. 2013 Apr 1;58(4).