



Effect of Nandrolone Decanoate on Some Biochemical Markers When Used as Adjuvant Therapy for Healing of Facial Muscle Wound

Tamarah M. Al-Abdullah¹, Faehaa A. Al-Mashhadane*²

¹Master student, Department of Dental Basic Sciences, College of Dentistry, Mosul University / Iraq.

²Department of Dental Basic Sciences, College of Dentistry, Mosul University / Iraq.

Article information

Received: 25 April 2023

Accepted: 6 June 2023

Available online: 15 Sep. 2024

Keywords

Nandrolone-Decanoate (ND),
Masseter muscle,
C- reactive protein (CRP),
Lactate dehydrogenase (LDH),
Aspartate aminotransferase (GOT),
Alanine aminotransferase (GPT).

*Correspondence:

E-mail:

faehaaazher@uomosul.edu.iq

Abstract

Aims: to distinguish if the nanodrolone decanoate has any effect on the healing of facial muscular wounds which are one of the issues that dentists face, and it is a challenge to find a useful treatment for this condition. This study explores the idea that, when used in conjunction with surgical repair. The steroid Nandrolone-Decanoate, when injected locally to the masseter muscle, improves healing. **Materials and Methods:** The study comprised twenty-five healthy rabbits, were sorted into three equal groups at random. The animals were classified randomly into 3 groups (5 rabbits/group). Group I: (control negative/5 rabbits) the rabbits were not undergoing surgical procedure and not receive any treatment. Group II: (control positive/10 rabbits) the rabbits were undergoing surgical procedure and receive distilled water injection. Group IIA: contained 5 rabbits that were euthanized on the 3rd day of the surgical procedure. Group IIB: contained 5 rabbits that were euthanized on the 7th day of the surgical procedure. Group III: (treatment/10 rabbits) the rabbits were undergoing surgical procedure, and each rabbit, treated once daily with nanodrolone deconate (10 mg/kg) using Mantoux syringe via intramuscular injection from the first day of the surgical procedure to the euthanizing day. Group IIIA: contained 5 rabbits that were euthanized on the 3rd day of the surgical procedure. Group IIIB: contained 5 rabbits that were euthanized on the 7th day of the surgical procedure. **Results:** There are highly significant differences in the serum aspartate aminotransferase (GOT) and Alanine aminotransferase (GPT). The results demonstrate an increase (both enzymes) in the treatment group on the seventh day of the trial as compared to the control group and the 3rd day. There is a decrease in the LDH (lactate dehydrogenase) level in the 7th day of the treatment as compared with 3rd day of treatment group and with the control group. C –reactive protein (CRP) serum results show a highly significant decrease in its level in 7th day as compared to the 3rd day and the control group. **Conclusions:** Nanodrolone Decanoate may be used as an adjunctive therapy in the healing of intramuscular wounds.

تأثير ديكانوات الناندرولون على بعض العلامات البيوكيميائية عند استخدامه كعلاج مساعد لشفاء جرح عضلات الوجه

الملخص

الأهداف: تهدف الدراسة الى التمييز بين ما إذا كان ديكانوات النانودرولون له أي تأثير على التئام جروح عضلات الوجه التي تعد واحدة من المشكلات التي يواجهها أطباء الأسنان ، ومن الصعب العثور على علاج مفيد لهذه الحالة. تستكشف هذه الدراسة فكرة أنه عند استخدامها جنباً إلى جنب مع الإصلاح الجراحي. الستيرويد الناندرولون-ديكانوات ، عند حقنه محلياً في العضلات الماضغة ، يحسن الشفاء. **المواد وطرائق العمل:** ضمت الدراسة خمسة وعشرين أرنباً سليماً ، تم فرزها إلى ثلاث مجموعات متساوية عشوائياً. تم تصنيف الحيوانات بشكل عشوائي إلى 3 مجموعات (5 أرانب/مجموعة). المجموعة الأولى: (تحكم سلبي / 5 أرانب) لم تكن الأرانب تخضع لعملية جراحية ولم تتلق أي علاج. المجموعة الثانية: (مراقبة إيجابية / 10 أرانب) كانت الأرانب تخضع لعملية جراحية وتتلقى حقن الماء المقطر. المجموعة إيا: الواردة 5 الأرانب التي تم الموت الرحيم في اليوم 3 من العملية الجراحية. المجموعة الثانية: احتوت على 5 أرانب تم القتل الرحيم في اليوم 7 من العملية الجراحية. المجموعة الثالثة: (علاج/10 أرانب) كانت الأرانب تخضع لعملية جراحية ، وكل أرنب يعالج مرة واحدة يومياً باستخدام ديكانوات النانودرولون (10 مجم/كجم) باستخدام حقنة مانتو عن طريق الحقن العضلي من اليوم الأول من العملية الجراحية إلى يوم القتل الرحيم. المجموعة الثانية: تحتوي على 5 أرانب تم التخلص منها في اليوم 3 من العملية الجراحية. المجموعة الثانية: احتوت على 5 أرانب تم قتلها رحيماً في اليوم 7 من العملية الجراحية. النتائج: هناك اختلافات كبيرة للغاية في مصل الأسبارتات أمينوترانسفيراز (غوت) والأنين أمينوترانسفيراز (غت). النتائج: أظهرت النتائج زيادة (كلا الإنزيمين) في مجموعة العلاج في اليوم السابع من التجربة مقارنة بالمجموعة الضابطة واليوم 3. هناك انخفاض في مستوى لد (اللاكتات ديهيدروجينيز) في اليوم 7 من العلاج بالمقارنة مع 3 يوم من مجموعة العلاج ومع المجموعة الضابطة. بروتين سي التفاعلي (كرب) نتائج المصل تظهر انخفاضاً كبيراً للغاية في مستواه في اليوم 7 بالمقارنة مع اليوم 3 والمجموعة الضابطة. **الاستنتاجات:** يمكن استخدام ديكانوات النانودرولون كعلاج مساعد في التئام الجروح العضلية.

DOI: 10.33899/RDENJ.2023.140735.1209, © Authors, 2024, College of Dentistry, University of Mosul

This is an open-access article under the CC BY 4.0 license (<http://creativecommons.org/licenses/by/4.0/>)

INTRODUCTION

Synthetic testosterone derivatives known as anabolic androgenic steroids (AASs) are created to increase anabolic activity while reducing androgenic side effects. They have garnered a great deal of notoriety in the last 50 years ⁽¹⁻³⁾.

There are numerous therapeutic uses for AASs. AASs' anabolic effects could be useful in the management of muscle loss caused by severe burns, as well as a number of additional long-term diseases such as malignancy, kidney damage, liver cirrhosis, lung disease, and muscle dystrophy ⁽⁴⁻⁷⁾.

There is mounting evidence that AASs have muscle mass and strength are increased. It was recently suggested that AASs have anabolic effects be studied further in muscle could improve postoperative healing and recovery after surgery including muscle injuries. Although the exact role of their administration in the mentioned processes is still inconclusive. Skeletal muscle has a well-known ability to self-repair, despite the fact that the severity of the injury may cause delayed or incomplete healing as a result of fibrosis. Preclinical research has demonstrated a link between testosterone and muscle regeneration processes. Unfortunately, few researches have directly examined. The impact of the AASs on the growth of muscles is debatable. with contradictory evidence ⁽⁸⁾.

Ferry and colleagues investigated the impact of Nanodrolone-Deconate (ND) on the soleus and extensor digitorum longus muscles following myotoxic injection ⁽⁹⁾, and additional

preclinical studies discovered that administering ND increased Muscle regeneration was permitted based on the number and shape of myofibers found in those muscles ⁽¹⁰⁻¹²⁾.

AST (GOT) and ALT(GPT) values are enzymes mainly found in liver tissues, red blood cells, muscle tissue and heart muscle and other organs, any damage in these tissues results in increase in the serum level of these two enzymes so they are particularly useful in the detection of liver disease ^(11, 13). Lactate-dehydrogenase is an enzyme that can be found in almost every human tissue. organ destruction and diseases cause elevation in the serum level of LDH which occurs due to significant cell death that results in loss of cytoplasm ^(14,15). C-reactive protein (CRP) is one of the liver enzymes that is produced in an acute –phase form, activated by TNF, IL-6, and IL-1. CRP level increase in response to inflammation. This can be proved by measuring the serum level of CRP which is increased in the 4 to 6 hours following inflammation, this level multiplying by two in 8 hours till it reaches its peak level in 36-50 hours ⁽¹⁶⁾.

Preclinical data may differ depending on the differential regeneration response to various forms of muscle injury, the dose and the duration of androgen treatment, as well as the outcome variables. No human research has examined the function of androgens in fostering muscle regeneration as of yet. Despite the fact that there is ongoing study on this subject, the most recent studies do not provide convincing arguments for or against the AASs uses ⁽⁸⁾.

MATERIALS AND METHODS

The experiment for this study was carried out with consent from the Dentistry College / Mosul University: approval of the Study Ethics Panel and the Dept. of Dental-Basic Science Educational Committee. NO. Uo.M-Dent: A.82/22.

Animals

The study comprised twenty local male rabbits weighing 1-1.5 kg and aged between 11-12 months. Individual animals were kept in special cages in specific circumstances (temperature of around 20-25°C with a light-dark cycle). 12:12 hr.), with left access to water and food ⁽¹⁷⁾.

Surgical processing

An injectable dosage of xylazine hydrochloride (5mg/kg) and ketamine hydrochloride (50 mg/kg) was used to anesthetize the animals ⁽¹⁸⁾. The anesthetized animal was placed on the surgical board on its ventral side, and the operative region (cheek) before being cleaned with tap water and sterilized with povidone-iodine solutions. Utilizing forceps and a surgical blade no:15 ⁽¹⁹⁾, a 1 cm long incision in the skin and deep into the masseter muscle was carefully produced. Following that, the wounds were sutured with an absorbable suture to allow them to heal by primary purpose. The animals received both antibiotics and analgesics in the first day only.

The rabbits were sorted into three equal groups at random. Group I consist of five rabbits control negative that receive nothing. Group II: Control positive group, (10 rabbits) were

subjected to a surgical procedure and injected with distilled water without receiving any treatment. Group III (10 rabbits): treatment group, rabbits were subjected to a surgical procedure and were treated once daily with Nanodrolone-Deconate (10 mg/kg) using Mantoux syringe via intramuscular injection from the first day of the surgical procedure to the euthanizing day. Five animals of each group were euthanized on the 3rd and 7th day were euthanized. Blood was collected from each rabbit The serum was separated for biochemical parameter analysis. using centrifugation and stored at (-20C°) until analysis by using BIOLABO kit for measuring AST, ALT- colorimetric method and BILLABO kit for measuring LDH SFBC modified method and CRP detection kit (SIEMENS).

RESULTS

Clinical observations

The animals were under daily observation of veterinary doctor. During the trial period, no mortality toxicity, aberrant signs in their activity, any behavioural pattern or other clinical findings were documented in any of the groups. Except local changes in the wound area as compared with the control group.

Biochemical finding

There is a highly significant difference of GOT, GPT, LDH and CRP. The results demonstrate a significant increase in GOT and GPT in the group treated with Nanodrolone-Deconate group on the

seventh day of the trial as compared to the control group and the 3rd day of treatment (Table 1 & 2), (Figure 1 & 2). In addition, there is a decrease in the LDH level in the 7th day of the treatment as compared with 3rd day of treatment and the control groups (Table 3) (Figure 3). CRP in serum results shows a highly significant decrease in the level in 7th day group as compared to the 3rd day and the control groups (Table 4), (Figure 4).

Table 1: Comparison between all groups in GOT level.

ANOVA						
	Squares	Df.	Square	F	sig.	
	Sum		Mean			
GOT	Between-	10492.382	4	2623.096	17.183	0.000**
	Groups					
	Within	3053.096	20	152.655		
	Groups					
	Total	13545.478	24			

** Highly Significant at P-value ≤ 0.01

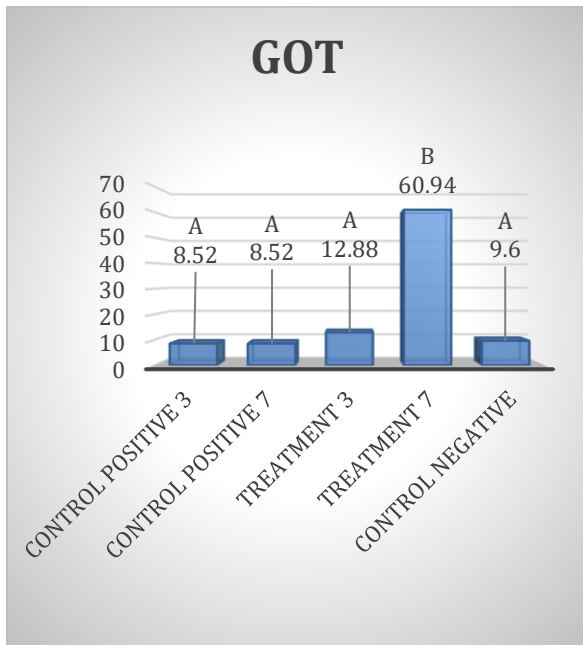


Figure 1: level of GOT in different groups.

Table 2: Comparison between all groups in GPT level.

ANOVA						
	Squares	Df.	Square	F	sig.	
	Sum		Mean			
GPT	Between-	7653.761	4	1913.440	2.640	0.044*
	Groups					
	Within	14495.671	20	724.784		
	Groups					
	Total	22149.432	24			

* Significant at P-value ≤ 0.05

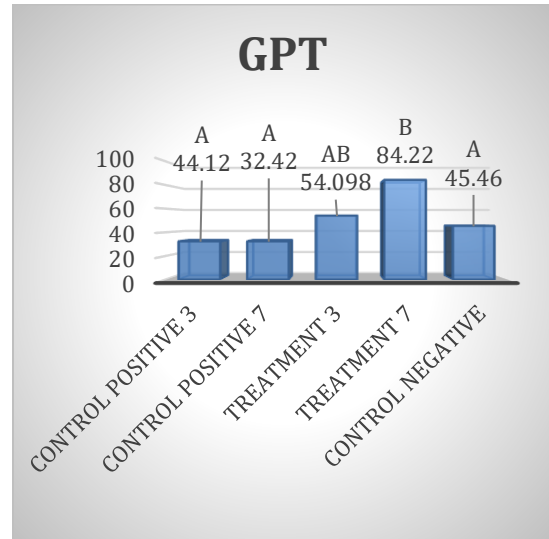


Figure 2: level of GPT in different groups.

Table 3: Comparison between all groups in LDH level.

ANOVA						
	Squares	Sum	Df.	Square	F	sig.
				Mean		
LDH	Between-	147592.882	4	36898.221	24.918	0.000**
	Groups					
	Within	29615.864	20	1480.793		
	Groups					
	Total	177208.746	24			

** Highly Significant at P-value ≤ 0.01.

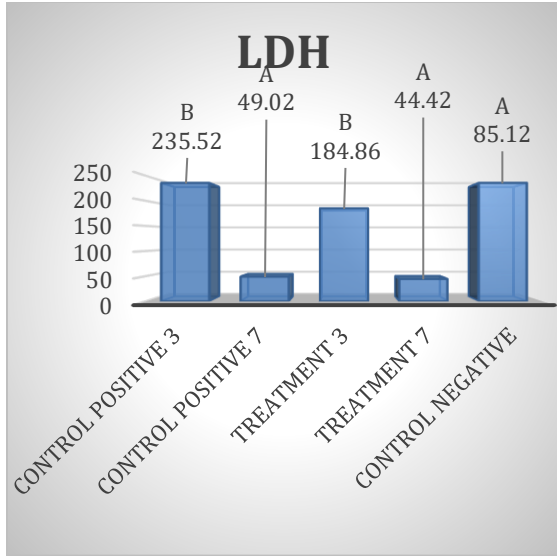


Figure 3: level of LDH in different groups.
Table 4: Comparison between all groups in CRP.

ANOVA						
		Squares	Df.	Square	F.	sig.
		Sum		Mean		
CRP	Between Groups	18.445	4	4.611	16.898	0.000**
	Within Groups	5.458	20	0.273		
	Total	23.902	24			

** Highly Significant at P-value ≤ 0.01 .

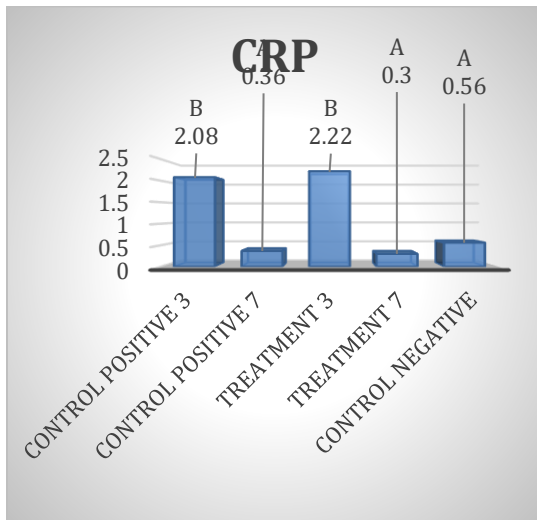


Figure 4: level of CRP in different groups.

DISCUSSION

Although the effects of anabolic steroids on skeletal muscle have been well documented, little attention has been paid to the acceleration of muscle regeneration following injury. The goal of this research was to find out if Nandrolone-Decanoate local injection improves masseter muscle regeneration and healing after incisional wound.

The muscle regeneration induced by exogenous anabolic steroids in the animal models have been examined after several types of muscle injury. In a previous study, the exogenous use of the administration of Nandrolone Decanoate to non-castrated rats proved advantageous for the regeneration of gastrocnemius muscle following crush injury. In intact rats, anabolic steroid use increases soleus muscle mass after muscular damage caused by snake venom (10,13 & 20).

Exogenous Nandrolone-Decanoate adjustment of the muscle regeneration is in need of additional search. Moreover, Nandrolone-Decanoate has also been implicated in the effective regeneration of mouse TA (tibialis anterior) muscle following muscle graft surgery (17). Although the Anabolic steroid regulation of muscle regeneration after injury has been broadly examine (20 & 21), their impact on these regenerative processes has not been fully recognized.

After injury, the early skeletal muscle regenerative response is comparable to wound repair in that it requires synchronized inflammation control, extracellular matrix renovation, and myofiber expansion (22 & 23).

Anabolic steroids have also an improved control the activity of immunological. All of these cells are required for tissue regeneration, fibroblasts, and myogenic precursor cells. Anabolic steroids also have a greater capacity to influence the activity of immunological, a fibroblast and the myogenic cell precursors, all of which are required over the repair of tissues^(17-19,24 & 25).

During 5, 14, and 42 days, Nandrolone-Decanoate treatment alone boosted muscle protein expression. Nandrolone-Decanoate enhanced protein expression in injured muscle three-fold over the control after 14 days of healing. Nandrolone-Decanoate significantly increased protein expression in damaged muscle compared to Nandrolone-Decanoate alone. Androgen receptor Induction of target gene recording may be ND is important in accelerating muscle mass expansion during injury healing⁽²⁶⁾. ND (nanodrolone decanoate) has been implicated in numerous studies. functional and morphological changes in the liver and kidney, resulting in increased blood levels of creatinine levels, urea, alanine transaminase, and the enzyme aspartate transaminase^(27 & 28).

These findings support Hough's assertion that elevated levels of AST, ALT, and lactic dehydrogenase are prevalent among steroid-using athletes⁽²⁹⁾.

According to Vieira *et al.*, ND treatment raises serum levels of AST, ALT, and alkaline phosphatase in rats in a dose-dependent manner. Our findings suggest that sub chronic ND therapy, particularly at higher-than-clinical

doses, may be harmful to the liver, resulting in incipient fibrosis⁽³⁰⁾.

Our study found a mild increase in LDH levels on the third day and a significant decrease on the seventh day, indicating that there is minimal cellular damage. Lactate dehydrogenase (LDH) is a cytoplasmic enzyme that is found in all cells and is rapidly released into the cell culture supernatant when the plasma membrane is damaged, making LDH an important feature of apoptotic cells. Necrosis, as well as other types of cellular damage⁽³¹⁾.

Finally, the C-reactive protein test shows a highly significant difference between the groups, these differences include an increase in the level of the CRP in the 3rd day as compared with the control positive group which is partly agreed with Grace FM and Davies B who say C reactive-protein concentrations were considerably (p0.05) greater in bodybuilders who used AAS⁽³²⁾ and disagree because our result shows a drop in the level of CRP in the 7th day.

The findings of the current study showed accelerating effect of ND on healing process of muscle injury within few days. There is evidence that Nandrolone-Decanoate-induced myofiber development Early in the recovery process, a muscle is injured. There are some drawbacks to this study. The tiny sample size and short duration of the study. However, we believe that the findings of local anabolic steroid use on masseter muscle healing are definitely useful. More research is needed to confirm these findings.

CONCLUSIONS

The local injection of Nandrolone in the injured masseter muscle of rabbits was capable to alter the healing direction. Complementary pharmaceutical therapies may aid in the successful recovery and regeneration of face muscle after surgery.

Conflict of Interest

The authors declare that there are no conflicts of interest regarding the publication and/or funding of this manuscript.

REFERENCES

1. Haupt HA, Rovere GD: Anabolic steroids: A review of the literature. *Am J Sports Med* 1984; 12:469-484.
2. Siperstein G, Romano N, Iskenderoglu G, Roman A, Fowler FJ Jr, Drascher M: The American Public's Perception of Illegal Steroid Use: A National Survey, 2013, Boston, MA: University of Massachusetts, 2013.
3. McDuff D, Stull T, Castaldelli-Maia JM, Hitchcock ME, Hainline B, Reardon CL: Recreational and ergogenic substance use and substance use disorders in elite athletes: A narrative review. *Br J Sports Med* 2019; 53:754-760.
4. Basaria S, Wahlstrom JT, Dobs AS: Anabolic-androgenic steroid therapy in the treatment of chronic diseases. *J Clin Endocrinol Metab* 2001; 86:5108-5117.
5. Wischmeyer PE, Suman OE, Kozar R, Wolf SE, Molinger J, Pastva AM: Role of anabolic testosterone agents and structured exercise to promote recovery in ICU survivors. *Curr Opin Crit Care* 2020;26: 508-515.
6. Giangregorio L, McCartney N: Bone loss and muscle atrophy in spinal cord injury: Epidemiology, fracture prediction, and rehabilitation strategies. *J Spinal Cord Med* 2006; 29:489-500.
7. Gorgey AS, Khalil RE, Gill R, et al: Effects of testosterone and evoked resistance exercise after spinal cord injury (TEREX-SCI): Study protocol for a randomised controlled trial. *BMJ open* 2017;7: e014125.
8. Weber AE, Gallo MC, Bolia IK, Cleary EJ, Schroeder TE, Rick Hatch GF 3rd. Anabolic Androgenic Steroids in Orthopaedic Surgery: Current Concepts and Clinical Applications. *J Am Acad Orthop Surg Glob Res Rev.* 2022 Jan 4;6(1): e21.00156. doi: 10.5435/JAAOSGlobal-D-21-00156. PMID: 34982051; PMCID: PMC8735789.
9. Ferry A, Noirez P, Page CL, Salah IB, Daegelen D, Rieu M: Effects of anabolic/androgenic steroids on regenerating skeletal muscles in the rat. *Acta Physiol Scand* 1999; 166:105-110.
10. Beiner JM, Jokl P, Cholewicki J, Panjabi MM: The effect of anabolic steroids and corticosteroids on healing of muscle contusion injury. *Am J Sports Med* 1999; 27:2-9.
11. Huang XJ, Choi YK, Im HS, Yarimaga O, Yoon E, Kim HS. Aspartate Aminotransferase (AST/GOT) and Alanine Aminotransferase (ALT/GPT) Detection Techniques. *Sensors*

- (Basel). 2006 Jul 31;6(7):756–82. PMID: PMC3894536).
12. Serra C, Tangherlini F, Rudy S, et al: Testosterone improves the regeneration of old and young mouse skeletal muscle. *J Gerontol a Biol Sci Med Sci* 2013; 68:17-26.
 13. Ferry A, Vignaud A, Noirez P, Bertucci W. Respective effects of anabolic/androgenic steroids and physical exercise on isometric contractile properties of regenerating skeletal muscles in the rat. *Arch Physiol Biochem* 108: 257–261, 2000.
 14. Farhana A, Lappin SL. Biochemistry, Lactate Dehydrogenase. [Updated 2022 May 8]. In: StatPearls [Internet]. Treasure Island (FL): StatPearls Publishing; 2022 Jan-.)))
 15. Feng Y, Xiong Y, Qiao T, Li X, Jia L, Han Y. Lactate dehydrogenase A: A key player in carcinogenesis and potential target in cancer therapy. *Cancer Med*. 2018 Dec;7(12):6124-6136. [[PMC free article](#)] [[PubMed](#)] [[Ref list](#)].
 16. Douglas JB, Silverman DT, Weinstein SJ, Graubard BI, Pollak MN, Tao Y, Virtamo J, Albanes D, Stolzenberg-Solomon RZ. Serum C-reactive protein and risk of pancreatic cancer in two nested, case-control studies. *Cancer Epidemiol Biomarkers Prev*. 2011 Feb;20(2):359-69. doi: 10.1158/1055-9965.EPI-10-1024. Epub 2010 Dec 20. PMID: 21173171; PMID: PMC3495286.
 17. Grounds MD. Phagocytosis of necrotic muscle in muscle isografts is influenced by the strain, age, and sex of host mice. *J Pathol* 153: 71– 82, 1987.
 18. Horiguchi T, Shibata MA, Ito Y, Eid NA, Abe M, Otsuki Y. Macrophage apoptosis in rat skeletal muscle treated with bupivacaine hydrochloride: possible role of MCP-1. *Muscle Nerve* 26: 79 – 8.
 19. Schneider CP, Schwacha MG, Samy TS, Bland KI, Chaudry IH. Androgen-mediated modulation of macrophage function after traumahemorrhage: central role of 5 alpha-dihydrotestosterone. *J Appl Physiol* 95: 104 –112, 2003.
 20. Yan Z, Choi S, Liu X, Zhang M, Schageman JJ, Lee SY, Hart R, Lin L, Thurmond FA, Williams RS. Highly coordinated gene regulation in mouse skeletal muscle regeneration. *J Biol Chem* 278: 8826 – 8836, 2003.
 21. Axell AM, MacLean HE, Plant DR, Harcourt LJ, Davis JA, Jimenez M, Handelsman DJ, Lynch GS, Zajac JD. Continuous testosterone administration prevents skeletal muscle atrophy and enhances resistance to fatigue in orchidectomized male mice. *Am J Physiol Endocrinol Metab* 291: E506 –E516, 2006.
 22. Ambrosio F, Kadi F, Lexell J, Fitzgerald GK, Boninger ML, Huard J. The effect of muscle loading on skeletal muscle regenerative potential: an update of current research findings relating to aging and neuromuscular pathology. *Am J Phys Med Rehabil* 88: 145–155, 2009.
 23. Huard J, Li Y, Fu FH. Muscle injuries and repair: current trends in research. *J Bone Joint Surg Am* 84-A: 822– 832, 2002.
 24. Friedl R, Brunner M, Moeslinger T, Spieckermann PG. Testosterone inhibits expression of inducible nitric oxide synthase in

- murine macrophages. *Life Sci* 68: 417– 429, 2000.
25. Zhang J, Pugh TD, Stebler B, Ershler WB, Keller ET. Orchiectomy increases bone marrow interleukin-6 levels in mice. *Calcif Tissue Int* 62: 219 –226, 1998.
26. Alessi DR, James SR, Downes CP, Holmes AB, Gaffney PR, Reese CB, Cohen P. Characterization of a 3-phosphoinositide-dependent protein kinase which phosphorylates and activates protein kinase Balpha. *Curr Biol* 7: 261–269, 1997.
27. Almaiman A.A., Almaiman S.H., Elagamy E.I., Al Wutayd O., Almarzuqi M., Alzunaidi R., Alhatlani S., Eid E.E. Side effects of anabolicsteroidsused by athletesatUnaizahGyms, Saudi Arabia: A pilotstudy. *J. Sports MedPhys. Fit.* 2019; 59:489–495. doi: 10.23736/S0022-4707.18.08366-4. [[PubMed](#)] [[CrossRef](#)] [[Google Scholar](#)].
28. Bertozzi G., Sessa F., Maglietta F., Cipolloni L., Salerno M., Fiore C., Fortarezza P., Ricci P., Turillazzi E., Pomara C. Immunodeficiency as a side effect of anabolic androgenic steroid abuse: A case of necrotizing myofasciitis. *Forensic. Sci. Med. Pathol.* 2019;15:616–621. doi: 10.1007/s12024-019-00144-z. [[PubMed](#)] [[CrossRef](#)] [[Google Scholar](#)] [[Ref list](#)].
29. Hough DO. Anabolic steroids and ergogenic aids. *Am Fam Physician.* 1990;41(4):1157–64. [[PubMed](#)] [[Google Scholar](#)].
30. Vieira RP, Franca RF, Damaceno-Rodrigues NR, Dolhnikoff M, Caldini EG, Carvalho CR, *et al.* Dose-dependent hepatic response to subchronic administration of nandrolone decanoate. *Med Sci Sports Exerc.* 2008;40(5):842–7. [[PubMed](#)] [[Google Scholar](#)].
31. Kumar P, Nagarajan A, Uchil PD. Analysis of Cell Viability by the Lactate Dehydrogenase Assay. *Cold Spring Harb Protoc.* 2018 Jun 1;2018(6). doi: 10.1101/pdb. Prot 095497. PMID: 29858337.
32. Grace FM, Davies B. Raised concentrations of C reactive protein in anabolic steroid using bodybuilders. *Br J Sports Med.* 2004 Feb;38(1):97-8. doi: 10.1136/bjism.2003.005991. PMID: 14751958; PMCID: PMC1724758.