



Research Article

Histopathological and biochemical assessments of Co-Q10 in mitigating submandibular salivary gland toxicity caused by Trastuzumab and Doxorubicin in rat model

Saif Aldeen Husam Alkakaee*¹, Jawnaa Khalid Mammdoh²

1 Ministry of Health - Ninevah health director – Al-Hamdania hospital, Mosul / Iraq

2 Department of Basic Dental Sciences/College of Dentistry/ University of Mosul/ Iraq

* Corresponding author: Saif.21dep27@student.uomosul.edu.iq

Abstract: The current study aimed to investigate the role of Co-Q10 in reducing the salivary gland toxicity caused by Trastuzumab and Doxorubicin. **Materials and methods** employed to study histopathological measurements by using H&E stains, and serological tests composed of T-AOC and MDA, in addition to BW. for this purpose, 16 white albino rats were employed, the experiment performed over 20 days, and rats divided into 4 groups: **G1** in which rats received pure corn oil orally, daily for 20 days. **G2** in which rats received TRZ+DOX, single dose of both drugs. **G3** in rats received Co-Q10 orally and then TRZ+DOX, a single dose of both drugs. And **G4**, in which rats received a single dose of both drugs and then Co-Q10 orally to the end of the experiment. **Results:** showed that the group in which rats received TRZ+DOX, the histopathological examination revealed many changes comparing with control (normal group), and there was increased serum level of MDA with slight increase in the serum level of T-AOC. In contrast, a vast benefit had been obtained from Co-Q10 as protection except for BW which still declined in all groups. The necrosis and degeneration of salivary gland cells and inflammatory cell infiltration were all found to be reduced in groups where rats received Co-Q10, however, the benefit was greater in the group that received Co-Q10 before TRZ+DOX, while circulatory disturbances and cell adaptation were found to get less benefit from Co-Q10. Total anti-oxidant capacity showed higher serum level in groups received Co-Q10, on the other hand, the serum level of MDA was lower in groups administered Co-Q10. **Conclusion:** Generally, our results concluded greater benefits from Co-Q10 when administered before TRZ+DOX.

Keywords: Co-Q10, Doxorubicin, MDA, Submandibular salivary gland toxicity, Trastuzumab, T-AOC.

Received: 28 April 2023

Revised: 28 May 2023

Accepted: 06 June 2023

Published: 1 March 2025



Copyright: © 2025 by the authors. This article is an open-access article distributed under the terms and conditions of the Creative Commons Attribution (CC BY 4.0) license (<https://creativecommons.org/licenses/by/4.0/>).

Citation: Alkakaee SH and MammdohJ Kh. Histopathological and biochemical assessments of Co-Q10 in mitigating submandibular salivary gland toxicity caused by Trastuzumab and Doxorubicin in rat model. Al-Rafidain Dent J. 2025;25(1):62-79



[10.33899/RDENJ.2023.140012.1206](https://doi.org/10.33899/RDENJ.2023.140012.1206)

INTRODUCTION

Cancer is a common disease that affects people, There are about 200 different types of cancers, ranging between solid tumors and hematological⁽¹⁾. Even though cancer is a complicated disease, its management is more complicated. The procedure involves a lot of disasters. Recently, much attention has been paid to reducing side effects and increasing long-lasting efficacy in cancer therapy and biological agents were a part of this aim⁽²⁾. Unfortunately, the improvement in the effectiveness of cancer therapy and improving patients' lifestyle and life span are associated with more frequent organ complications, which are related to side effects of chemotherapy⁽³⁾. The high possibility of oral complications of chemotherapy and/or radiotherapy for oral cancers is an additional challenge for dentists and oncologists⁽⁴⁾.

Despite the significant development of methods of cancer healing during the past decades, however, CHT remains the main method for cancer treatment. On the other hand, Multidrug resistance is responsible for over 90% of deaths in cancer patients receiving traditional chemotherapeutics or novel targeted drugs⁽⁵⁾.

Anti-cancer drug combinations provide patients with a good opportunity to get maximum benefits from therapy while reducing or preventing recurrence, resistance, and toxic effects, with the assurance of a better quality of life⁽⁶⁾. The rapidly expanding knowledge about the roles of the immune system in cancer has enabled the development of therapies targeted to specific cancerous tissues⁽⁷⁾.

Trastuzumab (Trz) is one of the monoclonal antibodies used as a standard treatment for breast cancer, metastatic gastric cancer, and gastro-esophageal junction cancers overexpressing the human epidermal growth factor receptor 2 (HER2)⁽⁸⁾. Trastuzumab is a HER2-directed antibody and DNA topoisomerase I inhibitor conjugate used for the treatment of numerous HER2-expressing cancers⁽⁹⁾.

Trastuzumab causes many undesirable adverse effects including: nausea, fatigue, vomiting, alopecia, constipation, decreased appetite, anemia, neutropenia, diarrhea, leukopenia, cough, thrombocytopenia, cardiotoxicity and hepatotoxicity⁽¹⁰⁾, however, oral side effects are also recorded, these include stomatitis, lip swelling, and decreased salivary secretion (dry mouth)⁽¹¹⁾. Doxorubicin (Dox) is an anthracycline anti-cancer drug. It is widely used as a first-line anti-cancer agent and is usually used in combination with other agents for the treatment of a variety of cancers, including breast and lung cancers, acute lymphocytic leukemia, and lymphomas. Dox. acts by producing free radicals that can induce membrane lipid peroxidation, scission of DNA strand, and direct oxidation of purine or pyrimidine bases, thiols, and amines⁽¹²⁾. However, its clinical application is limited because of a lack of specificity for tumors and its severe side effects, such as myelosuppression, nephrotoxicity, dose-dependent

cardiotoxicity, nausea, and vomiting. and oral side effects involving mucosal ulcerations in the mouth and throat, lip swelling, and xerostomia⁽¹³⁾.

Many approaches have been trialed to mitigate the side effects of anti-cancer drugs; among these trials are scheduling of doses, administration of protectant antioxidants, and using alternative drugs⁽¹⁴⁾. We chose the Co-Q10 (ubiquinone) as a protectant to minimize the toxicity of TRZ+DOX. Our goal was to study whether the administration of Co-Q10 in rats receiving TRZ and DOX can reduce salivary gland toxicity caused by TRZ and DOX or not

MATERIALS AND METHODS

Experimental animals

Sixteen healthy adult, male, white albino rats were separated in the animal house, they weighed from 270g - 388g. The rats are kept according to the standards of the animal house regarding room temperature $23\pm 2^{\circ}\text{C}$, light 12 h light/12 h dark, humidity $55\% \pm 10\%$, diet – commercial feed, water drink – tap water and medical care by staff of animal house and veterinarian⁽¹⁵⁾.

Study design

The rats were divided randomly into four groups, each group consisting of four rats. The study was done over 20 days, and the drugs were given in four patterns, as follows:

1. First group - G1(control): rats received pure corn oil only, the dose was 1ml/kg from first day of the experiment to the end;(day1-day20).
2. Second group – G2 rats received pure corn oil for 20 days, 1ml/kg orally daily, and were administered Trz. 10mg/kg single dose intraperitoneal (I.P.) + Dox. 10 mg/kg single dose I.P.) at the 10th day of experiment;(single dose)
3. Third group – G3 (protected group): rats received Co-Q10 orally 10mg/kg daily from the first day to the 10th day of experiment; at the 10th day, rats were administered (Trz. 10 mg/kg single dose I.P. + Dox. 10 mg/kg single dose I.P. Then administered pure corn oil 1ml/kg orally from day10 - day20 of experiment .
4. Fourth group – G4: rats received no treatment from day1 – day10 of experiment, at 10th day; they were administered (Trz. 10 mg/kg single dose I.P. + Dox. 10 mg/kg single dose I.P. at 10th day. Then they were administered Co-Q10, 10mg/kg daily orally from day 10 to day 20 of the experiment.

Body weight

All rats were weighed at the start of the experiment (at day 0), at the 10th day, and at the end of the experiment (20th day).

Blood sampling for biochemical examinations

After the end of the experimental period, rats were euthanized by ether, and after hemodynamic monitoring, blood samples were collected directly from the retro-orbital venous plexus. All blood samples were kept for 30 min. at room temperature. and then centrifuged for 20 min. at 3000 RPM and serum separated within Eppendorf tubes and stored at (-20 °C) to be ready for investigations of T-AOC and MDA⁽¹⁶⁾.

Histological examination:

Specimens of submandibular salivary glands of rats were prepared and stained with hematoxylin and eosin stains, to be examined after then by light microscope to measure the histopathological changes of submandibular salivary gland⁽¹⁷⁾.

Statistical analysis

Kruskal-Wallis Test, ANOVA test, The Duncan Test and Post-Hoc-Test were used for analyses of data of our study at level of $p \leq 0.05$ value and for comparison between groups.

RESULTS**Rats' weights**

Drugs that were used in the experiment had affected the weight of animals in general. All treated groups that received TRZ+DOX with and without protection (Co-Q10) were exerted and showed declining body weight.

The results of the assessment of body weights of rats showed that there were negligible changes in the weights among different groups at the 10th day interval at ($p \leq 0.05$), in comparison with the basal line weights at day zero. However, there was a significant decrease in the mean of body weights of rats in group-4 in which rats received TRZ+DOX with Co_Q10, at ($p \leq 0.05$) in the 20th day as in table1and figure1.

Table: (1): Comparison among groups in the mean of BW at day (0,10 and 20)

ANOVA for Rat Weight in Grams in Day0, Day10, and Day20				
Day0	Mean	Mean Square	F	Sig.
	G1 326.500	Between Gr 842.896	0.105	0.956
	G2 331.500			
	G3 337.750			
	G4 328.750			
		Within Gro: 710.229		
No Significant difference between four groups in day0				
Day10	Mean	Mean Square	F	Sig.
	G1 313.000	Between Gr 842.896	1.187	0.356
	G2 319.750			
	G3 344.000			
	G4 314.000			
		Within Gro: 710.229		
No Significant difference between the four groups on day 10				
Day20	Mean	Mean Square	F	Sig.
	G1 310.250	Between Gr 4439.896	2.179	0.043*
	G2 265.500			
	G3 245.750			
	G4 234.750			
		Within Gro: 2037.438		

* There is a Significant difference at $P \leq 0.05$ between the four groups on day 20

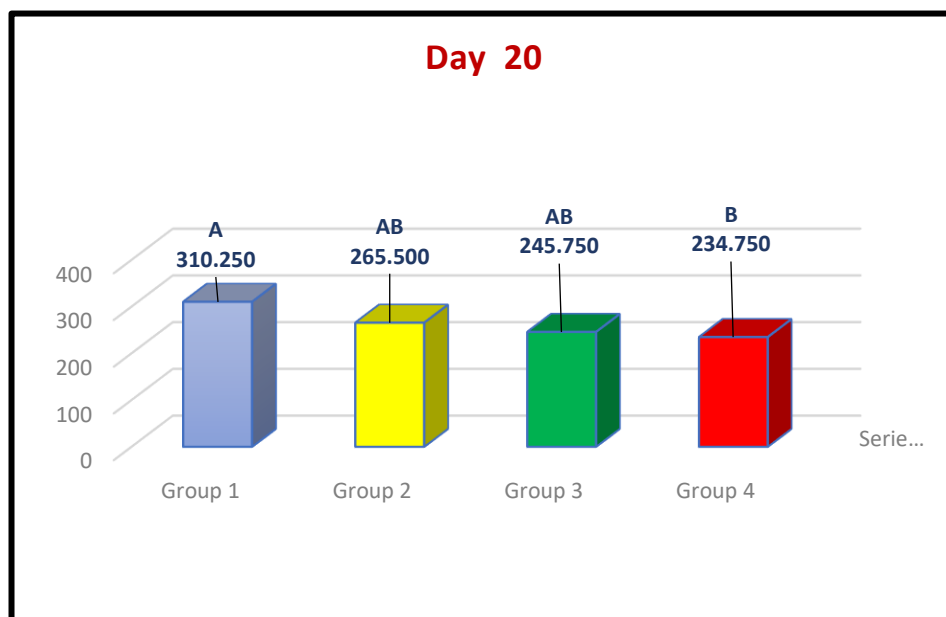


Figure: (1) differences in the mean of body weight among groups at Day 20

Histopathological examination:

Specimens of animals' tissues (submandibular salivary glands-SMG) were prepared and examined for searching for pathological and abnormal findings, and H&E stains were used for this purpose. SMG in group 2 showed necrosis of the granular convoluted tubules cells and seromucous acini cells, edema surrounding striated ducts, and congestion of blood vessels. Degeneration of the cells lining granular convoluted tubules cells, seromucous acini cells, and striated ducts had been found. Infiltration of inflammatory cells and congestion of blood vessels with increased fibrous connective tissue surrounding striated ducts were also seen, and severe vacuolar degeneration was well-defined in the figure (2-D). The photomicrographic examination of the SMG tissue of the groups that received Co-Q10 revealed intact seromucous acini, granular convoluted tubules, and striated ducts with congestion of blood vessels. Hyperplasia and mild degeneration of the cells lining seromucous acini had been found. Other findings like degeneration and necrosis of the cells lining granular convoluted tubules and striated ducts were also found, figure 2,3 and 4.

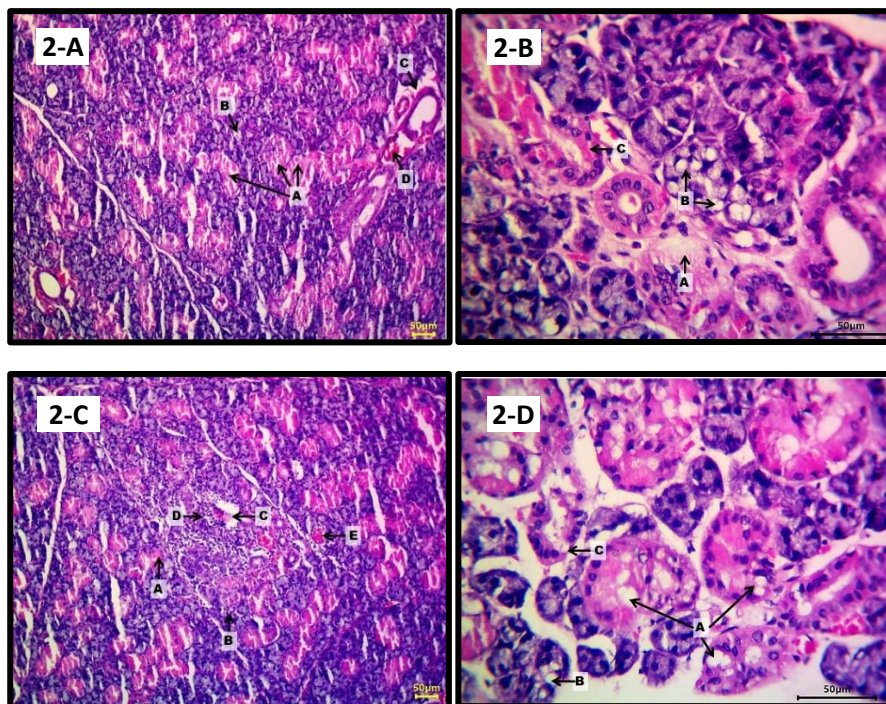


Figure: (2) 2-A photomicrograph of rat submandibular salivary gland of the G2 showing necrosis of the granular convoluted tubules cells (A) and seromucous acini cells (B), edema surrounding striated ducts (C) and congestion of blood vessels (D). 2-B necrosis and degeneration of the cells lining granular convoluted tubules cells (A), seromucous acini cells (B) and striated ducts (C). 2-C necrosis and degeneration of the cells lining granular convoluted tubules cells (A), seromucous acini cells (B), striated ducts (C), infiltration of inflammatory cells (D) and congestion of blood vessels (E). 2-D severe vacuolar degeneration and necrosis of the cells lining granular convoluted tubules cells (A), seromucous acini cells (B) and striated ducts (C).

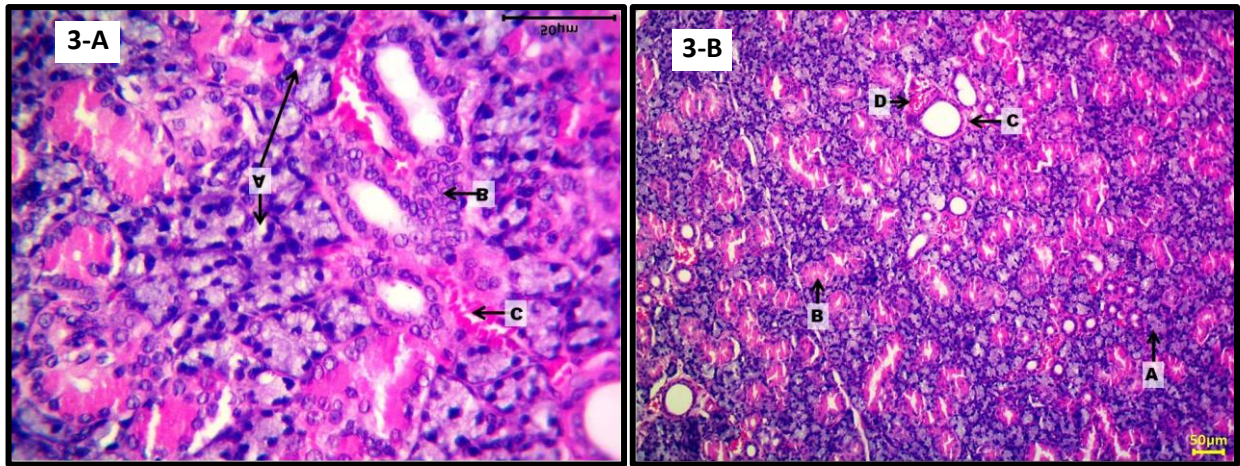


Figure:(3) 3-A photomicrograph of rat SMG of the G3 (protected) which received Co-Q10 then Trz+Doxo showing intact seromucous acini (A), granular convoluted tubules (B) and striated ducts (C) with congestion of blood vessels (D). 3-B showing mild degeneration of the cells lining seromucous acini (A), hyperplasia of the cells lining striated ducts (B) and congestion of blood vessels (C).

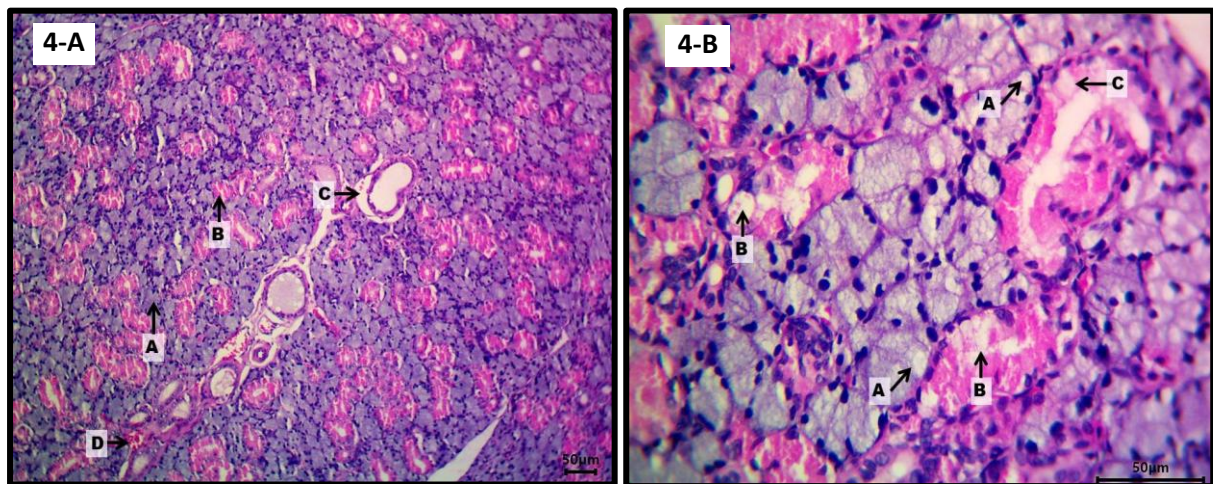


Figure:(4) 4-A photomicrograph of rat submandibular salivary gland of the G4 which received Trz+Doxo then Co-Q10, showing intact seromucous acini (A), granular convoluted tubules (B) and detachment of the striated ducts from the basement membrane (C) with congestion of blood vessels (D), 4-B degeneration and necrosis of the cells lining seromucous acini (A), granular convoluted tubules (B) and striated ducts (C).

The subsequent figures show significant results of the SMG toxicity in cell injury, inflammation, and increased fibrous tissue in group 2, which received TRZ+DOX without protection in comparison with other groups. These results were employed as scores according to the degrees of toxicities. These scores are then conducted as histograms as in Figures 5, 6, and 7.

a) Cell Injury

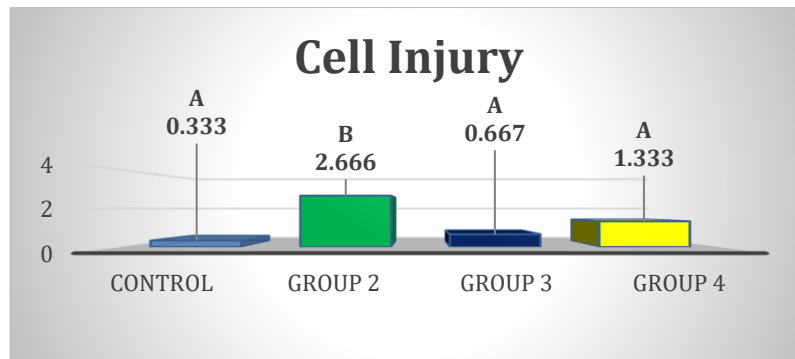


Figure (5): Histogram of comparison of mean ranks differences of scores of cell injury of rats SMG among four groups at the end of study.

b) Inflammation

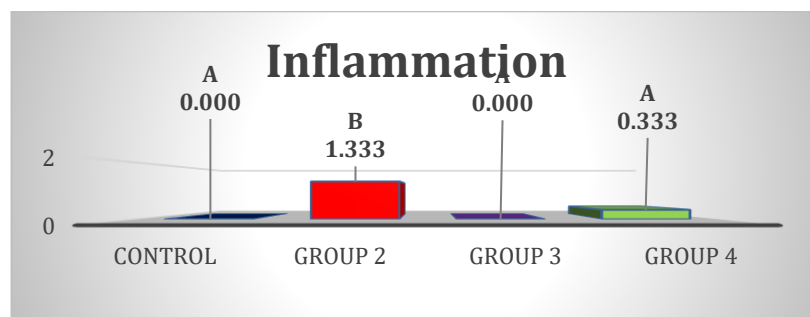


Figure:(6) Histogram of comparison of mean ranks differences of scores of the inflammation of rats SMG among four groups at the end of study

c) Fibrous Tissue

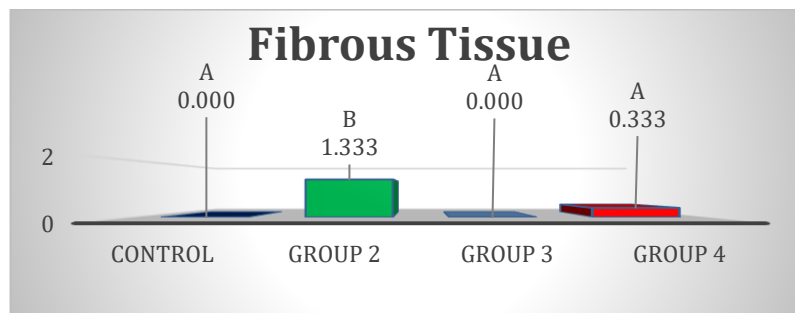


Figure:(7) Histogram of comparison of mean ranks differences of scores of the increase fibrous tissue of rats SMG among four groups at the end of study

Analysis of serum level of malondialdehyde (MDA) of rats

The result of serum level of MDA was significantly different at ($p \leq 0.05$) value, in group-2 in comparison with group-1 and group-3, with little variant but not significant difference between group-2 and group-4, as in table 2 and figure 8.

Table: (2) Comparison of means and standard deviations of the serum level of MDA among groups at the end of the study

ANOVA for serum level of MDA Conc.				
Groups	Mean	Std. Deviation	F	Sig.
G1	33.450	4.886	4.759	0.021*
G2	78.825	28.616		
G3	39.850	22.428		
G4	51.875	2.681		

Significant at $P \leq 0.05$ between four groups

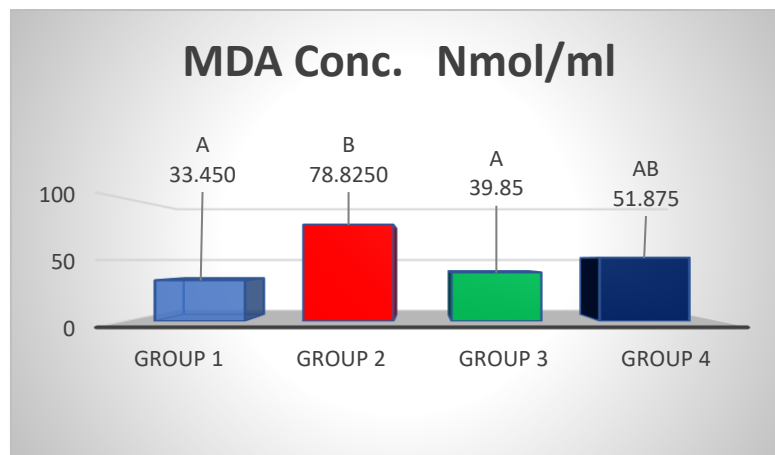


Figure:(8) Histogram of comparison of means of the serum level of MDA among all groups at the end of the study

Analysis of serum level of total antioxidant capacity (T-AOC) of rats

Table (3) revealed that there were significant differences between group-1 and group-4, however, there were no significant differences with other groups.

Table: (3) Comparison of means and standard deviations of the serum level of T-AOC among groups at the end of the study

Means and standard deviation of the serum level of T-AOC				
Groups	Mean	Std. Deviation	Kruskal-Wallis H	Sig.
G1	4.450	2.792	4.343	0.0227*
G2	4.800	3.467		
G3	7.400	3.430		
G4	8.325	2.064		

* Significant at $P \leq 0.05$ between four groups

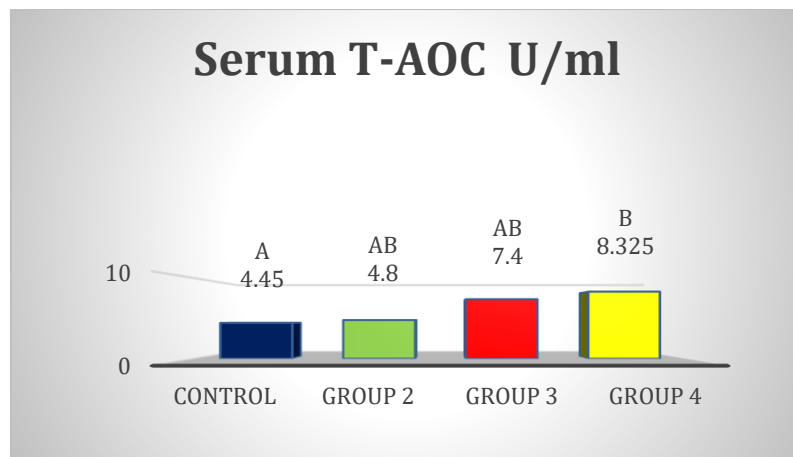


Figure:(9) Histogram of comparison of means of the serum level of T-AOC among groups at the end of the study

DISCUSSION

The body weights of rats were affected by TRZ+DOX, although, the TRZ+DOX was a direct factor led to reduction of BW, but also the administration of corn oil which was used as a solvent for Co-Q10, acted as an additional secondary factor which participated in the BW loss⁽¹⁸⁾ ⁽¹⁹⁾, and the BW reduction was higher after the middle time of the experiment in all groups,

Many mechanisms have been found to contribute to this effect. TRZ causes stomatitis, which reduces the animal's desire for food intake because of painful eating. Nauseant effect of TRZ also decreased the ability of rats to eat, and finally, diarrhea is one of the SE of the TRZ, which acted to reduce the BW of rats⁽²⁰⁾ ⁽²¹⁾. DOX had clinical effects resembling that of TRZ, in addition to causing bloody diarrhea, which further worsened the BW reduction⁽²²⁾ ⁽²³⁾.

Remarkable weight loss of rodent models by DOX had been noted by⁽²⁴⁾, and the BW loss as a result of TRZ use was observed by⁽²⁵⁾. The higher rate of BW loss with time had been agreed by⁽²⁶⁾.

Our study revealed that the connective tissues of SMG undergone to marked degeneration with dissociation of collagen fibers in the group-2 in which received TRZ+DOX without protection, the group-2 in our study revealed high variant results of tissue damage, including: cell injuries, circulatory disturbances, cell adaptation, inflammation and connective fibrous tissue damage, which also experimented previously by⁽²⁷⁾ and⁽²⁸⁾. These previous results demonstrated the potential toxicity of TRZ+DOX in the salivary gland when used as a chemotherapeutic regime. In addition, circulatory disturbances, like congestion of blood vessels, cell adaptation like atrophy and hyperplasia and inflammation in our results were came accordant to Alnuaimi⁽²⁹⁾who had focused on the chemotherapy induced circulatory disturbances

of the SMG, and recently Zhu⁽³⁰⁾ investigated inflammation of SMG caused by chemotherapies, but generally this type of injury of SMG was poorly studied.

These histological findings happened as a result of administration of TRZ to rats which adversely affects the salivary gland through binding with epidermal growth factor receptors EGFR which are required to initiate cell growth and cell survival, so blocking the EGFR will prevent cell proliferation, and cuts the cell survival pathway⁽³¹⁾ ⁽³²⁾. Also, Klymiuk⁽³³⁾ studied the potential for modulating the oral microbiome as a possible participating factor in TRZ-induced oral tissue toxicity. Additionally, DOX can cause SMG toxicities, like xerostomia, dilated ducts, formation of cysts, and degenerative and inflammatory changes of acini. Overproduction of ROS and mitochondrial membrane damage by depolarizing the membrane potential of the mitochondria participate in the cellular injury and, thus, salivary gland toxicity⁽³⁴⁾ ⁽³⁵⁾.

Alleviation of this type of oral toxicity to any possible degree is considered an important achievement. Starting from this point, we tried to face this challenge, by using Co-Q10 beside TRZ and DOX. Results showed significant improvements in groups 3 and 4 in whose rats received Co-Q10, with priority for group-3 in which Co-Q10 is administered before TRZ+DOX, explaining that administration of Co-Q10 before starting chemotherapy will reduce toxicities more, as the biological anti-oxidant system of rats were prepared for facing cytotoxic effects of TRZ and DOX.

There are several studies went in our study side, since⁽³⁶⁾ and⁽³⁷⁾ approved that the use of Co-Q10 as a non-toxic anti-oxidant can reduce the oxidative stress reactions which is usually lead to many cellular and tissue damages, and also help in increase the ability of DNA repairing, which generally protect biological system damage⁽³⁸⁾.

Co-Q10 is a mitochondrial coenzyme that is essential for the production of ATP. It is found in the cell membrane of all over the body cells, it is found at the core of cellular energy processes, it also improves cellular bioenergetics⁽¹⁸⁾ and decreases proinflammatory cytokines⁽³⁹⁾. Co-Q10 is an essential component in the mitochondrial electron transport chain which modulates different functions, like the antioxidant effect, inhibits [lipid peroxidation](#), and prevents calcium overload. And low levels of Co-Q10 are associated with many inflammatory processes and oxidative stress. According to Casagrande⁽⁴⁰⁾, Co-Q10 showed an improvement in clinical symptoms of salivary dysfunction and restored levels of salivary secretion. It has been found that Co-Q10 and other antioxidants can increase the quantity of saliva. However, increases the diameter (hypertrophy) of serous acini in both parotid and submandibular salivary glands⁽⁴¹⁾. Therefore, Co-Q10 is effectively used in restoring salivary gland functions and regenerating salivary glands⁽⁴²⁾ ⁽⁴³⁾.

Serum malondialdehyde of rats

Cancer as a disease and anticancer drugs are accompanied by tissue and cell damage⁽⁴⁴⁾; the cell distraction by anyway means leads to an increase apparent serum level of lipid peroxidation, which is measured in the form of MDA. The group-2 rats that received TRZ+DOX without Co-Q10 revealed a high serum level of MDA compared with the control group as a result of cell distraction. Rats in groups 3 and 4 that had received Co-Q10 as a protectant to reduce the toxic effects of TRZ+DOX revealed only a small elevation in serum level of MDA, both in comparison with G1(control group), with priority for G3 in which Co-Q10 is administered before TRZ+DOX.

The results of our study were parallel to Ebrahim⁽⁴⁵⁾ who demonstrated how the serum MDA could be lowered by administration of exogenous antioxidant. Many other studies went in our way in investigating the role of the antioxidant system protecting against induced tissue toxicity, through measuring serum level of MDA like⁽⁴⁶⁾and⁽⁴⁷⁾.

Serum total antioxidant capacity of rats (T-AOC)

T-AOC is used to indicate the balance between ROS production and antioxidant system efficacy. Many studies concluded that the administration of Co-Q10 will help in the reduction of oxidative stress reactions⁽⁴⁵⁾ ⁽⁴⁸⁾.

Group-2, in which rats received TRZ+DOX without protection, had a little increment in the serum T-AOC level; this result came parallel to a hypothesis which denotes cellular attempt for adaptation to the damage resulted from anticancer therapy⁽⁴⁹⁾ ⁽⁵⁰⁾. Our results of groups that received Co-Q10 showed a lot of increment in the level of serum T-AOC in G3 and G4, These results reflected that the administration of Co-Q10 will raise the capacity of the antioxidant system to face chemotherapy-induced toxicities.

Griñan⁽⁵⁰⁾also explained the importance of the use of antioxidants as an adjuvant therapy with anticancer drugs. Moreover, Gulcin⁽⁵¹⁾ and Christiansen⁽⁵²⁾ studied the role and benefits of exogenous antioxidants in reducing morbidity and disease prognosis related to cancer and anticancer drugs .

CONCLUSIONS

Co-Q10 is used in the rat model in a dose near to that used clinically in humans which is 10mg/kg body weight. It is better to administer Co-Q10 before starting administration of anticancer drugs (TRZ and DOX), since the histopathological result of rat SMG showed improvement when the Co-Q10 was used before starting TRZ and

DOX and the serum level of T-AOC raised and the serum level of MDA declined in rats when Co-Q10 was administered before TRZ and DOX.

Acknowledgment: This study was supported by the College of Dentistry at the University of Mosul / Iraq

Funding: This study is self-funded

Ethical statement: The research is approved by the Research Ethics Committee and Scientific Committee Department of Dental Basic Science/ College of Dentistry/ University of Mosul, under approval number (UoM. Dent/ A.84/ 22) on 19/12/2022.

Conflict of interest

The authors declare that there are no conflicts of interest regarding the publication of this manuscript.

REFERENCES

1. Netty (Annette) Cracknell and Alan Lamont, Whittlesea and Karen Hodson. Solid tumors. Cate. Clinical pharmacy and therapeutics. 2019. 6th edition, Elsevier, Holland; P: 909.
- (2) Schirmacher V. From chemotherapy to biological therapy: A review of novel concepts to reduce the side effects of systemic cancer treatment. International journal of oncology. 2019 Feb 1;54(2):407-19.
- (3) Bikiewicz A, Banach M, von Haehling S, Maciejewski M, Bielecka-Dabrowa A. Adjuvant breast cancer treatments cardiotoxicity and modern methods of detection and prevention of cardiac complications. ESC Heart Failure. 2021 Aug;8(4):2397-418.
- (4) Carneiro-Neto JN, Moura LB, de-Andrade CR. Protocols for management of oral complications of chemotherapy and/or radiotherapy for oral cancer: Systematic review and meta-analysis current. Medicina oral, patologia oral y cirugia bucal. 2017 Jan;22(1):e15.
- (5) Bukowski K, Kciuk M, Kontek R. Mechanisms of multidrug resistance in cancer chemotherapy. International journal of molecular sciences. 2020 May 2;21(9):3233.
- (6) Fisusi FA, Akala EO. Drug combinations in breast cancer therapy. Pharmaceutical nanotechnology. 2019 Feb 1;7(1):3-23.
- (7) Tsimberidou AM, Fountzilas E, Nikanjam M, Kurzrock R. Review of precision cancer medicine: Evolution of the treatment paradigm. Cancer treatment reviews. 2020 Jun 1;86:102019.

- (8) Sarosiek T, Morawski P. Trastuzumab and its biosimilars. *Polski Merkuriusz Lekarski: Organ Polskiego Towarzystwa Lekarskiego*. 2018 May 1;44(263):253-7.
- (9) Keam SJ. Trastuzumab deruxtecan: first approval. *Drugs*. 2020 Apr;80(5):501-8.
- (10) Kitani T, Ong SG, Lam CK, Rhee JW, Zhang JZ, Oikonomopoulos A, Ma N, Tian L, Lee J, Telli ML, Witteles RM. Human-induced pluripotent stem cell model of trastuzumab-induced cardiac dysfunction in patients with breast cancer. *Circulation*. 2019 May 21;139(21):2451-65.
- (11) Shitara K, Iwata H, Takahashi S, Tamura K, Park H, Modi S, Tsurutani J, Kadowaki S, Yamaguchi K, Iwasa S, Saito K. Trastuzumab deruxtecan (DS-8201a) in patients with advanced HER2-positive gastric cancer: a dose-expansion, phase 1 study. *The Lancet Oncology*. 2019 Jun 1;20(6):827-36.
- (12) Whalen K. Lippincott® Illustrated Reviews: Pharmacology. Wolters kluwer india Pvt Ltd; 2018 Oct 25.
- (13) Zhu L, Lin M. The synthesis of nano-doxorubicin and its anticancer effect. *Anti-Cancer Agents in Medicinal Chemistry (Formerly Current Medicinal Chemistry-Anti-Cancer Agents)*. 2021 Dec 1;21(18):2466-77.
- (14) Kiyuna LA, e Albuquerque RP, Chen CH, Mochly-Rosen D, Ferreira JC. Targeting mitochondrial dysfunction and oxidative stress in heart failure: Challenges and opportunities. *Free Radical Biology and Medicine*. 2018 Dec 1;129:155-68.
- (15) Kawakami K, Matsuo H, Kajitani N, Yamada T, Matsumoto KI. Comparison of survival rates in four inbred mouse strains under different housing conditions: effects of environmental enrichment. *Experimental Animals*. 2022;71(2):150-60.
- (16) Cho DH, Lim IR, Kim JH, Kim MN, Kim YH, Park KH, Park SM, Shim WJ. Protective effects of statin and angiotensin receptor blocker in a rat model of doxorubicin-and trastuzumab-induced cardiomyopathy. *Journal of the American Society of Echocardiography*. 2020 Oct 1;33(10):1253-63.
- (17) Khalel LI, Mammdoh JK, Ahmed AA. The histologic effects of high doses of botulinum toxin a on the rabbit's salivary gland. *Iraqi Journal of Veterinary Sciences*. 2022 Oct 1;36(4):1111-7.
- (18) Zhang Y, Mahmood T, Tang Z, Wu Y, Yuan J. Effects of naturally oxidized corn oil on inflammatory reaction and intestinal health of broilers. *Poultry Science*. 2022 Jan 1;101(1):101541.
- (19) Thimotheo Batista JP, Santos Marzano LA, Menezes Silva RA, de Sá Rodrigues KE, Simões e Silva AC. Chemotherapy and Anticancer Drugs Adjustment in Obesity: A Narrative Review. *Current Medicinal Chemistry*. 2023 Mar 1;30(9):1003-28.

- ⁽²⁰⁾ Tao G, Chityala PK. Epidermal growth factor receptor inhibitor-induced diarrhea: clinical incidence, toxicological mechanism, and management. *Toxicology Research*. 2021 May;10(3):476-86.
- ⁽²¹⁾ Sun W, Wang X, Wang D, Lu L, Lin H, Zhang Z, Jia Y, Nie X, Liu T, Fu W. CD40×HER2 bispecific antibody overcomes the CCL2-induced trastuzumab resistance in HER2-positive gastric cancer. *Journal for Immunotherapy of Cancer*. 2022;10(7).
- ⁽²²⁾ Rodak M, Dekempeneer Y, Wojewódzka M, Caveliers V, Covens P, Miller BW, Sevenois MB, Bruchertseifer F, Morgenstern A, Lahoutte T, D'Huyvetter M. Preclinical evaluation of 225Ac-labeled single-domain antibody for the treatment of HER2pos cancer. *Molecular Cancer Therapeutics*. 2022 Dec 2;21(12):1835-45.
- ⁽²³⁾ Rodrigues D, Coyle L, Füzi B, Ferreira S, Jo H, Herpers B, Chung SW, Fisher C, Kleinjans JC, Jennen D, de Kok TM. Unravelling mechanisms of doxorubicin-induced toxicity in 3D human intestinal organoids. *International Journal of Molecular Sciences*. 2022 Jan 24;23(3):1286.
- ⁽²⁴⁾ Kim D, Jang G, Hwang J, Wei X, Kim H, Son J, Rhee SJ, Yun KH, Oh SK, Oh CM, Park R. Combined Therapy of Low-Dose Angiotensin Receptor–Neprilysin Inhibitor and Sodium–Glucose Cotransporter-2 Inhibitor Prevents Doxorubicin-Induced Cardiac Dysfunction in Rodent Model with Minimal Adverse Effects. *Pharmaceutics*. 2022 Nov 28;14(12):2629.
- ⁽²⁵⁾ Kang M, Shin JI, Han S, Kim JY, Park J, Kim KI, Kang JH, Lee TS. Therapeutic response monitoring with 89Zr-DFO-pertuzumab in HER2-positive and trastuzumab-resistant breast cancer models. *Pharmaceutics*. 2022 Jun 24;14(7):1338.
- ⁽²⁶⁾ Dou XQ, Wang H, Zhang J, Wang F, Xu GL, Xu CC, Xu HH, Xiang SS, Fu J, Song HF. Aptamer–drug conjugate: Targeted delivery of doxorubicin in a HER3 aptamer-functionalized liposomal delivery system reduces cardiotoxicity. *International journal of nanomedicine*. 2018;13:763.
- ⁽²⁷⁾ Vistoso Monreal A, Polonsky G, Shiboski C, Sankar V, Villa A. Salivary Gland Dysfunction Secondary to Cancer Treatment. *Front. Oral complications in cancer patients*. 2023 Mar 2;16648714:64.
- ⁽²⁸⁾ Schvartsman G, Pinto NA, Bell D, Ferrarotto R. Salivary gland tumors: Molecular characterization and therapeutic advances for metastatic disease. *Head & neck*. 2019 Jan;41(1):239-47.
- ⁽²⁹⁾ Alnuaimi O, Mammdoh J, Al Allaf L. The role of selenium in mitigating the adverse effect of cyclophosphamide on the rat submandibular salivary glands. *Egyptian Journal of Veterinary Sciences*. 2022 Dec 1;53(4):505-16.
- ⁽³⁰⁾ Zhu J, Luo Y, Tong H, Zhong L, Gong Q, Wang Y, Yang M, Song Q. “Drying effect” of fructus aurantii components and the mechanism of action based on network

pharmacology and in vitro pharmacodynamic validation. *Frontiers in Pharmacology*. 2023;14.

⁽³¹⁾ Nemeth BT, Varga ZV, Wu WJ, Pacher P. Trastuzumab cardiotoxicity: from clinical trials to experimental studies. *British journal of pharmacology*. 2017 Nov;174(21):3727-48.

⁽³²⁾ van Herpen C, Vander Poorten V, Skalova A, Terhaard C, Maroldi R, van Engen A, Baujat B, Locati LD, Jensen AD, Smeele L, Hardillo J. Salivary gland cancer: ESMO–European Reference Network on Rare Adult Solid Cancers (EURACAN) Clinical Practice Guideline for diagnosis, treatment and follow-up. *ESMO open*. 2022 Dec 1;7(6).

⁽³³⁾ Klymiuk I, Bilgiler C, Mahnert A, Prokesch A, Heining C, Brandl I, Sahbegovic H, Singer C, Fuereder T, Steininger C. Chemotherapy-associated oral microbiome changes in breast cancer patients. *Frontiers in Oncology*. 2022;12.

⁽³⁴⁾ Zheng H, Yu Z, Zhou L, Yang X, Liu J. Seasonal abundance and activity of the hard tick *Haemaphysalis longicornis* (Acari: Ixodidae) in North China. *Experimental and applied acarology*. 2012 Feb;56:133-41.

⁽³⁵⁾ Mansy M, Soliman M, Mubarak R, Shamel M. The role of exogenous epidermal growth factor on Ki-67 proliferation marker expression in the submandibular salivary gland of albino rats receiving doxorubicin. *F1000Research*. 2020;9.

⁽³⁶⁾ Najafi M, Cheki M, Amini P, Javadi A, Shabeeb D, Musa AE. Evaluating the protective effect of resveratrol, Q10, and alpha-lipoic acid on radiation-induced mice spermatogenesis injury: A histopathological study. *International Journal of Reproductive BioMedicine*. 2019 Dec;17(12):907.

⁽³⁷⁾ Ovchinnikov AN, Paoli A, Seleznev VV, Deryugina AV. Royal jelly plus coenzyme Q10 supplementation improves high-intensity interval exercise performance via changes in plasmatic and salivary biomarkers of oxidative stress and muscle damage in swimmers: a randomized, double-blind, placebo-controlled pilot trial. *Journal of the International Society of Sports Nutrition*. 2022 Dec 31;19(1):239-57.

⁽³⁸⁾ Dawood GA, A Taqa G, Alnema MM. Histological Effect Of Coq10 On Liver And Buccal Mucosa In Mice. *Journal of Applied Veterinary Sciences*. 2020 Apr 1;5(2):1-5.

⁽³⁹⁾ Filipiak KJ, Surma S, Romańczyk M, Okopień B. Heart Failure – Do We Need New Drugs or Have Them Already? A Case of Coenzyme Q10. *Journal of Cardiovascular Development and Disease*. 2022 May 16;9(5):161.

⁽⁴⁰⁾ Casagrande D, Waib PH, Júnior AA. Mechanisms of action and effects of the administration of Coenzyme Q10 on metabolic syndrome. *Journal of Nutrition & Intermediary Metabolism*. 2018 Sep 1;13:26-32.

- (41) Ahmed AA, Mammdoh JK. Expression of Ki67 in submandibular salivary glands of rabbits after BTX injection: Histological and immunohistochemical study. *Iraqi Journal of Veterinary Sciences*. 2022 Jul 1;36(3):611-20.
- (42) Ayers J, Cook J, Koenig RA, Sisson EM, Dixon DL. Recent developments in the role of coenzyme Q10 for coronary heart disease: a systematic review. *Current atherosclerosis reports*. 2018 Jun;20:1-7.
- (43) Awad K, Sayed A, Banach M. Coenzyme Q10 Reduces Infarct Size in Animal Models of Myocardial Ischemia-Reperfusion Injury: A Meta-Analysis and Summary of Underlying Mechanisms. *Frontiers in Cardiovascular Medicine*. 2022;9.
- (44) Dawood Gh A., Taqa Gh A., Alnema M M. Histological Effect of Cytarabine on Liver and Buccal Mucosa in Mice. *Al-Rafidain Dent J*. 2020 ;20 (1):36-45. DOI: 10.33899/rden.2020.164521
- (45) Ebrahim N, Al Saihati HA, Mostafa O, Hassouna A, Abdulsamea S, Abd El Aziz M, El Gebaly E, Abo-Rayah NH, Sabry D, El-Sherbiny M, Madboly AG, Hussien NI. Prophylactic evidence of MSCs-derived exosomes in doxorubicin/trastuzumab-induced cardiotoxicity: beyond mechanistic target of NRG-1/Erb signaling pathway. *International Journal of Molecular Sciences*. 2022 May 25;23(11):5967.
- (46) Ren J, Huang R, Li Y, Chen R, Tian H, Liu C. Radioprotective effects and mechanism of HL-003 on radiation-induced salivary gland damage in mice. *Scientific Reports*. 2022 May 19;12(1):8419.
- (47) Dos Santos VR, Ferreira MK, Bittencourt LO, Mendes PF, Souza-Monteiro D, Balbinot KM, Pinheiro JD, Charone S, Pessan JP, Lima RR. Maternal fluoride exposure exerts different toxicity patterns in parotid and submandibular glands of offspring rats. *International Journal of Molecular Sciences*. 2022 Jun 29;23(13):7217.
- (48) Yi GY, Kim MJ, Kim HI, Park J, Baek SH. Hyperthermia treatment as a promising anti-cancer strategy: Therapeutic targets, perspective mechanisms and synergistic combinations in experimental approaches. *Antioxidants*. 2022 Mar 24;11(4):625
- (49) Gilliam LA, St. Clair DK. Chemotherapy-induced weakness and fatigue in skeletal muscle: the role of oxidative stress. *Antioxidants & redox signaling*. 2011 Nov 1;15(9):2543-63.
- (50) Griñan-Lison C, Blaya-Cánovas JL, López-Tejada A, Ávalos-Moreno M, Navarro-Ocón A, Cara FE, González-González A, Lorente JA, Marchal JA, Granados-Principal S. Antioxidants for the treatment of breast cancer: Are we there yet?. *Antioxidants*. 2021 Jan 31;10(2):205.
- (51) Gulcin İ. Antioxidants and antioxidant methods: An updated overview. *Archives of toxicology*. 2020 Mar;94(3):651-715.

(52) Christiansen LB, Morsing MK, Reimann MJ, Martinussen T, Birlie Z, Schou-Pedersen AM, Lykkesfeldt J, Olsen LH. Pharmacokinetics of repeated oral dosing with coenzyme Q10 in cavalier king charles spaniels with myxomatous mitral valve disease. Antioxidants. 2020 Sep 4;9(9):827.

التقييمات النسيجية والبيوكيميائية CoQ10 في التخفيف من سمية الغدد اللعابية تحت الفك السفلي التي يسببها تراستوزوماب ودوكسوروبيسين في نموذج الفئران

سيف الدين الكاكي بي ,جوناء ممدوح

الملخص

الاهداف: تهدف هذه الدراسة الى التحقق من دور مركب Co-Q10 في تقليل سمية الغدد اللعابية تحت الفك السفلي، الناتجة عن استخدام دواء تراستوزوماب و دوكسوروبيسين. **المواد وطرائق العمل:** إنَّ المواد والطرق المستخدمة لدراسة القياسات النسيجية المرضية باستخدام صبغتي H&E ، والاختبارات المصلية المكونة من T-AOC و MDA ، بالإضافة إلى قياس اوزان الجردان. حيث تم لهذا الغرض استخدام 20 جرذاً أبيض اللون من نوع البينو وأجريت التجربة على مدى 20 يوماً ، وقسمت الفئران إلى 4 مجموعات G1: حيث تلقت الفئران زيت الذرة النقي 1 مل / كجم عن طريق الفم ، يومياً لمدة 20 يوماً G2. حيث تلقت الفئران TRZ + DOX ، جرعة واحدة من 10 مجم / كجم IP لكلا العقارين في اليوم العاشر من التجربة G3. حيث تلقت الجردان Co-Q10 عن طريق الفم ، 10 مجم / كجم يومياً من اليوم الأول حتى اليوم العاشر و TRZ + DOX جرعة واحدة من 10 مجم / كجم IP لكلا العقارين في اليوم العاشر. و G4 حيث تلقت الجردان جرعة واحدة من TRZ + DOX مقدارها 10 مجم / كجم IP من كلا العقارين في اليوم العاشر وCo-Q10 بجرعة 10 مجم / كجم يومياً عن طريق الفم من اليوم العاشر إلى اليوم العشرين من التجربة. **النتائج:** وقد أظهرت نتائج الفحص النسيجي المرضي أن مجموعة الجردان التي تلقت TRZ + DOX أظهرت عن العديد من التغييرات مقارنة مع مجموعة السيطرة (المجموعة العادية) والتي لم تتلقَ الجردان فيها TRZ + DOX ، وكانت هناك زيادة في مستوى مصل MDA مع زيادة طفيفة في مستوى مصل

