



Research Article

The Impact of Two Platelet Concentrates on Healing of Surgically Created Bone Defects in Sheep (Radiological Analysis)

Amina Abdolfattah Humadi*¹ , Rayan Salim Hamed¹ , Hayam Nori Awad² 

1 Department of Oral and Maxillofacial Surgery, College of Dentistry, University of Mosul/ Iraq.

2 Department of Basic Dental Sciences/College of Dentistry/ University of Duhok, Kurdistan Region, Iraq

* Corresponding author: aminahabdufattah@gmail.com


Abstract: The present study aims to assess the density of bone with Concentrated growth factors and advanced plasma-rich fibrin in the bone defects that were created surgically in the sheep's mandible by the use of radiographic assessment. **Materials and methods:** Seven defects were made in the bone with 4 mm depth and width on every side of the mandible of the eight sheep, The defects were filled in the following manner: from the proximal to the distal orientation; 1st, 2nd, 3rd, 4th, and the 5th defect was full of CGF on the right side and A-FRF is in the left side, the 6th, and 7th left empty to filled with physiological clot. Densitometric analysis of the defects of the bone was made to measure the bone density of the 4 intervals (3 days, 7 days, 21 days, 28 days), after the surgery. **Results:** The result of the Densitometric analysis revealed a major distinction between the CGF group and the A-PRF group when compared to the control group at all four intervals, with the density of the bone being the highest in the CGF group, followed by the A-PRF group and the control group was the least one show improvement in the bone density. **Conclusions:** The CGF group increased the density of the bone throughout the entire study period, as found by densitometric analysis data.

Received: 26 March 2024

Revised: 27 April 2024

Accepted: 28 April 2024

Published: 5 March 2025



Copyright: © 2025 by the authors. This article is an open-access article distributed under the terms and conditions of the Creative Commons Attribution (CC BY 4.0) license (<https://creativecommons.org/licenses/by/4.0/>).

Citation: Humadi AA, Hamed RS, Awad HN. The Impact of Two Platelet Concentrates on Healing of Surgically Created Bone Defects in Sheep (Radiological Analysis). Al-Rafidain Dent J. 2025;25(1):142-150.



[10.33899/rdenj.2024.148248.1253](https://doi.org/10.33899/rdenj.2024.148248.1253)

Keywords: Advanced platelet-rich fibrin, Bone density, Concentrated growth factors

INTRODUCTION

Augmentation of the deficiencies of the bone caused by infections, tumors, trauma, and surgical excision is one of the major difficulties¹. Different types of graft materials have been developed in oral and maxillofacial procedures to restore bony deformities². Bioactive molecules are one of these materials that act by increasing osteoblastic differentiation and accelerating bone healing, over the past twenty years, platelet concentrate has developed from the first-generation platelet-rich fibrin (PRP), plasma rich in growth factors to the second generation for example advanced rich fibrin (A-PRF).

These are autologous products that contain more concentration of leukocyte and have a flexible mesh of fibrin and this mesh acts like a scaffold for increased migration of the cells and through its contents have angiogenic, osteogenic, and antimicrobial activities assisting in the regeneration of tissues. The second generation has an easier preparation, faster, and cheaper with the entire fibrin matrix resulting in flexible tridimensional mesh³. Another bioactive material is concentrated growth factor (CGF) that developed by a scientist called Saccoin the year 2006.

In a specifically designed centrifuge, (Medifuge; Italy) the CGF can be produced by the centrifugation of the venous blood with a pre-programmed centrifugation cycle, and this cycle gave us a platelet concentrated in a layer that resembles the gel layer, containing a matrix of fibrin that rich with GFs and leukocytes. CGF can degranulate the alpha granules that are found in the platelets which play an important role in the process of early healing of the wound and it is suggested that the CGF include more GFs than the other generations of the platelet-based bioactive materials⁴.

This study aims to assess the density of bone with Concentrated growth factors and advanced plasma-rich fibrin in the bone defects that were created surgically in the sheep's mandible by the use of radiographic assessment.

MATERIALS AND METHODS

The study received approval from the Scientific Research Committee / Department of Oral and Maxillofacial Surgery / College of Dentistry / University of Mosul.

Eight male healthy sheep (age 1.5-2 yrs) with a weight range between 40-45 (mean equal to 42.5 Kg) were involved in our study, the sheep were from the same farm. The health and the feeding were supervised by a veterinarian. The sheep were acclimated for two weeks before the procedures and the general state inspected to ensure there were no infectious diseases. All the surgeries were done by the same surgeon to prevent operator errors. Surgeries will be conducted at the College of Veterinary College /university of Mosul. All eight sheep were operated on using the mandibular

bone of both sides in which seven monocortical defects were created, on one side five of them augmented with A-PRF alone and the other two served as control negative, on the other side of the mandible five of the defects augmented with CGF while the other two defects served as control negative. Every two sheep served one observational period divided into (3, 7, 21, and 28 days/a total of 8 sheep) and at completion, the sheep were slaughtered by a licensed butcher.

Preparation of A-Platelet Rich Fibrin and Concentrated Growth Factor

The jugular vein is our target to collect blood from the sheep. Two – 10 ml blood samples were taken to a plastic tube without any coatings and the samples were centrifuged immediately. The centrifuge cycle for the preparation of an Advanced rich platelet fibrin according to the preparation protocol is 14 min – 1500 rpm by (Hettich Universal 320 Zentrifugen) and for concentrated growth factor: 30sec -acceleration, 2 min – 2700 rpm, 4min -2400- rpm, 4min - 2700 rpm, 3 min – 3000 rpm, 36sec – deceleration and stop by (Medifuge, Silfradent, Sofia, Italy). After centrifuge cycle, the membrane (the platelet-rich side i.e. proximal to the red end) was shredded and placed inside the allocated bone defect.

Surgical procedure: The operation was performed under the effect of general anesthesia and optimal sterile conditions. Intramuscular injection of a combination of medicines that contain (10 mg/ml/kg) ketamine hydrochloride as a general anesthetic agent (Hameln/Germany) and (2mg/ml/kg) xylazine solution as sedation and analgesia (Intercheme / Holland) was given for the general anesthesia (induction and maintenance). With a 15-scalpel blade, the fleece that may remain was scraped off and this was done after the sheep was anesthetized. We disinfect the surgical area with a 10% povidone-iodine solution (Iraq). Local anesthesia (2% Lidocaine with adrenaline 1:80,000) (new static / Colombia) was placed by infiltration at the operation region before cutting to obtain hemostasis. A transverse incision of about 5 cm was made in the skin and the periosteum along the surface of the mandible. Exposure of the bony segment was accomplished by a periosteal elevator. To create seven standardized monocortical defects in the mandible, a trephine bur of 4mm in width and 4mm in depth placed on a straight angle handpiece (speed of the handpiece 1000 rpm) was used. The trephine bur was placed perpendicular to the long axis of the bone surface during the preparation of the defects. Each side of the mandible was drilled with seven 4 mm wide and 4 mm deep typical bone defects, spaced 5 mm apart, using cooled 0.9 percent normal saline. By the use of tweezers, we filled the seven defects in the following manner: the first five defects were filled with CGF on one side and A-PRF

on the other side, and the last two defects acted as a control on both sides filled with a physiological clot. Before the wound was closed, the periosteum was replaced over the defects, A non-absorbable 3-0 black silk suture was used to close the wound, and the wound was treated with an antibiotic aerosol spray.

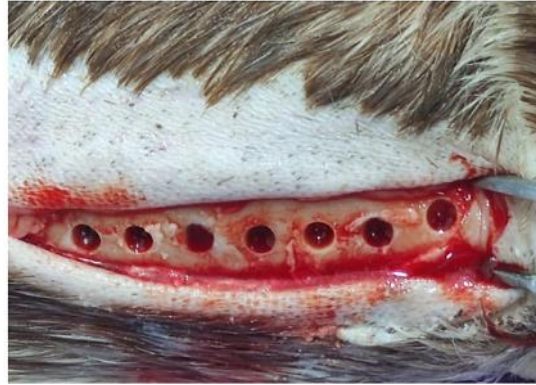

Figure (1): Seven standard bone defects of 4mm in width and depth with 5 mm apart on each side of the mandibular bone.

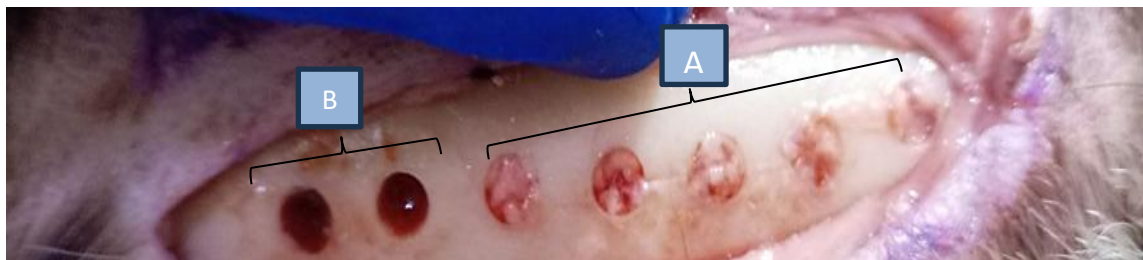

Figure (2): A- Five defects filled with platelet-rich side.
B- Two defects filled with physiological clots.

Radiographic Assessment

A licensed butcher euthanized each sheep at the end of the procedure's timetable. After the animals had been euthanized, then autopsy specimens (7 cm mandible autopsy) were taken from each sheep and sliced into 7 mm samples, and the overlaying soft tissue was peeled away. An experienced radiologist at Al-Rasheed Radiographic Centre in Mosul, Iraq, used imaging analysis software (version 7.0.3) to evaluate the X-ray pictures of each sample that were taken with a digital dental radiological machine. The parallel technique was used as an imaging procedure to avoid any geometrical distortion in the image. The power was set at 50 milliamperes per second and 60 kilovolts (kilovolt). The setting of the sensor (size = 1 Care stream; RVG 5200) on a digital sensor positioner, visualizing the specimen in the center of the sensor, and then setting the X-ray source at a distance of five centimeters from the sensor allowed us to figure out the optimal source-object distance. To get an accurate reading, the sensor was aligned horizontally and vertically perpendicular to the long axis of the object. At the upper, lower, and mid-defect areas, we aimed to measure

densitometric values that reflect bone density within our defect. For densitometric data the graph is displayed with the value (0) as black and the value (255), as white. Bone has a higher density when the mean densitometric value is higher, and vice versa. The bone defect was the area of focus. The linear drawing option was used to mark the defect's two sides with red lines after picture acquisition; the mean of three readings (upper border, mid-defect area, and lower border) was taken into account for each defect. The upper, middle, and lower area averages were combined and the average mean indicated the total densitometric mean of bone density in a two-dimensional image of the defect.

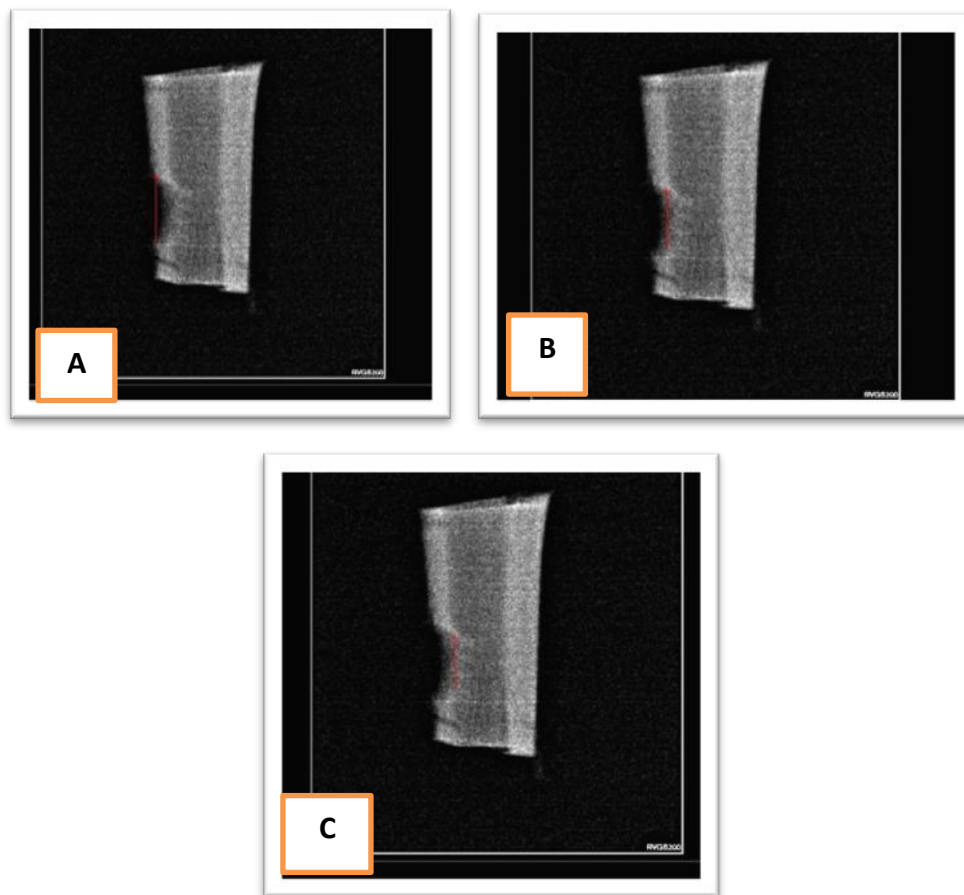


Figure (3): Densitometric examination of the upper (A), middle (B), and lower (C) portions of the bone defect is performed using a linear (red line) selection.

Statistical Analysis: After checking the variables, they appear to be non-parametric. So, we used these tests: The Kruskal-Wallis test, this test was used to determine the significance of each interval in the same group, and the Mann-Whitney test was used to show the significance between the groups.

RESULTS

The animals healed without any complication, and there was a total of 112 samples analyzed. Descriptive and Kruskal-Wallis tests were used to analyze the mean grayscale in the control surgical bone defect group, advanced plasma-rich fibrin, and concentrated growth factor group at the four intervals showed a statically significant among the three groups. Mann – Whitney test between intervals gives us information that there are significant differences between the mean of the grayscale values at three days intervals in the control bone defect and A-PRF group when we compared it to the other three intervals, a significant difference in seven days, twenty-one days intervals surgical bone defects and twenty-eight days intervals. And a significant difference in the seven days interval surgical bony defects Versus twenty-one- and twenty-eight-days intervals.

There was a significant difference between twenty-one- and twenty-eight-days intervals. The result of the CGF group revealed a significant difference between the mean of the grayscale values in the 3-day interval when we compared the group to the seven days, twenty-one days, and twenty-eight days intervals of control and A-PRF groups with superiority of the CGF group. The Whitney test results of the mean gray value showed statistical significance in all three groups, with correspondingly higher mean values in the CGF. group followed by the A-PRF. group.

Table (1): Mean grayscale value comparison of each group at four-time intervals. Value is Mean (Standard Deviation SD).

Groups	3 Days	7 Days	21 Days	28 Days
Control	49.93 (.1601)	50.20 (.3031)	72.80 (.1403)	73.34(.1940)
A-PRF	55.21 (.1890)	55.71 (.08)	87.34 (.1621)	87.73 (.0777)
CGF	66.33 (.1742)	66.65 (.1529)	100.29 (.2037)	100.58 (.1805)

Table (2): Mean grayscale value comparison among the three groups at four-time intervals. Value is significant.

Groups	3 Days	7 Days	21 Days	28 Days
Control vs. CGF	.00	.00	.00	.00
Control vs. A-PRF	.00	.00	.00	.00
A-PRF vs. CGF	.00	.00	.00	.00

*Significance set at $p \leq 0.05$

DISCUSSION

Bone is a dynamic biological tissue consisting of metabolically active cells that are integrated into a rigid framework. The bones' healing potential affected by many factors such as biomechanical, cellular, hormonal, biomechanical and pathological

factors. An ongoing state of bone deposition, resorption, and remodeling favors the healing program⁵.

The bone defects especially the large ones are very serious complications, most often caused by trauma, tumors, infection, or congenital musculoskeletal disorders. If a non-union occurs, the bone defect is repaired by implantation using biomaterials that have been developed as defect fillers and promote bone regeneration⁶. In this study we use the concentrated growth factor (CGF) and advanced platelet-rich fibrin (A-PRF) as biomaterials to fill the bone defects and induce osteogenesis, we use sheep as an animal model, the animal models are widely used in biomedical research and this may be because in vitro models cannot fully replicate the complex nature of the human body, Sheep is a very good animal model for evaluating biomaterials for bone regeneration⁷.

In our study the CGF group showed a superiority in the result when compared to the A-PRF and control group, there is a study that agrees with us, CGF increased bone ratio, and CGF has reconstructive and regenerative growth factors that help in increase bone mass⁸. And also, preetibhadouria in 2023 mentioned in his study that CGF when compared with A-PRF found that CGF can increase bone density and volume.

This may be due to the ability of CGF to promote osteogenic differentiation of the marrow of the bone and induct cell migration, like endothelial and fibroblast cells, and CGF's ability to prolong the release of growth factors¹⁰.

CONCLUSIONS

At the end of our study, with the limitation of this study, our study concludes that throughout the study time and as shown by the digital radiography (densitometric analysis) result both CGF and A-PRF can increase bone density with superior to CGF, CGF appears to be a well-accepted and minimally invasive technique to be used clinically in the future.

Acknowledgment: This study was supported by the College of Dentistry at the University of Mosul / Iraq

Funding: This study is self-funded

Ethical statement: All the experiments were approved by the Committee of Ethics of the University of Mosul/College of Dentistry.

Conflict of interest

The authors declare that there are no conflicts of interest regarding the publication of this manuscript

REFERENCES

1. Chen Y, Xu J, Huang Z, Yu M, Zhang Y. An Innovative Approach for Enhancing Bone Defect Healing Using PLGA Scaffolds Seeded with Bone Marrow Mesenchymal Stem Cells (BMSCs). *Nat Publ Gr [Internet]*. 2017;(February):1–13.
2. Lee E, Kim D, Lim H, Lee J, Jung U, Choi S. Comparative evaluation of biphasic calcium phosphate and biphasic calcium phosphate collagen composite on osteoconductive potency in rabbit calvarial defect. 2015;1–7.
3. Caruana, Andree ; Savina , Daniele; et al . 2019 .From platelet-Rich Plasma to Advanced Platelet-Rich Fibrin: Biological Achievements and Clinical in Modern Surgery . *European Journal of Dentistry* , Vol.13(2): 280-286.
4. Lokwani, Bhavna Vasudev; Gupta, Deeksha, et a .2020. The Use of concentrated growth factor in dental implantology: A system review. *The Journal of Indian prosthodontics Society*.Vol.20 (1): (3-10).
5. Kalfas, I.H.2001. Principles of bone healing. *Neurological focus*, Vol.10(4): 1-4.
6. Li, y; Chen, k; LI, L; Qin, L; Wang, X-L and Lai, Y. 2015. Bone Defect Animal Models for Testing Efficacy of Bone Substitute Biomaterials. *Journal of Orthopedic Translation*. Vol.4(3): 95-104.
7. Sartoretto, S. C; Uzeda, M.J; Miguel, F.B; Nascimento, J. R; Ascoli, F. and Calasans-Mia, M. D. 2016. Sheep as an Experimental Model Implant Evaluation.*Acta Ortopedica Brasileira*. Voi.24: 262-266.
8. Sitamahalakshmi, K; Bingi, S.K; Kumar, G.K; Bhuvanesh, Y; Sai, S.K and Parkavi, S. 2024. Rejuvenation of Bone Volume with CGF and I-PRF in Intra-Osseous Defects. *Bioinformation*. Vol.(1): 85.
9. Preetibhadouria, D.A.S.P; Sharma, C; Sankey Kumar Baidya, D.R.K.S. and Dhimte, S. 2023. Evaluation of Concentrated Growth Factor and Advanced Platelete Rich Fibrin around Peri-implant Tissues in Maxillary Anterior Region. *Pakistan Heart Journal*.Vol.56(1):644-648.
10. Stanca, E; Calabriso, N; Giannotti, L; Nitti, P; Stanca, Damiano, F; and Stanca, B. D. C. 2021. Analysis of CGF Biomolecules, Structure and Cell Population: Characterization of the Stemness Features of CGF Cells and Osteogenic Potential. *International Journal OF Molecular Science*.Vol.22.(16):8867.

تأثير نوعان من تراكيز الصفائح الدموية على شفاء العيوب المصنوعة جراحيا في الاغنام (تحليل شعاعي)

امنة عبدالفتاح حمادي, ريان سالم حامد, هيام نوري

الملخص

الاهداف: تهدف هذه الدراسة الى تقييم كثافة العظام مع عوامل النمو المكثفة والفبرين الغني بالصفائح الدموية المتقدمة في عيوب العظم التي تم صنعها جراحيا في عظام الفك السفلي للاغنام باستخدام التقييم الشعاعي. **المواد وطرائق العمل:** لقد تم اجراء سبعة عيوب جراحية في الفك السفلي (القسم الأيمن و القسم الايسر) للاغنام بقطر 4 مم و عمق 4 مم ثم تم ملئ العيوب بالترتيب التالي: العيب الأول و الثاني و الثالث و الرابع و الخامس (عوامل النمو المكثفة بالجانب الأيمن و الفبرين الغني بالصفائح الدوية المتقدمة بالجانب الايسر)، اما العيب السادس و السابع فقد ترك فارغا ليملى بتخثر دموي. لقد استخدمنا التصوير الشعاعي الرقمي لغرض تقييم كثافة العظام و ذلك خلال الفترات الزمنية (ثلاثة أيام, سبعة أيام, واحد و عشرون يوما, ثمان و عشرون يوما). **النتائج:** لقد كشفت النتائج عن وجود فرق كبير جدا و ذو دلالة إحصائية خلال الفترات الزمنية التي استخدمت في الدراسة في مجموعة عوامل النمو المكثفة و مجموعة الفبرين الغني بالصفائح الدموية المتقدمة و ذلك عندما تم مقارنتها مع المجموعة الضابطة، وعندما قمنا بالمقارنة بين المجموعات تم الكشف عن اختلاف كبير جدا و ذو دلالة إحصائية، و كان اعلى متوسط في الفترة الزمنية (ثمان و عشرون يوما) بعد الجراحة لمجموعة عوامل النمو المكثفة. **الاستنتاجات:** كانت عوامل النمو المكثفة هي اكثر مادة ساهمت بتحسين كثافة العظام و قامت بالمحافظة عليها (تأثير تآزري) طوال فترة الدراسة كما وتم اظهارها من خلال نتائج التصوير الرقمي الاشعاع.