



Research Article

## Modulation Effects of Formulated Topical Nifedipine Ointment on IL- 6 and C-Reactive Protein During Facial Skin Wound Healing in Rabbits

Wasan J. Al-Dabbagh\*<sup>1</sup> , Faehaa A. Al-Mashhadane<sup>2</sup> , Ayad A. Al-Sarraj<sup>2</sup>   
Saba I. Thanoon<sup>3</sup> , Nenuphar N. Ibrahim<sup>4</sup> 

1 Ministry of Health, Ninevah Health Directorate, Albatool Teaching Hospital, Mosul, Iraq

2 Department of Basic Dental Sciences/College of Dentistry/ University of Mosul, Mosul, Iraq

3 Ministry of Health, Ninevah Health Directorate, Ibsina Teaching Hospital, Mosul, Iraq

4 Ninevah Health Directorate, Mosul, Iraq


\* Corresponding author: [wasan.20dep8@student.uomosul.edu.iq](mailto:wasan.20dep8@student.uomosul.edu.iq)

Received: 05 June 2024

Revised: 20 July 2024

Accepted: 28 July 2024

Published: 5 March 2025



**Copyright:** © 2025 by the authors. This article is an open-access article distributed under the terms and conditions of the Creative Commons Attribution (CC BY 4.0) license (<https://creativecommons.org/licenses/by/4.0/>).

**Citation:** Al-Dabbagh WJ, Al-Mashhadane FA, Al-Sarraj AA, Thanoon SI, Ibrahim NN. Modulation Effects of Formulated Topical Nifedipine Ointment on IL-6 and C-Reactive Protein During Facial Skin Wound Healing in Rabbits. Al-Rafidain Dent J. 2025;25(1):132-141.



[10.33899/rdenj.2024.150485.1261](https://doi.org/10.33899/rdenj.2024.150485.1261)

**Abstract:** The current study aimed to assess the modulation effect of 1% and 2% topical nifedipine ointment on IL-6 and CRP during facial skin wound healing in rabbits. **Materials and Methods:** Nifedipine ointments of 1% and 2% were prepared. Fifty healthy male rabbits were included and divided equally into two groups based on the research period: group A (7 days) and group B (14 days). Each group was divided into five groups, each with five rabbits. Group I (normal), Group II (negative control), Group III (positive control), Group IV (NFD1%), and Group V (NFD 2%). All animals except group I were anesthetized. A circular, full-thickness excisional wound of 1 cm in diameter was surgically induced on each rabbit's forehead. The wounds were left open; group II did not receive any treatment. Group III, Group IV, and Group V were treated topically twice daily with white petrolatum jelly, nifedipine ointment 1%, and nifedipine ointment 2%, respectively, until the day of euthanasia. Blood samples (5 mL) were collected on the 7th and 14th days from all animals via the jugular vein during euthanasia. The serum was separated for measurement of IL-6 and CRP. **Results:** On the 7th day, there was a significant rise in IL-6 and CRP levels in the NFD1% and NFD2% groups compared to the other groups, but the increase was greater in the NFD2% group. On the 14th day, there was no significant difference in IL-6 levels among the normal, negative control, and NFD1% groups, but there was a significant difference between the NFD2% group and the other groups. There was no significant difference in the CRP level between the NFD1% and NFD2% groups. **Conclusions:** Topical application of NFD1% ointment improves facial skin wound healing in rabbits by moderately modulating the inflammatory response and accelerating wound closure, whereas the modulating effect of NFD2% ointment delays healing.

**Keywords:** C-reactive protein, Nifedipine, Wound healing, IL-6

## INTRODUCTION

Nifedipine (NFD) is an antihypertensive and antianginal L-type calcium channel blocker that relaxes vascular smooth muscle and has a negative inotropic and chronotropic impact <sup>(1)</sup>.

Nifedipine has vasodilatory characteristics, which increase blood supply to the wound and stimulate growth factor synthesis <sup>(2)</sup>. Gingival hyperplasia, on the other hand, is a side effect of NFD usage <sup>(3)</sup>. There have been two major inflammatory and non-inflammatory mechanisms suggested. The non-inflammatory mechanisms include defective collagenase activity due to decreased folic acid uptake. Inflammation in the inflammatory pathway could lead to overexpression of numerous cytokine factors that may contribute to the wound healing effect <sup>(4)</sup>.

The wound healing process is quite complicated and consists of several steps: hemostasis, inflammation, cell proliferation/granulation, and the remodeling stage <sup>(5)</sup>. Any changes to the wound restoration process can lead to incomplete or prolonged healing <sup>(6)</sup>.

Interleukin 6 is described as the main contributor to the activation of a large number of acute-phase proteins during inflammation <sup>(7)</sup>. It is produced in a transitory and immediate manner in response to infections and tissue damage <sup>(8)</sup>, and it is essential in stimulating the mitogenic activity of keratinocytes, as well as exerting a chemo-attractive effect on neutrophils. These effects aim to speed up the healing of wounds <sup>(7)</sup>.

Injury, infection, and inflammation all cause a significant increase in C-reactive protein levels. Evidence indicates that CRP plays an essential role in the inflammatory course and host responses to infection <sup>(9)</sup>. In this study, we assess the modulation effect of 1% and 2% topical nifedipine ointment on IL-6 and CRP during facial skin wound healing in rabbits.

## MATERIALS AND METHODS

The experimental work for this research was done in an animal house and scientific laboratory in the period from November 2021 to July 2022 and was approved by the Research Ethics Committee and Scientific Committee/Department of Dental Basic Science/College of Dentistry/ University of Mosul (approval number: UoM.Dent/A.L.6/22).

### Preparation of nifedipine ointment

Two concentrations of nifedipine ointment were made by mixing (1 & 2 g) of nifedipine powder in 100 gm of white petroleum jelly to provide a final concentration

(1%, 2%) W\W with continual mixing, using a spatula and glass plate, till identical ointments were made. They were kept in opaque containers and stored at  $25^{\circ}\text{C} \pm 2^{\circ}\text{C}$  till used <sup>(10,11)</sup>.

### **Experimental Animals:**

Fifty local healthy mature male rabbits weighing between (1.25- 1.5) Kg and aged (10-12) months were included in the study. The animals were placed individually in special cages on standard conditions (room temperature of about  $25 \pm 2^{\circ}\text{C}$  with a 12:12 hr. light-dark cycle) <sup>(12)</sup>, given free access to water and a standard diet. The rabbits were maintained in the animal house of the College of Dentistry/University of Mosul under the supervision of a veterinarian to monitor their condition and overall health before and after the surgical process.

The animals were divided equally into two groups based on euthanasia day: Group A euthanized on the 7<sup>th</sup> day, and Group B was euthanized on the 14<sup>th</sup> day after the surgical procedure. Each group was divided into five groups, each with five rabbits.: Group I (Normal): Rabbits were not exposed to any surgical procedures or treatments to standardize biochemical parameters. Group II (negative control): Rabbits were subjected to surgical procedures with no treatment. Group III (positive control), Group IV (NFD1%), and Group V (NFD 2%): Rabbits were subjected to surgical procedure, treated topically twice daily with white petroleum jelly, 1% NFD ointment, 2% NFD ointment, respectively, from the first day to the euthanizing day.

### **Surgical procedure**

Animals except the normal group were anesthetized by administering an intramuscular dose of xylazine hydrochloride (sedative and muscle relaxant) and ketamine hydrochloride (anesthetic and analgesic) at 5, 50 mg/Kg, respectively, injected into the thigh muscle <sup>(13)</sup>. The anesthetized animal was laid on its ventral side on the surgical board, and the surgical area (forehead) was shaved using scissors and a surgical scalpel, then rinsed with tap water and sterilized with povidone-iodine solutions. A full-thickness circular (1 cm in diameter) excision was carefully created using surgical blade no. 15 and forceps <sup>(14)</sup>.

### **Postoperatively**

The animals were continuously monitored, particularly in the first 24 hours following the surgical procedure, involving feeding and physical activity. They were treated topically according to their grouping twice daily at the same time till the day of euthanasia. The wounds were left open after the application of each treatment. The animals did not receive any antibiotics. Their cages were altered regularly and maintained clean to prevent wound infections.

### Blood Samples Collection

Blood samples (5ml) were drawn from euthanized rabbits' jugular veins and deposited into plain tubes. The serum was separated and stored at ( -20 °C) until utilized for biochemical parameter analysis <sup>(15)</sup>.

### Statistical Analysis

The results were expressed as mean  $\pm$  SD and variance among five experimental groups was statistically assessed via one-way analysis of variance (ANOVA) followed by the Duncan test. P values  $\leq$  0.01 were considered significant <sup>(16)</sup>.

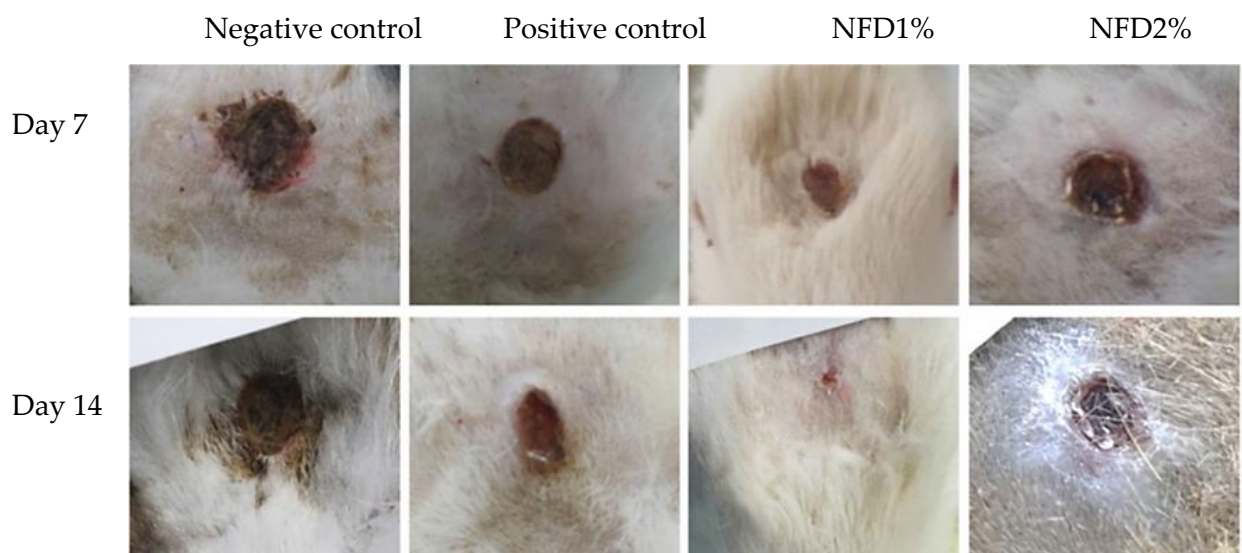
## RESULTS

### Clinical observation:

The animals were observed frequently following the topical application of NFD1% or NFD2%. No toxicity, mortality, abnormal signs and symptoms in the activity, behavioral patterns, postural irregularities, or any other clinical observations were recorded throughout the experimental period in all groups.

### Wound Healing

According to macroscopic observations, the wound changes and healing patterns of the NFD 1% group were more advanced than those of the other groups, over the whole treatment period (Figure 1).



**Figure (1):** Macroscopic view of wound healing progression in experimental groups during the study period.

### Comparisons of serum IL6 and CRP among study groups on the 7<sup>th</sup> and 14<sup>th</sup> days

The results in Table (1) showed a substantial rise in IL6 and CRP levels in the NFD 1% and NFD 2% groups compared to the other groups **on the 7<sup>th</sup> day**. There were significant differences between the NFD 1% and NFD 2% groups. There was no significant difference between the positive control and negative control groups. **on the 14<sup>th</sup> day**, there was no significant difference in the IL6 levels among the normal, negative control, and NFD1% groups, but there was a significant difference when these groups were compared to the positive control and NFD 2% groups. There was a substantial difference between the NFD 2% group and positive control groups. There was no substantial difference in the CRP levels between the NFD 1% and NFD 2% groups, although it is clear that the NFD 1% group has less value than the NFD 2% group.

**Table (1):** The level (mean± SD) of IL6 and CRP in the serum of study groups on the 7<sup>th</sup> and 14<sup>th</sup> days

Group	IL6 (ng/L) 7 <sup>th</sup> day	IL6 (ng/L)14 <sup>th</sup> day	CRP (mg/L) 7 <sup>th</sup> day	CRP (mg/L)14 <sup>th</sup> day
Normal group	106.927±2.60814 A	107.114±2.56437 A	2.5800±0.10954 A	3.1600±0.08944 A
Negative control	153.854±3.59519 B	117.563±2.26090 A	2.8400±0.35777 A	2.7400±0.15166 A
Positive control	161.196±5.84607 B	206.477±22.86742 C	2.9400±0.21909 A	4.8200±0.65727 C
NFD 1%	192.835±4.67457 C	115.538±1.37670 A	4.3200±0.66106 B	3.9400±0.46690 B
NFD 2%	289.947±41.97752 D	175.521±8.91597 B	6.6800±0.43818 C	4.1800±0.21679 B
<b>P-value</b>	0.000**	0.000**	0.000**	0.000**

Each group consists of 5 animals. Data expressed as Mean ± Stander error

\*\* Highly Significant at P ≤ 0.01

The different letters in the column indicate significant variations between the groups at P ≤ 0.01.

## DISCUSSION

Wound healing is a natural response to tissue injury, restoring injured tissue to its normal state. Many chemical agents can expedite wound healing, and local treatment can improve the healing process while minimizing systemic adverse effects <sup>(17)</sup>.

Skin wound treatment with topical NFD is recorded in medical practice as isolated case reports with no standard concentrations, i.e., it is used off-label <sup>(18)</sup>. The primary advantage of using NFD topically for wound healing is low percutaneous penetration and quick metabolism in the skin; it outperforms oral treatment in terms of potentiating local effects without considerable systemic drug distribution.

Previously, a 3% concentration of topical nifedipine was investigated in pressure ulcer healing <sup>(19)</sup>. In this study, topical nifedipine concentrations of 1% and 2% were

considered using petrolatum jelly as a base. We utilized petrolatum (non-aqueous base) since it offers better adherence and a longer residence duration than creams. In addition, preparations are more stable in non-aqueous bases, as hydrolysis is less likely in the absence of water <sup>(10)</sup>.

The macroscopic observations of wounds in the present study indicated that the level of the healing process development started and progressed more rapidly in 1% of NFD-treated wounds than in 2% of NFD-treated wounds.

Based on biochemical analysis, the NFD 1% and 2% groups had significantly higher levels of IL-6 and CRP expression than the other groups in the first week, with the NFD 2% group showing the greatest increase. This finding supports prior studies that established a relationship between nifedipine usage, which promotes overexpression of cytokine factors, and gingival hyperplasia <sup>(1)</sup>.

CRP is an acute-phase protein produced by hepatocytes, and its levels rise considerably in response to infection, tissue injury, and inflammatory disorders. CRP was thought to improve tissue regeneration by increasing microbial opsonization and phagocytosis of necrotic cells, hence promoting wound healing <sup>(20)</sup>.

Although there is no clear correlation between the CRP concentration and disease severity, high values of CRP reflect inflammation and/or tissue damage, as well as difficulty in wound healing <sup>(21)</sup>.

Interleukin-6 is a pleiotropic cytokine generated by a wide variety of cells. It is essential for the prompt resolution of wound healing and plays a major role in acute inflammation <sup>(22)</sup>.

Interleukin -6 is produced early in response to injury. It stimulates the production of proinflammatory cytokines from macrophages, keratinocytes, endothelial cells, and stromal cells, as well as leukocyte chemotaxis into a wound <sup>(23)</sup>. It also promotes the shift of macrophages from the proinflammatory M1 phenotype to the reparative and TGF $\beta$ -producing M2 macrophages <sup>(22)</sup>, which initiate wound healing and are considered important players in tissue repair. As inflammation proceeds, IL-6 signaling initiates the transition to a reparative environment <sup>(23)</sup>.

The inflammatory phase in wound repair is considered to be a preparatory process for the formation of new tissue <sup>(22)</sup>. While it effectively eradicates microbial invasion <sup>(24)</sup>, the continual increasing or uncontrolled inflammation causes an unusual inflammatory profile characterized by an imbalance between MMPs and their inhibitors, preferring wound deterioration through retaining wound healing in the inflammatory phase rather than advancing to the proliferative phase, preventing rather than promoting wound healing <sup>(25,26)</sup>.

The importance of IL-6 in cutaneous wound healing can't be understated, and the timing of the inflammatory process is vital for efficient wound resolution and healing<sup>(23)</sup>. Although several studies have shown that IL-6-deficient animals have poor wound healing due to impaired inflammation, granulation tissue formation, and re-epithelialization, excessive levels of IL-6 have been linked to poor wound healing and implicated in the development of various inflammatory diseases<sup>(27,28,29)</sup>.

Based on our results, topical treatment with 1% NFD ointment significantly accelerated wound healing in rabbits and reduced the number of days required for full healing as compared to other groups, while 2% NFD ointment had no such impact. This could be attributed to the moderately modulating effect of 1% NFD ointment on the IL-6 and CRP levels during the inflammatory phase, which favored wound debridement and facilitated the easy progression of damaged tissue to later stages of healing, whereas 2% NFD ointment caused a greater and more sustained inflammatory response, which may contribute to the delayed healing process.

## CONCLUSIONS

Topical application of 1% NFD ointment exhibited more beneficial healing activity in a full-thickness wound model through proper modulation of the inflammatory phase during the healing process, whereas NFD2% ointment may cause an uncontrolled inflammatory response, leading to delayed healing.

**Acknowledgment:** The authors sincerely appreciate the support provided by the University of Mosul/ College of Dentistry to reach the best quality of this study.

**Funding:** This study is self-funded

**Ethical statement:** All the experiments were approved by the Research Ethics Committee and Scientific Committee/Department of Dental Basic Science/College of Dentistry/ University of Mosul (approval number: UoM.Dent/A.L.6/22).

## Conflict of interest

The authors declare that there are no conflicts of interest regarding the publication of this manuscript

**REFERENCES**

- 1-Lauritano, D., Moreo, G., Vella, F. D., Palmieri, A., Carinci, F., & Petruzzi, M. (2021). Biology of Drug-Induced Gingival Hyperplasia: In Vitro Study of the Effect of Nifedipine on Human Fibroblasts. *Applied Sciences*, 11(7), 3287.
- 2- Mojiri-Forushani, H. (2018). The role of calcium channel blockers in wound healing. *Iranian journal of basic medical sciences*, 21(12), 1198.
- 3-Tonsekar, P., & Tonsekar, V. (2021). Calcium-Channel-Blocker-Influenced Gingival Enlargement: A Conundrum Demystified. *Oral*, 1(3), 236-249.
- 4- Hemmati, A. A., Forushani, H. M., & Asgari, H. M. (2014). Wound healing potential of topical amlodipine in full thickness wound of rabbit. *Jundishapur journal of natural pharmaceutical products*, 9(3).
- 5-Miricescu, D., Badoiu, S. C., Stanescu-Spinu, I. I., Totan, A. R., Stefani, C., & Greabu, M. (2021). Growth Factors, Reactive Oxygen Species, and Metformin—Promoters of the Wound Healing Process in Burns?. *International Journal of Molecular Sciences*, 22(17), 9512.
- 6-Mojiri-Forushani, H. (2018). The role of calcium channel blockers in wound healing. *Iranian journal of basic medical sciences*, 21(12), 1198.
- 7-Agyare, C., Osafo, N., & Boakye, Y. D. (2019). Biomarkers of Wound Healing. *Wound Healing-Current Perspectives*.
- 8-Tagliari, E., Campos, L. F., Casagrande, T. A. C., Fuchs, T., de Noronha, L., & Campos, A. C. L. (2021). Effects of oral probiotics administration on the expression of transforming growth factor  $\beta$  and the proinflammatory cytokines interleukin 6, interleukin 17, and tumor necrosis factor  $\alpha$  in skin wounds in rats. *Journal of Parenteral and Enteral Nutrition*.
- 9-Sproston, N. R., & Ashworth, J. J. (2018). Role of C-reactive protein at sites of inflammation and infection. *Front Immunol.* 2018; 9: 754. URL: <https://www.frontiersin.org/articles/10.3389/fimmu>.
- 10- Friciu, M., Chefson, A., & Leclair, G. (2016). Stability of Hydrocortisone, Nifedipine, and Nitroglycerine Compounded Preparations for the Treatment of Anorectal Conditions. *The Canadian journal of hospital pharmacy*, 69(4), 329.
- 11-Katsinelos, P., Papaziogas, B., Koutelidakis, I., Paroutoglou, G., Dimiropoulos, S., Souparis, A., & Atmatzidis, K. (2006). Topical 0.5% nifedipine vs. lateral internal sphincterotomy for the treatment of chronic anal fissure: long-term follow-up. *International journal of colorectal disease*, 21(2), 179-183.
- 12-Nazir, T., Shakir, L., Rahman, Z. U., Najam, K., Choudhary, A., Saeed, N., ... & Khanum, A. B. (2020). Hepatoprotective Activity of *Foeniculum Vulgare* Against Paracetamol Induced Hepatotoxicity in Rabbit. *J. Appl. Pharm*, 12, 2376-0354.

- 13-Ricci, F., Bresesti, I., LaVerde, P. A. M., Salomone, F., Casiraghi, C., Mersanne, A., ... & Lista, G. (2021). Surfactant lung delivery with LISA and InSurE in adult rabbits with respiratory distress. *Pediatric research*, 90(3), 576-583.2
- 14- Ragab, G. H., Zaki, F. M., Hassan, F. E., & Safwat, N. M. (2021). Comparable Study of Different Materials (Silver Nanoparticles, PRP and its Mixture) That Enhance Surgical Excisional Skin Wound Healing in New Zealand Rabbits; Histopathological Evaluation. *Annals of the Romanian Society for Cell Biology*, 25(6), 15966-15975.
- 15- Naji, A. H., Al-Watter, W. T., & Taqa, G. A. (2022). The Effect of Xylitol on Bone Alkaline Phosphatase Serum Level and Bone Defect Diameter in Rabbits. *Journal of Applied Veterinary Sciences*, 7(1), 6-10.
- 16-Triola, M. M., Triola, M. F., & Roy, J. A. (2006). *Biostatistics for the biological and health sciences*. Boston: Pearson Addison-Wesley.
- 17-Naghavi, M., Tamri, P., & Asl, S. S. (2021). Investigation of healing effects of cinnamic acid in a full-thickness wound model in rabbit. *Jundishapur Journal of Natural Pharmaceutical Products*, 16(1).
- 18- Brasileiro, A. C. L., Oliveira, D. C. D., Silva, P. B. D., & Rocha, J. K. S. D. L. (2020). Impact of topical nifedipine on wound healing in animal model (pig). *Jornal Vascular Brasileiro*, 19.
- 19- Zolfagharnezhad, H., Khalili, H., Mohammadi, M., Niknam, S., & Vatanara, A. (2021). Topical nifedipine for the treatment of pressure ulcer: a randomized, placebo-controlled clinical trial. *American Journal of Therapeutics*, 28(1), e41-e51.
- 20-Kingsley, A., & Jones, V. (2008). Diagnosing wound infection: the use of C-reactive protein. *Wounds Uk*, 4(4), 32-46.
- 21- Salvo, P., Dini, V., Kirchhain, A., Janowska, A., Oranges, T., Chiricozzi, A., ... & Romanelli, M. (2017). Sensors and biosensors for C-reactive protein, temperature and pH, and their applications for monitoring wound healing: a review. *Sensors*, 17(12), 2952.
- 22- Costantini, E., Aielli, L., Serra, F., De Dominicis, L., Falasca, K., Di Giovanni, P., & Reale, M. (2022). Evaluation of Cell Migration and Cytokines Expression Changes under the Radiofrequency Electromagnetic Field on Wound Healing In Vitro Model. *International Journal of Molecular Sciences*, 23(4), 2205.
- 23- Johnson, B. Z., Stevenson, A. W., Prêle, C. M., Fear, M. W., & Wood, F. M. (2020). The role of IL-6 in skin fibrosis and cutaneous wound healing. *Biomedicines*, 8(5), 101.
- 24-Bekeschus, S., von Woedtke, T., Emmert, S., & Schmidt, A. (2021). Medical gas plasma-stimulated wound healing: Evidence and mechanisms. *Redox biology*, 46, 102116.

- 25-Caley, M. P., Martins, V. L., & O'Toole, E. A. (2015). Metalloproteinases and wound healing. *Advances in wound care*, 4(4), 225-234.
- 26-Serra, F., Aielli, L., & Costantini, E. (2021). The role of miRNAs in the inflammatory phase of skin wound healing. *AIMS Allergy and Immunology*, 5(4), 264-278.
- 27-Sato, K., Takeda, A., Hasegawa, E., Jo, Y. J., Arima, M., Oshima, Y.,... & Sonoda, K. H. (2018). Interleukin-6 plays a crucial role in the development of subretinal fibrosis in a mouse model. *Immunological Medicine*, 41(1), 23-29.
- 28-Gallucci, R. M., Simeonova, P. P., Matheson, J. M., Kommineni, C., Guriel, J. L., Sugawara, T., & Luster, M. I. (2000). Impaired cutaneous wound healing in interleukin-6-deficient and immunosuppressed mice. *The FASEB journal*, 14(15), 2525-2531.
- 29-Ellis, S., Lin, E. J., & Tartar, D. (2018). Immunology of wound healing. *Current dermatology reports*, 7, 350-358.

## التأثيرات المعدلة لمرهم النيفيديبين الموضعي على الانترليوكين - 6 والبروتين التفاعلي C أثناء شفاء جروح جلد الوجه في الأرانب

وسن الدباغ, فيحاء المشهداني, أياد السراج, صبا دنون, نينوفر ابراهيم

### الملخص

**الاهداف:** تهدف الدراسة الى تقييم التأثيرات المعدلة لمرهم النيفيديبين الموضعي بنسبة 1% و 2% على IL-6 و CRP أثناء التئام جروح جلد الوجه في الأرانب. **المواد وطرائق العمل:** تم تحضير مرهم نيفيديبين 1% و 2%. تم إشراك خمسين أرنباً ذكراً سليماً وتم توزيعهم بالتساوي على مجموعتين على أساس فترة الدراسة: المجموعة أ (7 أيام) والمجموعة ب (14 يوماً). تم تقسيم كل مجموعة إلى خمس مجموعات (خمس أرانب/مجموعة). المجموعة الأولى (طبيعية)، المجموعة الثانية (السيطرة السلبية)، المجموعة الثالثة (السيطرة الايجابية)، المجموعة الرابعة (NFD1 %)، المجموعة الخامسة (NFD2 %). تم تخدير جميع الحيوانات باستثناء المجموعة الأولى. ثم تم إحداث جرح استتصالي دائري كامل السمك بقطر 1 سم جراحياً على جبهة كل أرنب. ترك الجرح مفتوحاً، المجموعة الثانية لم تتلقى أي علاج، بينما المجموعة الثالثة، المجموعة الرابعة، والمجموعة الخامسة عولجوا موضعياً مرتين يومياً بالفازلين الأبيض، مرهم نيفيديبين 1%، مرهم نيفيديبين 2% على التوالي حتى يوم القتل الرحيم. تم جمع عينات الدم (5 مل) في اليومين السابع والرابع عشر من جميع الحيوانات عن طريق الوريد الوداجي أثناء القتل الرحيم. تم فصل المصل لغرض قياس مستويات IL-6 و CRP. **النتائج:** في اليوم السابع من الدراسة، كانت هناك زيادة كبيرة في مستويات IL-6 و CRP في مجموعتي NFD1% و NFD2% مقارنة بالمجموعات الأخرى، ولكن الزيادة كانت أكبر في مجموعة NFD2%. في اليوم الرابع عشر، لم يكن هناك فرق كبير في مستويات IL-6 بين المجموعات الطبيعية، والسيطرة السلبية، ومجموعات NFD1%، ولكن كان هناك فرق كبير بين مجموعة NFD2% والمجموعات الأخرى. لم يكن هناك فرق كبير في مستوى CRP بين المجموعتين NFD1% و NFD2%. **الاستنتاجات:** التطبيق الموضعي لمرهم NFD1% له قيمة مفيدة لتحسين التئام جروح جلد الوجه في الأرانب من خلال تعديل الاستجابة الالتهابية بشكل معتدل وتسريع التئام الجرح، في حين أن التأثير المعدل لمرهم NFD2% يؤخر الالتئام.