



Characteristics of Gubernacular Canal of Impacted/ Unerupted Canine in Relation to Eruption Status by Using CBCT

Tiba S. Almoosa ^{(1)*}

Mustafa M. AL-Khatieeb ⁽²⁾

^(1, 2) Department of orthodontics, College of Dentistry, University of Baghdad, Iraq.

Keywords:

Gubernacular canal; CBCT;
Impacted canine; eruption
status.

Article Info.:

Article History:

Received: 12/6/2023

Received in revised form:
18/6/2023.

Accepted: 3/7/2023

Final Proofreading: 3/7/2023

Available Online: 1/6/2024

© THIS IS AN OPEN ACCESS ARTICLE
UNDER THE CC BY LICENSE

<https://creativecommons.org/licenses/by/4.0/>



Citation: Almoosa TS, AL-Khatieeb MM. Characteristics of Gubernacular Canal of Impacted/Unerupted Canine in Relation to Eruption Status by Using CBCT. *Tikrit Journal for Dental Sciences* 2024; 12(1): 78-88

<https://doi.org/10.25130/tjds.12.1.8>

*Corresponding Author:

Email:

teba.sajad1203a@codental.uobaghdad.edu.iq

(1) Master student,
Department of orthodontics,
College of Dentistry,
University of Baghdad, Iraq.
Dentist, Ministry of health,
Karbala, Iraq.

Abstract

To evaluate detection rates and morphology of gubernacular canal (GC) in impacted/ unerupted canine, and to determine whether there is a difference in GC characteristics between impacted and unerupted canine.

Subjects and Methods: By using CBCT, GCs were retrospectively analyzed in 300 patients with 432 impacted/ unerupted canine (96 males, 204 females; Age range, 7 to 54 years). Each imaging system software was first converted the CBCT pictures to volumetric data, from which reconstructions on multiple planes were done. Axial, sagittal, and coronal views were provided for each CBCT exposure. Furthermore, coronal sections and corrected sagittal were ready to assess all impacted/ unerupted canines for the presence of GCs, alteration in shape of GC, opening site of GC in the alveolar crest, attachment site of GC to the dental follicle, and canine eruption status. **Results:** The normal or delay eruption status of canines had high detection rate which were 95.9% and 100% respectively, unlike the impacted canine which had a low detection rate which was 71.2%. Only 8.9% of detected GC had alteration in shape. 54.1% of GC opened palatal or lingual to alveolar crest, 21.9% of GC was continuous with periodontal ligament (PDL) of primary canine, 20.5% of GC opened in the center of alveolar crest, and 3.5% of GC opened Buccally. 59.1% of GC was unusually attached to dental follicle, and 40.9% of GC was usually attached to dental follicle. There was a high significant difference between canine eruption status and characteristics of GC.

Conclusion: The findings of this study reveal that the characteristics of GC in impacted/ unerupted canine may be a sign of an abnormal eruption condition.

Introduction:

On dry skulls, the lingual or palatal surface of the deciduous teeth have a small aperture that is known as the Gubernacular canal (GC) ⁽¹⁾. The Gubernacular cord (GCo), a fibrous connective tissue filled with blood arteries, lymphatics, nerves, and epithelial cell remnants of the dental lamina, is housed in this canal. Additionally, GCo creates a number of chemical mediators that cause osteoclastic bone resorption, generating an eruptive route that directs the permanent tooth to emerge lingual to its deciduous predecessors ⁽²⁾. Due to ethical restrictions, it is challenging to analyze the physiological GCo histologically, but because the GC is a bone canal, it may be seen radiologically. However, due to their thin nature and unrelated location to the cortices in the spongy bone, it is highly challenging to distinguish these structures from bone marrow gaps using traditional two-dimensional imaging, this explains why it is only occasionally mentioned in any of the classic oral radiology textbooks ⁽²⁾. This canalicular structure has only recently been investigated in retrospective studies during the past 6-7 years due to the development of improved imaging techniques like CBCT ^(2, 3). CBCT concerning canine impaction has diagnostic potency and may impact on organizing the treatment ⁽⁴⁾. According to earlier studies ^(3, 5), the GC typical diameter ranges from 1 to 3 mm. In fact, it gets wider as the teeth advance closer the alveolar ridge to erupt. In teeth with a typical eruption pattern, the shape is typically straight or mildly curved, though there may be some variance depending on the type of tooth. On the coronal and sagittal images of CBCT, GC in teeth with a normal eruption pattern shows as a corticated tract of low density that is contiguous with the dental follicle of the erupting tooth. On the axial scan, they appear as low-density, rounded regions on the lingual side of the corresponding deciduous tooth ⁽²⁾. The coronal and sagittal scans will clearly show the length of the GC. It will vary depending on age, with smaller GCs appearing on teeth that

are about to erupt and disappearing once the dental follicle of the erupting tooth becomes continuous with the alveolar crest ⁽²⁾. Earlier studies have documented the GC's shape alterations, which include straightening, curving, obliteration, contraction, and bending. These changes in the GC's structure in impacted teeth do reflect how the GC functions during the emerging process ⁽⁵⁾. Buccal, lingual, central, or in the periodontal ligament space of the primary tooth are possible locations for the opening site of GC ⁽⁶⁾. According to our knowledge, this is the only study compared the GC detection rate regarding the impacted/ unerupted canine in each gender and such study is done for the first time on an Iraqi sample. The aims of this study were to evaluate detection rates and morphology of the GC in impacted/ unerupted canine, and to determine whether these images differ by eruption status of canine.

Materials and Methods

The Sample:

The study sample consists of 300 patients with impacted/unerupted permanent canines (Ages 7 to 54), it is classified into five age groups (7-9, 10-19, 20-29, 30-39, and ≥ 40), who underwent CBCT scans and were referred between 2014 and 2022 for implant planning, orthodontic purpose, impacted teeth localization, and dental abnormalities detection. The databases of several dental specialty centers work stations of CBCT images were gathered and analyzed with software provided by the manufacture of each CBCT unit involved in the study.

The Sample Criteria

The only requirement for inclusion is that there must be one or more teeth that are entirely encased in bone. The sample was not attempted to be categorized by age, gender, or ethne. Furthermore, effort wasn't taken to establish if the canine is impacted or unerupted. Exclusion criteria included CBCT images of low quality with metal artifacts or motion blur inhibiting GCs vision, patient under orthodontic treatment, patient subjected to

orthognathic surgery fixation, cleft palate patient, or facial trauma.

Methods (Procedure/Intervention):

Each imaging system software was first converted CBCT pictures to volumetric data, from which reconstructions on multiple planes were done. Axial, sagittal, and coronal views were provided for each CBCT exposure. Furthermore, coronal sections and corrected sagittal were ready to assess all impacted or unerupted canines for the presence of GCs.

The following image characteristics were analyzed :

1. GC detection ⁽⁷⁾:

The detection is carried out in 3 planes of CBCT images: axial, sagittal, and coronal as following:

- Detected: On coronal and sagittal CBCT views, the GC often shows as a radiolucent tract and clearly corticated borders that ranges in diameter from 1 to 3 mm, as seen in figure A and B, and its present as low-density rounded zones in the alveolar bone crest on axial CBCT images, as seen in figure 1C ⁽⁷⁾.
- Not detected: The canines are investigated in each slice of all 3 planes (axial, sagittal, and coronal) of CBCT views, if there is no existence of GC, it records not detected.(figure 1D)
- Alteration in shape of GC ^(5, 7): The GC's shape was altered in a variety of ways, including:
 - A. Thinning or contraction (diameter less than 1 mm) , as seen in figure 2A.
 - B. Deformation: irregular shape GC, as seen in figure 2B.
 - C. Folding or bending, as seen in figure 2C.
 - D. Obliteration: some of GC didn't open on the alveolar bone crest behind the deciduous teeth, extended to a distance and stopped (figure 2D) ⁽⁵⁾.
 - E. Changing in direction from the tooth's eruptive route: We

observed a difference between the tooth direction of eruption and the direction of the GC in some horizontally impacted teeth, as seen in figure 2E ⁽⁵⁾.

If GC was observed, another classification was done according to ⁽⁶⁾:

- The opening site of GC in the alveolar crest: Buccal, central, palatal or lingual, or in the periodontal ligament space (PDL) of the preceding canine (Figure 3).
- The attachment site of GC to the dental follicle (Figure 4):
 - a. Usual: The attachment site of GC to the dental follicle should be corresponded with cusp tip of canine ⁽⁶⁾.
 - b. Unusual: The attachment site of GC to the dental follicle deviates from usual location, may be buccally, lingually, distally, mesially, or cervically ⁽⁶⁾.
- 2. Status of eruption ⁽⁶⁾:

Assessment of the canine eruption status is carried out as follows:

 - A. Normal: Normal eruption cases were defined as those without observable mechanical barriers and patients who fit the mean eruption age range ^(8,9).
 - B. Delayed: When the unerupted canine was inside bone, free of any obvious mechanical obstacles, and the patient's age differed significantly from the average erupting age of the dental group (More than double the standard deviation specified for that dental group), it was said that the eruption was delayed ^(8,9).
 - C. Impacted: When a physical barrier was found, it was determined that the teeth were impacted (e.g., Supernumerary teeth, insufficient dental arch width, and tooth germ deviation) ⁽⁸⁾, and any unerupted canine with a closed apex and passed the

normal chronological age of eruption (around 10-12 years) considered as an impacted canine.

Statistical Analysis

The sample's entire data set underwent computerized statistical analysis using SPSS version 26 software (IBM, Stanford, California). The statistical analysis included: Frequency, Percentages, Chi-square test.

Results:

GC detection rate in impacted/ unerupted canines: The number of detected GC was 347 from the total number 432 cases and the detection rate of GC in impacted/ unerupted canine was 80.3%.

Detection rate of GC according to patients' gender: The detection rate of GC was 83.5 % in males, while it was 78.4 % in females, the statistical analysis reported that there was no significant difference in detection of GC between both gender using chi-square ($P > 0.05$), as shown in table 1.

Characteristics of detected GC in impacted/ unerupted canines:

1. Alteration in shape of GC:

The statistical analysis showed that 8.9 % of detected GC had alteration in shape most of them (45.2 %) were thinning in diameter (less than 1 mm), 32.3% of them had different direction to the normal, and the others showed altered shape GC, which were obliteration (16.1 %), deformation (3.2 %), or folding (3.2 %).

In relation to eruption status 83.9 % of shape alteration was found in impacted canine, while 16.1 % of shape alteration was found in normal unerupted canine, on the other hand, there was high significant difference regarding shape alteration and eruption status using chi-square test (P value < 0.01), as seen in table 2.

2. Opening site of GC in relation to the alveolar crest: (Table 3)

The statistical analysis showed that 54.1 % of GC opened palatal or lingual to alveolar

crest, 21.9 % of GC was continuous with periodontal ligament (PDL) of primary canine, 20.5 % of GC opened in the center of alveolar crest, and 3.5 % of GC opened Buccally.

In relation to eruption status 46.5 % of normally unerupted canine had GC continuous with PDL of primary canine, while 38.6 % opened palatal or lingual, 13.2% opened centrally, and only 1.8 % opened buccally.

Delayed erupted canine had 48.4 % palatal or lingual opening, while 38.7% continuous with PDL, and 12.9 % opened centrally.

while impacted canine had 64 % palatal or lingual opening, 25.9 % opened centrally, 5.1 % continuous with PDL, or opened buccally, furthermore there was a high significant difference regarding the opening site and the eruption status using chi-square test (P value < 0.01), as seen in table 3.

3. Attachment site of GC to the dental follicle: (Table 4)

The statistical analysis showed that 59.1 % of GC was unusually attached to dental follicle, and 40.9 % of GC was usually attached to dental follicle.

In relation to eruption status, the normal eruption status of canine had 91.5 % with usual attachment, delayed erupted canine had 64.5 % with usual attachment, while the impacted canine had 7.1 % with usual attachment.

The impacted canine had 92.9 % with unusual attachment, 35.5 % of delay canine eruption with unusual attachment site, and 8.5 % of normal eruption canine status with unusual attachment site, in addition there was a high significant difference between attachment site and eruption canine status using chi-square (P value < 0.01), as seen in table 4.

Detection rate of GC according to canine eruption status:

The total number of normal erupted canines was 123, while the delayed erupted canines were 31, and the impacted canine were 278 in number.

The statistical analysis also revealed that the normal or delay eruption status of canines had high detection rate which

were 95.9 % and 100 % respectively, unlike the impacted canine which had a low detection rate which was 71.2 %, furthermore there was a high significant difference using chi-square test between GC detection and eruption status (P value < 0.01), as seen in table 5.

Discussion:

The current study specialized in permanent canines because it was playing a key role in the aesthetic and chewing functions; any disruptions in the eruption of permanent canines can result in problems with the dental arch and teeth beside them, necessitating specific attention ⁽¹⁰⁻¹²⁾.

GC detection rate in impacted/ unerupted canines:

The GC detection rate in impacted/ unerupted canine was 80.3 % in general, this result agreed with a study of **Gaeta-Araujo et al** ⁽⁶⁾, whereas this rate in impacted/ unerupted canine was 81.4%.

While the detection rate in the research of **koc et al** ⁽⁷⁾ was 72.1 %, this difference in the result may be due to racial difference of population from which the sample was collected and/ or may be due to sample size difference.

In a study of **Nishida et al** ⁽⁵⁾, the GC detection rate was 87 %, but this result confined to canine of 10 years old patients and below.

Detection rate of GC according to patient gender:

The GC detection rate in females and males were about 78.4% and 83.5%, retrospectively. Furthermore, there was no significant difference between the GC detection and gender difference, this due to the small difference in number of detections between females and males. There was no previous study compared the GC detection rate regarding the impacted/ unerupted canine in each gender.

Characteristics of detected GC in impacted/ unerupted canines:

1. Alteration in shape of GC:

The altered shape GC was 8.9 % of detected GC, most of them (45.2 %)

were thinning in diameter (less than 1 mm), 32.3% of them had different direction to the normal, and the others showed altered shape GC which were obliteration (16.1 %), deformation (3.2 %), or folding (3.2 %).

These results somewhat resemble the results of **Koc et al** ⁽⁷⁾, whereas shape alterations were 12.1 % from the detected GC, these cases included GC contraction (n= 43, 56.6%), GC obliteration (n= 24, 31.6%), difference between eruption direction of tooth and GC (n= 6, 7.9%) and GC bending (n= 3, 3.9%), but these results include all teeth not only canine, unlike the current study these differences may be due to different selection criteria and methodology between studies.

In relation to eruption status, 83.9 % of shape alteration was found in impacted canine, while 16.1 % of shape alteration was found in normal unerupted canine. There was a highly significant relation between shape alteration of GC and abnormal eruption, these results agreed with the study of **Koc et al** ⁽⁷⁾, who demonstrated a substantial correlation between the eruption disruptions and the altered GC shape, and agreed with the study of **Nishida et al** ⁽⁵⁾ who explained that The GC was observed to shift, displace, and deform due to the obstructive eruption or non-eruption of the tooth.

2. Opening site of GC in relation to the alveolar crest:

The opening site of GC is usually located on the Palatal or lingual side of alveolar crest behind the primary teeth ^(6, 13) and can be located centrally, continuous with pdl of primary tooth, or buccally positioned in low frequencies ⁽⁶⁾.

In the current study there was 54.1 % of GC opened palatal or lingual to alveolar crest, 21.9 % of GC was continuous with periodontal ligament (PDL) of primary canine, 20.5 % of GC opened in the center of alveolar crest, and 3.5 % of GC opened Buccally, so these results were different from the study of **Gaeta-Araujo et al** ⁽⁶⁾, which showed that 88.4 % of GC for anterior teeth and premolars were opened lingually, 5.2 % were opened centrally, 3.6 % were opened buccally, and 2.8 % were continuous with periodontal ligament

(PDL) of primary teeth, these differences in results may be due to differences in race, sample size, and the teeth included were not only the canines.

In relation to eruption status, only 38.6 % of normally unerupted canine had GC opened palatal or lingual. On the other hand, the delayed erupted canine had 48.4 % palatal or lingual opening, while impacted canine had 64 % palatal or lingual opening. These results were differed from the study of **Gaeta-Araujo et al** ⁽⁶⁾, which showed that 91.8% of normally erupted anterior and premolars teeth had GC opened lingually, 73.7 % of delay erupted anterior and premolars teeth had GC opened lingually, and 76.5 % of impacted anterior and premolars teeth had GC opened lingually, these differences in results may be due to difference in sample size and inclusion of other teeth was not only the canines.

Furthermore, there was a highly significant difference between opening site and eruption status, this was due to the high percentage of impacted or delayed canine (64 %, 48.4 %, respectively) the opening site was palatal or lingual, in addition the normal canine eruption status showed high percentage (46.5 %) of GC, which were continuous with the PDL of primary canine.

3. Attachment site of GC to the dental follicle:

The attachment site of GC of canine was unusually attached to dental follicle with 59.1 %, and 40.9 % of GC was usually attached to dental follicle, while the study of **Gaeta-Araujo et al** ⁽⁶⁾ showed that 82.7 % of GC of anterior and premolars teeth was usually attached to dental follicle and 17.3 % of GC was unusually attached to dental follicle, these differences can be due to that the normally unerupted canines in the current study was 28.5 % of the total sample size, while the normally unerupted anterior and premolars teeth in study of **Gaeta-Araujo et al** ⁽⁶⁾ was 78.7 %.

In relation to eruption status, the normal canine eruption status had 91.5 % with usual attachment, delayed erupted canine had 64.5 % with a usual attachment, while

the impacted canine had 92.9 % with unusual attachment.

These results resemble the results of **Gaeta-Araujo et al** ⁽⁶⁾, where in normally unerupted canine which had 91.8 % with usual attachment, but different in delayed erupted canine which had 63.2 % with unusual attachment, and the impacted canine which had 55.9 % with usual attachment, these differences in results may be due to difference in sample size and inclusion of other teeth not only the canine.

Moreover, the research of **Gaeta-Araujo et al** ⁽⁶⁾, showed that with atypical eruption status, the uncommon attachment site of GC to the dental follicle was noticeably more prevalent, these findings implied that the likelihood of abnormal tooth eruption was increased if the GC connects to the follicular space in an unusual manner in the CBCT.

Furthermore, there was a high significant difference between eruption canine status and attachment site, because of high percentage (91.5 %) of normally erupted canine with a usual attachment site, and high percentage (92.9 %) of impacted canine with an unusual attachment site.

However, teeth with abnormal eruption status had considerably more unusual GC attachment sites to the dental follicle, this suggests that if the GC is found attached to the follicular space in less usual sites on CBCT, the teeth would be more liable to erupt abnormally ⁽⁶⁾.

Detection rate of GC according to canine eruption status:

The normal or delay eruption status of canines had high detection rate which were about 95.9 % and 100 % respectively, unlike the impacted canine which had a low detection rate which was 71.2 %, these results indicated that there was a relation between detection of GC and abnormal eruption status (impacted), therefore there was a high significant difference between them.

The GC detection rate in impacted/ unerupted canine in this study was different from the research of **Gaeta-Araujo et al** ⁽⁶⁾, who reported 82% detection rate in normal erupted canine,

68.8 % in delay eruption, and 65 % in impacted canine.

These differences in result of researches may be because the variation in sample size, whereas the total number of canines in research of **Gaeta-Araujo et al** ⁽⁶⁾ was 124 (82 normal eruption, 16 delay eruption, 26 impacted canine), while the total number of canines in this research was 432 (123 normal eruption, 31 delay eruption, and 278 impacted canine), this controversy in results can be due to the differences in sample selection, race, and methodology.

Conclusion:

1. The GC detection rate in impacted/ unerupted canine was 80.3 % in general, 8.9 % of them had shape alteration, more than half of them opened palatal or lingual to alveolar crest, and 59.1% of them had unusually attached to dental follicle.
2. There was no significant difference between the GC detection of impacted/ unerupted canine and gender difference, whereas the GC detection rate in females and males were about 78.4% and 83.5%, retrospectively.
3. The normal or delay eruption status of canines had a high detection rate which were about 95.9 % and 100 %

respectively, unlike the impacted canine which had a low detection rate which was 71.2 %.

4. There was a highly significant relation between shape alteration of GC and abnormal eruption, whereas 83.9 % of shape alteration was found in impacted canine, while 16.1 % of shape alteration was found in normal unerupted canine.

5. There was a highly significant difference between opening site and eruption status, this was due to the high percentage of impacted or delayed canine (64%, and 48.4%, respectively) the opening site was palatal or lingual, in addition the normal canine eruption status showed high percentage (46.5 %) of GC which were continuous with the PDL of primary canine.

6. There was a high significant difference between canine eruption status and attachment site, whereas 91.5 % of normally erupted canine had a usual attachment site, and 92.9 % of impacted canine had an unusual attachment site.

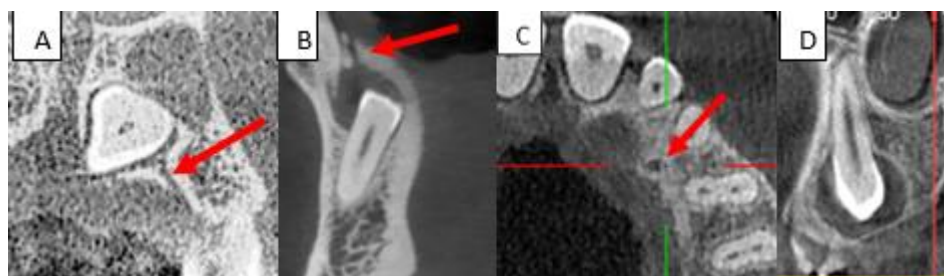


Figure 1: A: Coronal CBCT image of impacted upper left canine show GC (red arrow); B: Sagittal CBCT image of impacted lower canine show GC (red arrow); C: Axial CBCT image of GC (red arrow) of upper left impacted canine; D: Coronal CBCT image of impacted upper left canine with not detected GC.

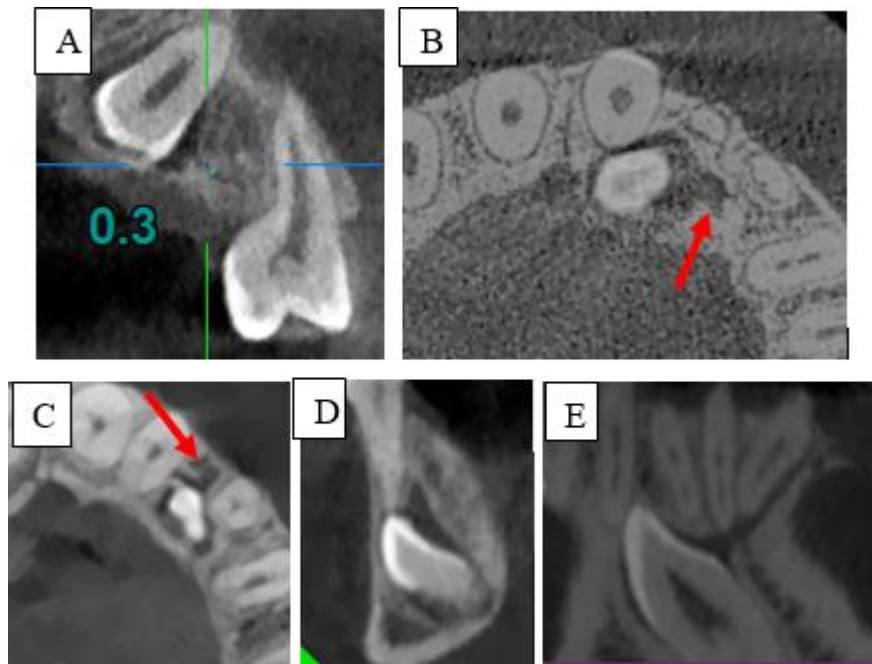


Figure 2: CBCT views show alteration in shape of GC: A: Thinning of GC (diameter <1 mm); B: Deformation; C: Folding; D: Obliteration; E: Change in direction.

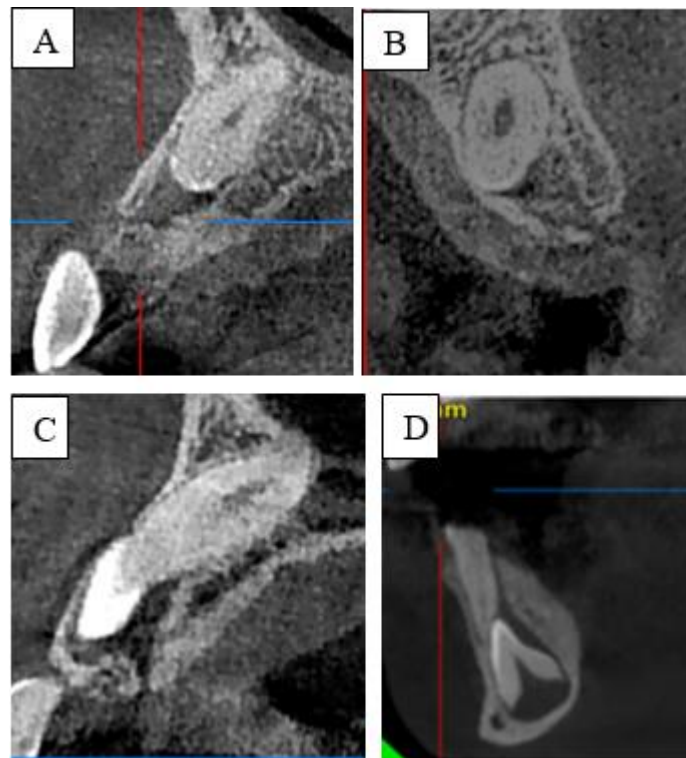


Figure 3: Opening site of GC in the alveolar crest, A: Sagittal CBCT image of buccally opened GC, B: Sagittal CBCT view of centrally opened GC, C: Sagittal CBCT view of palatally opened GC, D: Sagittal CBCT view of PDL opened GC in unerupted lower canine.

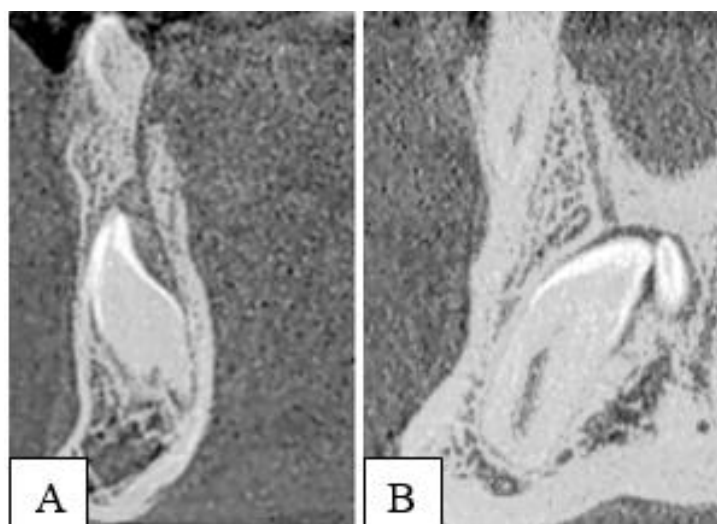


Figure 4: Sagittal CBCT view of lower canine shows the attachment site of GC to the dental follicle, A: Usual, B: Unusual.

Table 1: Number and percentage of GC according to patients' gender.

			Gender *		Total	Chi-square	P value
			Female	Male			
Detection	Not detected	Count	58	27	85	1.72	0.189 (NS)
		% Within gender	21.6%	16.5%	19.7%		
	Detected	Count	210	137	347		
		% Within gender	78.4%	83.5%	80.3%		
Total		Count	268	164	432		
		% Within detection	62.0%	38.0%	100%		

NS: Not significant (P value > 0.05).

*Number of impacted/ unerupted canine in each gender.

Table 2: Number and percentage of altered shaped GC in relation to eruption status.

Shape alteration		Eruption status		Total	Chi-square	P value
		Normal	Impacted			
Thin less than 1 mm	Count	1	13	14	18.22	0.001 (HS)
	Percentage *	20.0%	50.0%	45.2%		
Different direction	Count	0	10	10		
	Percentage	0.0%	38.5%	32.3%		
Obliteration	Count	4	1	5		
	Percentage	80.0%	3.8%	16.1%		
Deformation	Count	0	1	1		
	Percentage	0.0%	3.8%	3.2%		
Folding	Count	0	1	1		
	Percentage	0.0%	3.8%	3.2%		
Total		Count	5	26	31	
		Percentage	16.1%	83.9%	8.9% **	

HS: high significant, p value < 0.01.

* All percent is within eruption status except the last row is within shape alteration.

** Percent of altered shape GC to the total detected number (347).

Table 3: Number and percentage of opening sites of GC in impacted/ unerupted canine in relation to eruption status.

Opening site		Eruption status			Total	Chi-square	P value
		Normal	Delay	Impacted			
Buccal	Count	2	0	10	12	79.78	0.000 (HS)
	Percentage	1.8%	0.0%	5.1%	3.5%		
Central	Count	15	4	51	70		
	Percentage	13.2%	12.9%	25.9%	20.5%		
Palatal or lingual	Count	44	15	126	185		
	Percentage	38.6%	48.4%	64.0%	54.1%		
PDL *	Count	53	12	10	75		
	Percentage	46.5%	38.7%	5.1%	21.9%		
Total	Count	114	31	197	342		

HS: high significant, p value < 0.01.

* PDL: periodontal ligament of primary canine.

Table 4: Number and percentage of attachment sites of GC in relation to eruption status.

Attachment site		Eruption status			Total	Chi-square	P value
		Normal	Delay	Impacted			
Usual	Count	108	20	14	142	225.97	0.000 (HS)
	Percentage	91.5%	64.5%	7.1%	40.9%		
Unusual	Count	10	11	184	205		
	Percentage	8.5%	35.5%	92.9%	59.1%		
Total	Count	118	31	198	347		

HS: high significant (p value < 0.01).

Table 5: Number and percentage of GC detection according to eruption status.

			Eruption status			Total	Chi-square	P value
			Normal	Delay	Impacted			
Detection	Not detected	Count	5	0	80	85	41.12	0.000 (HS)
		%	4.1%	0.0%	28.8%	19.7%		
	Detected	Count	118	31	198	347		
		%	95.9%	100%	71.2%	80.3%		
Total		Count	123	31	278	432		
		%	28.5%	7.2%	64.4%	100%		

HS: highly significant difference, P value < 0.01.

References

1. Ferreira DCA, Fumes AC, Consolaro A, Nelson-Filho P, Queiroz AM, Rossi AD. Gubernacular cord and canal – does these anatomical structures play a role in dental eruption? *RSBO*. 2013;10(2):167–171.
2. Chaudhry A, and Sobti G. Imaging characteristics of Gubernacular Tract on CBCT- A pictorial review. *Oral Radiol J*. 2020; 37: 355–365.
3. Oda M, Nishida I, Miyamoto I, Habu M, Yoshiga D, Kodama M, et al. Characteristics of the gubernaculum tracts in mesiodens and maxillary anterior teeth with delayed eruption on MDCT and CBCT. *Oral Surg Oral Med Oral Pathol Oral Radiol*. 2016;122(4):511-516.
4. Rahman VF, and Fatah AA. Localization of Maxillary Impacted Canine Using Cone Beam Computed Tomography for Assessment of Angulation, Distance From Occlusal Plane, Alveolar Width and Proximity to Adjacent Teeth. *J. Baghdad Coll. Dent*. 2017; 29(1), 70-75.
5. Nishida I, Oda M, Tanaka T, Kito S, Seta Y, Yada N, et al. Detection and imaging characteristics of the gubernaculum tract in children on cone beam and multi-detector CT. *Oral Surg Oral Med Oral Pathol Oral Radiol*. 2015;120:E109–E117.
6. Gaêta-Araujo H, da Silva MB, Tirapelli C, Freitas DQ, de Oliveira-Santos C. Detection of the gubernacular canal and its attachment to the dental follicle may indicate an abnormal eruption status. *Angle Orthod*. 2019;89(5):781–787.
7. Koc N, Dogru HB, Cagirankaya LB, Dural S, Stelt PFV. CBCT assessment of gubernacular canals in relation to eruption disturbance and pathologic condition associated with impacted/ unerupted teeth. *Oral Surg Oral Med Oral Pathol Oral Radiol*. 2019;127(2):175–184.
8. Suri L, Gagari E, Vastardis H. Delayed tooth eruption: Pathogenesis, diagnosis, and treatment. A literature review. *Am J Orthod Dentofacial Orthop*. 2004;126:432-445.
9. Caldas, I.M., Carneiro, J.L., Teixeira, A., Matos, E., Afonso, A. and Magalhães, T. Chronological course of third molar eruption in a Portuguese population. *Int J Legal Med* 2012; 126: 107– 112.
10. Al-Ansari N.B., Ghaib N.H. and Al-Naimi S.H. Diagnosis and localization of the maxillary impacted canines by using dental multi-slice computed tomography 3D view and reconstructed panoramic 2D view. *J. Baghdad Coll. Dent*. 2014; 26(1), 159-165.
11. AL-Mayali AMY, Nahidh M, Alnajjar HA, Fahad AH. Impaction prevalence of permanent teeth pattern from orthodontic view. *Eurasia J Biosci*. 2020; 14: 2823-2828.
12. Ruwiae RA, Al-Ali DA, and Abid MF. A Difficulty Chart for Estimation of Treatment Duration of Palatally Impacted Canines. *Med Legal Update J*. 2020; 20(3): 1040-1046.
13. Cerqueira TS, Correia KV. Study and evaluation of the gubernacular canal by means of cone beam computed tomography. *Stomatologija*. 2020; 22(3):86-91.