



Comparison Between the Effects of Alvogyl Paste and 0.2% Chlorhexidine Gel on Postoperative Swelling Following Mandibular Third Molar Surgery

Abdul Haleem Alaa Abdul Zahra ^{(1)*}
Sahar Shakir Al-adili ⁽²⁾

^(1,2) Department of Oral & Maxillofacial Surgery, College of Dentistry, University of Baghdad, Iraq.

Keywords:

impacted third molar, swelling
Periokin®; Chlorhexidine;
Alvogyl®.

Article Info.:

Article History:

Received: 29/7/2023

Received in revised form:
6/8/2023.

Accepted: 9/8/2023

Final Proofreading: 9/8/2023

Available Online: 1/6/2024

© THIS IS AN OPEN ACCESS ARTICLE
UNDER THE CC BY LICENSE

<https://creativecommons.org/licenses/by/4.0/>



Citation: Abdul Zahra AHA, Al-adili SS. Comparison Between the Effects of Alvogyl Paste and 0.2% Chlorhexidine Gel on Postoperative Swelling Following Mandibular Third Molar Surgery. Tikrit Journal for Dental Sciences 2024; 12(1): 89-95

<https://doi.org/10.25130/tjds.12.1.9>

*Corresponding Author:

Email:

haleem_1994@yahoo.com

Tel: +964 7804856862

(1) B.D.S. University of Baghdad, College of Dentistry, Oral & Maxillofacial Surgery Department.

Abstract

Facial swelling, pain, and trismus are typical side sequelae of mandibular third molar surgery. These symptoms are all caused by tissue inflammation followed by trauma from surgery and the quality of life of these patients has been significantly impacted by these symptoms in the immediate post-operative period. Both Alvogyl and chlorhexidine bio-adhesive gel are routinely used in dental practice to reduce post-operative sequelae due to their antimicrobial and anti-inflammatory properties.

The study was set up as a randomized controlled clinical study and conducted from February 2022 to September 2022. The study involved patients 18-39 years old who sought extraction of an impacted lower third molar attending the Oral Surgery Clinic in the College of Dentistry in Baghdad. The sample was divided into three groups, the first group received Alvogyl paste following third molar surgery while the second group received periokin chlorhexidine bio-adhesive gel and the last control group didn't receive any medication.

Results of a study with 51 patients, equally assigned into two study groups and a control group, indicate that in the study groups, there was a reduction in post-operative facial swelling in comparison with the control group and the reduction was statistically significant ($P = 0.001$), and the Alvogyl paste was superior to chlorhexidine in swelling reduction but statistically not significant.

Introduction:

Impaction is the inability of a tooth to fully emerge into its final position of function within a given period of time due to a dental arch's lack of space caused by obstruction with a neighboring tooth, or the development of the tooth in an ectopic position, and the most commonly impacted teeth in the human body are the mandibular third molars (1), (2).

One of the most typical daily minor oral surgical operations is the surgical extraction of the mandibular third molar which can cause pain, swelling, and limitation in mouth opening, several factors lead to these conditions, however they originate from the inflammation that is caused by trauma of surgery (3),(4).

A variety of techniques has been used to prevent or reduce postoperative swelling, including the use of medications like corticosteroids or non-steroidal anti-inflammatory drugs, biological factors like PRF, and various closure techniques flap designs (5-7).

Alvogyl is an intra-alveolar addressing material that has been widely used in the treatment of alveolar osteitis. It is known to rapidly provide pain relief and soothing effects throughout the healing process, and known to minimize complications and swelling following the removal of the lower third molars (8).

The ingredients in Alvogyl paste include Iodoform (15.8%), an antimicrobial agent Butylparaminobenzoate (25.7%), an anesthetic, Eugenol (13.7%), which reduces inflammation and pain by blocking the activity of prostaglandins, and Penghawar (3.5%), an anti-inflammatory (9).

Chlorhexidine (CHX) is a Biguanide-derived antimicrobial agent commonly used as a topical antiseptic in dentistry. CHX has significant antibacterial effects due to its powerful dicationic and molecular form, which allows it to react with the anions. (9).

Chx demonstrates a broad antibacterial activity against gram + and gram - bacteria due to its ability to damage the interior cytoplasmic layer of bacteria, it demonstrates bacteriostatic action at low

concentrations and bactericidal action at high concentrations. It is also effective against fungi, certain viruses, and dermatophytes (10), (11).

The most popular formulation recently is a 0.2% intra-alveolar Chlorhexidine bio-adhesive gel at bactericidal concentration, that is used to prevent postoperative problems like alveolar osteitis and postoperative complications. (12).

The aim of this study is to compare the effectiveness of alvogyl paste and chx gel on facial swelling after surgery to remove an impacted lower third molar.

Materials and Methods

Patients who attended the Oral Surgery Clinic/Oral and Maxillofacial Surgery Department at the College of Dentistry Teaching Hospital/Baghdad University between February 2 and September 30, 2022, were the subjects of this randomized controlled clinical study.

Patients were informed about the procedure and informed consent was obtained from them. The research ethical committee in Baghdad University approved to this study (Protocol reference number 417121).

The study included a practical sample of patients who needed surgical extraction of impacted mandibular third molar that was either completely or partially covered by bone (Class I-II and position A-B, that is, according to Pell and Gregory's classification), and who additionally maintained adequate dental hygiene and a surgical site clean of active infection.

On the other hand, the study excluded patients with any systemic disease, a recent history of head and neck radiotherapy, pregnancy and female patients taking oral contraceptives, patients that were not capable of coming back for the follow-up visit, cystic lesions or periapical pathology related to the impacted tooth, or any interference with the inferior alveolar nerve, smokers, and patients allergic to the ingredients of alvogyl paste or chlorhexidine.

Fifty-one Patients were divided into 3 groups randomly, each group includes 17 patients: the Alvogyl group, which received Alvogyl paste in the socket

(Septodont Inc, Saint-Maur-des-Fossés, France); the chlorhexidine group, which received periokin 0.2% chlorhexidine gel in the socket (Kin Inc, Barcelona, Spain); and the control group, which received nothing after surgery.

The surgery was performed under local anesthesia using 2% lidocaine, and 1.8 ml of adrenaline, with buccal and inferior alveolar nerve blocks.

A two-sided flap was reflected, with sufficient bone removal utilizing a low-speed surgical hand-piece (15000–2000 revolutions per minute [rpm]),

This was obtained by continuous, copious irrigation with normal saline solution during the procedure.

When necessary, the tooth was sectioned into sections with a turbine handpiece and removed by elevator, which was followed by complete irrigation and removal of debris.

Either Alvogyl or Chx gel was then placed inside the socket in the study groups and suturing the flap with three interrupted sutures (3-0 braided) black silk.

The patients were instructed to take only the medication that had been prescribed for them including Augmentin® tab. 625 mg (Amoxicillin 500 mg, Clavulanic acid 125mg) every 8 hours. In case of penicillin allergic patients, they were instructed to take an Azithromycin cap. 500 mg 1 tab per day, Analgesic tablets were prescribed (paracetamol 500mg), three times per day for all groups.

The researcher used measuring tape to measure the distances between the following points to determine the amount of facial edema: the lateral canthus of the eye to the angle of the jaw, the tragus from the ear to the mouth corner, and the tragus to the soft tissue pogonion, as shown in Figure (1). The patient's facial swelling was recorded prior to surgery, on days two and seven following surgery, and an analytic comparison between the three groups was done. Version 25 of the Statistical Package for Social Sciences (SPSS) was used to analyze the data. Ranges, the standard deviation, and the mean are used to present the data. The presentation of categorical data uses percentages and frequencies. Paired t-tests and Analysis of Variance (ANOVA) (two-tailed) were used to

evaluate the continuous variables and to determine the significance of differences between different percentages (qualitative data). To compare both study groups, the post hoc test (LSD) was utilized as a multiple comparison test. P values of less than 0.05 were regarded as significant levels.

Results

A study on 51 patients with surgical extraction of impacted mandibular 3rd molar showed that the percentage extent of swelling in the control group exhibited a **statistically significant** increase in the swelling in the 2nd and 7th postoperative days compared with the chx and alvogyl groups (6.38 vs 4.18 and 3.72, P= 0.001) and (1.51 vs 1.04 and 0.74, P= 0.001) respectively, and alvogyl group showed less swelling than chx group but statistically not significant as shown in Table (1).

Between the study and control groups, there was no statistically significant difference in any of the other study variables, such as age, gender, and surgical difficulty. The ages of the patients ranged from 18 to 39 years, with a mean age of 25.69 years and an SD of 4.84 years. The majority of study participants were between the ages of 18 and 25. Of these, 47.1% were assigned to the alvogyl group, 52.9% to the chlorhexidine group, and 52.9% to the control group, as shown in Table (2). Regarding gender, the proportion of females was higher than males in this study (54.9% versus 45.1%), as shown in Table (3). The surgical procedures were of mild difficulty in most of the studied patients and the rest were of moderate difficulty (68.6% vs. 31.4%). in which 58.8% of the alvogyl group, 82.4% of the chlorhexidine group, and 64.7% of the controls, as shown in Table (4).

Discussion

After the extraction of the third molar, a variety of methods have been utilized to prevent or lessen postoperative swelling. Numerous clinical researchers have suggested using oral mouthwashes, socket

packing, intra-alveolar medication or antibiotic dressing, systemic antibiotics, ointments, and other treatments. None of these techniques completely remove postoperative facial edema or without their own morbidities.

Swelling analysis showed that the percentage of increased swelling was less in the study groups than control group in the first follow-up (p-value =0.001) and in the second follow up the (p-value =0.008) and the difference was statistically significant, and the alvogyl being superior to chx in reduction of facial edema but statistically not significant.

Maximum face edema was seen in all groups in this study on the second postoperative day, after which it gradually subsided. This is consistent with (13) who claimed that face edema is a direct outcome of surgical trauma to the investing tissues of the impacted third molar region. The symptoms begin gradually, peak after 24 to 48 hours, and sometimes last up to 7 days.

Both alvogyl and chlorhexidine appear to have anti-inflammatory properties. The significant difference in facial swelling reduction in the alvogyl group can be attributed to the actual fact that eugenol exhibits anti-inflammatory action by preventing prostaglandin production by lowering the levels of expression of inflammatory markers COX-2, iNOS, and cytokine tumor necrosis factor (TNF-), as well as antioxidant enzymes, Alvogyl also includes the antimicrobial agent iodoform, which has been demonstrated to have an antibacterial impact on a number of oral bacterial strains. (9) discovered that Alvogyl surpassed zinc oxide eugenol (ZOE) in quickly decreasing inflammation around the extraction socket. This is likely due to Penghawar fibers' additional anti-inflammatory action, which gives the product a firm consistency that promotes early filling of the alveolar socket and is also used as a hemostatic agent. The results of this study are consistent with those of a study by (14), which recommended regular application of eugenol-containing paste (alvogyl) following the surgical removal of the mandibular third molar. The Eugenol group outperformed the chx gel and placebo control groups not only in terms of the frequency of alveolar osteitis but also in

terms of lowering the levels of pain, infection, inflammation, and facial swelling. Regarding chx gel, the information provided by (15) shows that its application post-extraction results in a considerable decrease in post-operative edema and trismus thanks to its antimicrobial activity, which lowers the number of bacteria at the surgical site. Chlorhexidine bioadhesive gel anti-inflammatory effect can be attributed to its antiseptic quality that reduces the microbial population in the surgical site and thus inflammatory mediators that are produced as a result of bacterial activity are also reduced, thereby the painful inflammatory response is reduced (15). The results of this study were in agreement with those of a study by (16),(17) which discovered that a topical gel comprising 0.2% chlorhexidine, chitosan, allantoin, and dexpanthenol significantly reduced postoperative inflammation and edema when compared to the use of a placebo. Additionally, the experimental group exhibits enhanced wound-healing abilities. And supports a study by (18) that discovered a considerable decrease in facial edema and trismus post-operatively in patients who had intra alveolar chx gel inserted (i.e., measurements that were almost the same as pre-operative values). Finally, the application of alvogyl paste or chx bio-adhesive gel showed promising effects following third molar surgery, however larger sample size and standardization of impaction type is needed to prove its true efficacy.

Conclusions

This randomized controlled study aims to compare Alvogyl and 0.2% chlorhexidine bio-adhesive gel in reducing facial swelling following impacted third molar surgery and found that Alvogyl and chlorhexidine gel significantly reduce postoperative edema compared to the control group, and Alvogyl being superior to chlorhexidine gel in swelling reduction, however, no statistically significant difference was found between Alvogyl and chlorhexidine gel groups.

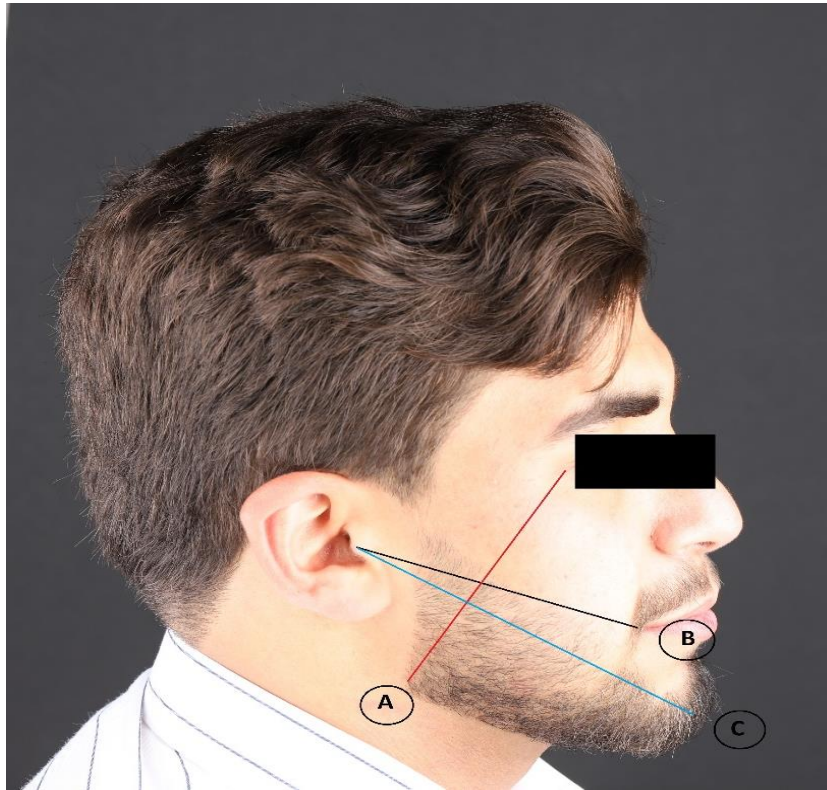


Figure 1: measurement lines of facial swelling.

Table 1: Comparison between study groups by the extent of swelling in the 2nd and 7th postoperative days

Extent of Swelling (%)	Study Groups			F	P- Value*
	Alvogyl Group Mean ± SD	CHX Group Mean ± SD	Control Group Mean ± SD		
2 Days Postoperatively	3.72 ± 2.05	4.18 ± 1.55	6.38 ± 2.24	8.84	0.001 S
7 Days Postoperatively	0.74 ± 0.63	1.04 ± 0.61	1.51 ± 0.82	5.27	0.008 S

Table 2: Distribution of the study groups according to age.

Age (Years)	Study Groups			P- Value*
	Alvogyl Group n= 17	CHX Group n= 17	Control Group n= 17	
18 - 25	8 (47.1)	9 (52.9)	9 (52.9)	0.238
25 - 29	2 (11.7)	6 (35.3)	5 (29.4)	
≥ 30	7 (41.2)	2 (11.7)	3 (17.7)	

Table 3: Distribution of the study groups according to gender

Gender	Study Groups			P- Value*
	Alvogyl Group n= 17	CHX Group n= 17	Control Group n= 17	
Male	7 (41.2)	7 (41.2)	9 (52.9)	0.728
Female	10 (58.8)	10 (58.8)	8 (47.1)	

Table 4: Distribution of study groups according to time and difficulty of extractions

Time & Difficulty	Study Groups			P- Value
	Alvogyl Group n= 17	CHX Group n= 17	Control Group n= 17	
Extraction Difficulty				
Mild	10 (58.8)	14 (82.4)	11 (64.7)	0.306
Moderate	7 (41.2)	3 (17.6)	6 (35.3)	

References

1. Abu-Hussein M, Watted N, Watted A, Abu-Hussein Y, Yehia M, Awadi O, et al. Prevalence of tooth agenesis in orthodontic patients at Arab population in Israel. prevalence. 2015;13:15.
2. Hasan LS, Ahmad FT, Abdullah EH. Impacted wisdom teeth, prevalence, pattern of impaction, complications and indication for extraction: A pilot clinic study in Iraqi population. studies. 2016;5(6):7-8.
3. Hadi ZW, Al-Adili SS. The Effect of Submucous Dexamethasone Injection on the Post-Operative Sequelae After Impacted Third Molar Surgery. Indian Journal of Public Health Research & Development. 2020;11(2).
4. Mubarak HA, Al-Adily SS. A Randomized Case-controlled Clinical Trial of the Effect of Preemptive Etoricoxib, Prednisolone and a Control Group on of Postoperative Sequelae after Surgical Removal of Impacted Mandibular Third Molars. Medico-Legal Update. 2021;21(2).
5. Isola G, Matarese M, Ramaglia L, Cicciù M, Matarese G. Evaluation of the efficacy of celecoxib and ibuprofen on postoperative pain, swelling, and mouth opening after surgical removal of impacted third molars: A randomized, controlled clinical trial. International Journal of Oral and Maxillofacial Surgery. 2019;48(10):1348-54.
6. Trybek G, Rydlińska J, Aniko-Włodarczyk M, Jaroń A. Effect of platelet-rich fibrin application on non-infectious complications after surgical extraction of impacted mandibular third molars. International Journal of Environmental Research and Public Health. 2021;18(16):8249.

7. Alkadi S, Stassen L. Effect of one-suture and sutureless techniques on postoperative healing after third molar surgery. *Journal of Oral and Maxillofacial Surgery*. 2019;77(4):703. e1-. e16.
8. Keshini M, Shetty SK, Sundar S, Chandan S, Manjula S. Assessment of healing using alvogyl and platelet-rich fibrin in patients with dry socket-An evaluative study. *Annals of Maxillofacial Surgery*. 2020;10(2):320.
9. Yadav A, Kumar A, Agrawal S, Malik R, Mandal TK, Ahmed S. A comparative study of Alvogyl and ZOE in dry socket syndrome. *IOSR J Dent Med Sci*. 2019;18:68-75.
10. Łukomska-Szymańska M, Sokołowski J, Łapińska B. Chlorhexidine—mechanism of action and its application to dentistry. *Journal of Stomatology*. 2017;70(4):405-417.
11. Abdulazeez MI. Clinical Study on the Effect of Sodium Fluoride Mouthrinse/Gel and Toothpaste in Combination with Chlorhexidine Mouth Wash on Plaque and Gingivitis in Orthodontic Patients. *Tikrit Journal for Dental Sciences*. 2011;1(1).
12. Muñoz-Cámara D, Pardo-Zamora G, Camacho-Alonso F. Postoperative effects of intra-alveolar application of 0.2% chlorhexidine or 1% hyaluronic acid bioadhesive gels after mandibular third molar extraction: a double-blind randomized controlled clinical trial. *Clinical oral investigations*. 2021;25(2):617-25.
13. Patil C, Jadhav A, Rajanikanth K, Bholá N, Borle RM, Mishra A. Piezosurgery vs bur in impacted mandibular third molar surgery: Evaluation of postoperative sequelae. *Journal of Oral Biology and Craniofacial Research*. 2019;9(3):259-262.
14. Jesudasan JS, Wahab PA, Sekhar MM. Effectiveness of 0.2% chlorhexidine gel and a eugenol-based paste on postoperative alveolar osteitis in patients having third molars extracted: a randomised controlled clinical trial. *British Journal of Oral and Maxillofacial Surgery*. 2015;53(9):826-830.
15. Requena-Calla S, Funes-Rumiche I. Effectiveness of intra-alveolar chlorhexidine gel in reducing dry socket following surgical extraction of lower third molars. A pilot study. *Journal of clinical and experimental dentistry*. 2016;8(2):e160.
16. Madrazo-Jiménez M, Rodríguez-Caballero Á, Serrera-Figallo M-Á, Garrido-Serrano R, Gutiérrez-Corrales A, Gutiérrez-Pérez J-L, et al. The effects of a topical gel containing chitosan, 0, 2% chlorhexidine, allantoin and dexpanthenol on the wound healing process subsequent to impacted lower third molar extraction. *Medicina oral, patología oral y cirugía bucal*. 2016;21(6):e696.
17. Sáez-Alcaide LM, Molinero-Mourelle P, González-Serrano J, Rubio-Alonso L, Bornstein MM, López-Quiles J. Efficacy of a topical gel containing chitosan, chlorhexidine, allantoin and dexpanthenol for pain and inflammation control after third molar surgery: A randomized and placebo-controlled clinical trial. *Medicina oral, patología oral y cirugía bucal*. 2020;25(5):e644.
18. Inamdar MN, Chauhan R, Mapare SA, Goswami RP, Goswami Y, Khadri SF. Prevention of dry socket using chlorhexidine gel and ornidazole gel in impacted mandibular third molar: a comparative randomized prospective study on 30 patients. *Journal of International Oral Health*. 2015;7(11):41.