



## Prevalence of Cusp of Carabelli in Upper First Molars in Salahdin Governate and Its Caries Susptability

Areej Salim Al-Azzawi <sup>(1) \*</sup>

Fatima Gazi Aswad <sup>(2)</sup>

Ataa Kamil Rasheed <sup>(3)</sup>

Malak Amer Abdulrazak <sup>(4)</sup>

Fatima Abbas Ibrahim <sup>(5)</sup>

<sup>(1,2)</sup> Department of Oral Diagnosis, Tikrit Collage of Dentistry, Tikrit, Iraq.

### Keywords:

cusp of Carabelli, dental caries, first molar

### Article Info.:

#### Article History:

Received: 10/8/2023

Received in revised form:  
16/8/2023.

Accepted: 10/9/2023

Final Proofreading: 10/9/2023

Available Online: 1/6/2024

© THIS IS AN OPEN ACCESS ARTICLE  
UNDER THE CC BY LICENSE

<https://creativecommons.org/licenses/by/4.0/>



**Citation:** Al-Azzawi AS, Aswad FG, Rasheed AK, Abdulrazak MA, Ibrahim FA. Prevalence of Cusp of Carabelli in Upper First Molars in Salahdin Governate and Its Caries Susptability. *Tikrit Journal for Dental Sciences* 2024; 12(1): 172-178.

<https://doi.org/10.25130/tjds.12.1.19>

### \*Corresponding Author:

#### Email:

areej\_salim@tu.edu.iq

fatimagaswad@tu.edu.iq

(1) B.D.S., McS Department of Oral Diagnosis, College of Dentistry, University of Tikrit, Iraq

### Abstract

This study was performed to measure distribution of different types of Carabelli cusps among population and relationship of each cusp type with dental caries.

Method: this study included the examination of 200 patients for both right and left sides, to find the distribution of Carabelli cusp and their caries susptability. Patients with severe destructed or extracted upper first molar from any side were excluded.

Results: percentage of presence or appearance of prominent Carabelli cusp was approximately 23%. Groove obtained in 33% of total examined teeth. Prominent cusps showed higher rate of caries infection, while smooth surface had lower caries susptability.

Conclusion: according to the anatomical differences of mesiopalatal surface of upper first molar, Carabelli cusp prevalence was high and caries susptability was increased in positive cusp expression

## Introduction:

A personal identity, origin and gender can be determined using dental anatomic characteristics. The frequency of dental anatomical trait in a given number of people determine the significance <sup>(1)</sup>

In normal dental arches, the upper first molar is the largest tooth in the upper segment. The maxillary first molar has four functional cusps: mesiobuccal, distobuccal, mesiopalatal and distopalatal, in addition it has one supplemental cusp on the palatal surface of mesiopalatal cusp called the cusp of Carabelli. The palatal surface of upper first molar's curves outward and palatally, the crest of curvature locates at the crown's middle third <sup>(2)</sup>.

Carabelli cusp shapes ranged from well-developed cusps and graded down to a series of grooves, depressions, or pits on the mesiopalatal surface, while in some individuals Carabelli cusp is entirely absent <sup>(3)</sup>. When Carabelli cusp is well obvious, the palatal surface dips inward to reveal it. While if it is undeveloped, the palatal outline continues smoothly from the crest of curvature of palatal surface to the tip of the mesiopalatal cusp <sup>(2)</sup>.

The cusp of Carabelli ranges in size from being the largest cusp of the upper first molar to a very simple elevation. When the cusp of Carabelli is well developed, its well be outlined with a developmental groove which called (Carabelli cusp groove) that's joins the end of palatal groove <sup>(4)</sup>.

In 1963 Dahlberg develop a classification scale for the development degree of Carabelli cusp. The scale numerated from (0) to (7), the (0) degree refer to smooth mesiopalatal surface, while (7) indicate large cusp as described figure (1) <sup>(5)</sup>

Dental hard tissue become demineralized and remineralized in the deep points of the pits and grooves, leading to dental caries, which is biofilm-mediated, sugar-driven, multifactorial disease <sup>(6)</sup>

Deep Carabelli cusp groove has high risk of developing dental caries because the groove act as a potential plaque-retentive area. For that reason, sealant must be applied to both the positive and negative expressions of Cusp of Carabelli <sup>(7)</sup>.

Because Carabelli cusp located on palatal surface of the posterior teeth, it is not easy

to be cleaned by the toothbrush. In addition, the large Carabelli cusp may prevent the tongue from cleaning the groove by acting as a physical barrier <sup>(8)</sup>.

During orthodontic treatment, a large special band must be used on the upper first molars to accommodate the large cusp of Carabelli, sometimes these bands may fit loosely creating a gap between the tooth and the band, this facilitates food and plaque accumulation result in dental caries and periodontal diseases in this area <sup>(9)</sup>.

Management of carious lesions depends on the extent and severity of dental caries <sup>(10)</sup>.

## Material and Method

This subject was conducted from 200 person at Tikrit university of 14 years or above were examined. 13 patients with heavy destroyed or missing teeth from one or both sides were excluded. Baseline data for patients were obtained from clinical examination there information were arrange in table including name ,type of mesiopalatal surface (smooth, groove, prominence) and present of caries or not.

Occlusal surface of upper first molars on both right and left sides were carefully examined by dental mirror and probe, under adequate light, presence of Carabelli cusp was identified by pulling the probe tip over the groove created by cusp looking for stickiness and avoiding apically directed force.

## Results

### Prevalence of the Cusp of Carabelli

Descriptive statistics illustrated in table (1) reveal that 23% of exanimated upper first molars had prominent cusp on the mesiopalatal surface. Figure (2). 10% had distributed bilaterally while 13% had unilateral distribution.

The upper first molars that had groove on the mesiopalatal percent was 33% of total examined teeth, 13% distributed unilaterally and 20% had bilateral distribution, Figure (3).

The percentage of smooth mesiopalatal surface of examined upper first molars was 44%, distribution counted 13% unilaterally and 31% bilaterally. Figure (4).

### **Caries distribution**

Table (2) describes the percentage of upper first molars infected with caries on their mesiopalatal surface, prominent cusps show the highest percent of caries distribution (22% of total number), while 10% of total number of grooves were infected with caries. The smooth surface shows least present of caries distribution (4% of total number of smooth surface).

### **Discussion**

Carabelli cusp is a sort of attachment cusp, mostly seen in permanent upper first molar, an etiology is unknown. The shape and size of this cusp have wide variations, its composed of enamel with or without pulpal and dentinal extension (Sedano, et al. 2009)<sup>(11)</sup>. It's have many names such as tubercle of Carabelli, trait of Carabelli, fifth cusp, mesiopalatal prominence or molar tubercle (Kamatham & Nuvvula, 2014)<sup>(12)</sup>.

In this, the prevalence of the cusp of Carabelli in upper first molars was examined as well as its caries susceptibility in population of Salahdin. It had been obtained that 44% of the exanimated teeth had smooth surface with no cusp or groove, while upper first molars showed positive expression of Carabelli cusp were count 56% ranging from shallow groove (33%) to well prominent cusp (23%) this finding agree with (Sadeeq BI and Abdulla AG, 2020)<sup>(3)</sup> Who gave conclusion that a large majority of Salahdin- Tikrit population (59.5%) had positive expression of Carabelli trait. Also, it agree with (Kaviani, et al. 2013) who suppose that 61% of patients denoted to the dental school of Islamic Azad University of Tehran had prominent cusps<sup>(13)</sup>. Proximity of results may referred to the geographical proximity of these countries.

Finding of this study disagree with (Falomo, 2002)<sup>(7)</sup> who study prevalence of the cusp of Carabelli on Nigerian population and found that only 17.43% of the selected people had positive Carabelli cusp, also its disagree with (Khan et al, 2011)<sup>(9)</sup> who found that 29.7% of the study population in Pakistan had Carabelli cusps on their first molars.

Morphologic variation of the teeth is important for anthropological and forensic

point of view, findings form different studies showed wide variation of the expression of groove type of Carabelli, in this research the result show 33% expression of groove obtained in students of Tikrit university. This finding agree with (Shaweesh 2012)<sup>(14)</sup> who found that 38% of Jordanian population have positive groove n their mesiopalatal surface.

Unilateral presence of cusp of Carabelli in the upper first molar was noticed in (23%) ranging from prominent cusp to shallow groove of total examined teeth, while bilateral presence of cusp was noticed (33%) in university of Tikrit. this does not correspond to the prevalence cusp of Carabelli in Mardan Pakistan<sup>(9)</sup> which show unilateral presence of cusp in 32% and bilateral presence cusp was noticed in (73.3%) of total case in Nepalese population.

Also in this study caries susptability of mesiopalatal surface of upper first molar was examined, it had been found that highest present of caries obtained in prominent cusps about 22%, while in grooves 10% were infected with caries and only 4% of smooth surfaces were attacked, these finding agree with (Shethri, 2011)<sup>(8)</sup> who found that prominent cusps of Carabelli had the higher rate of caries occurrence, it was 4 times more that in smooth mesiopalatal surface.

Caries development occur more in prominent cusps due more palatal position of the cusp, make it difficult to be cleaned by the toothbrush In addition the large Carabelli cusp may prevent the tongue from cleaning the groove by acting as a physical barrier, ability of Carabelli cusp for food stagnation and derbies retention, this explain reason of increase percent of caries attack in prominent cusps in this study, this finding agree with (Shethri AS.,2011)<sup>(8)</sup>.

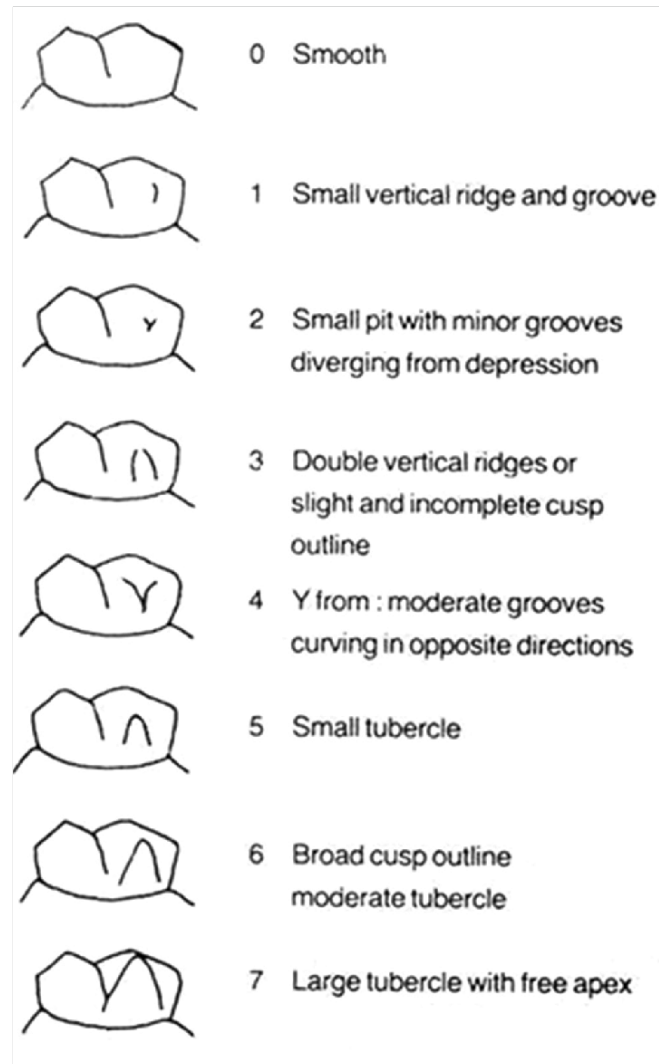


Figure (1) Dahlberg's scale (1963) that determine expression of degree of Carabelli cusps.

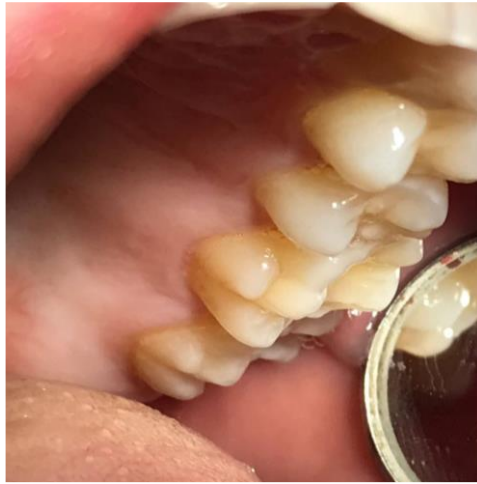

Figure (2): Maxillary first molar with prominent cusp

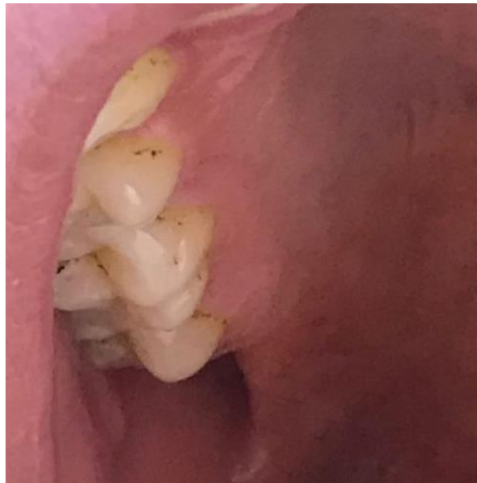

Figure (3): Maxillary first molar with groove in mesiopalatal surface.

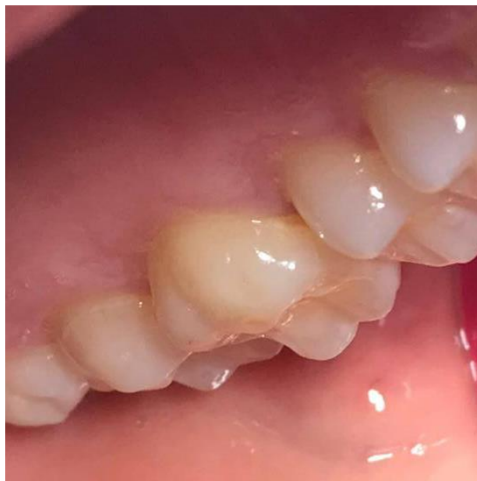

Figure (4): Maxillary first molar with smooth mesiopalatal surface.

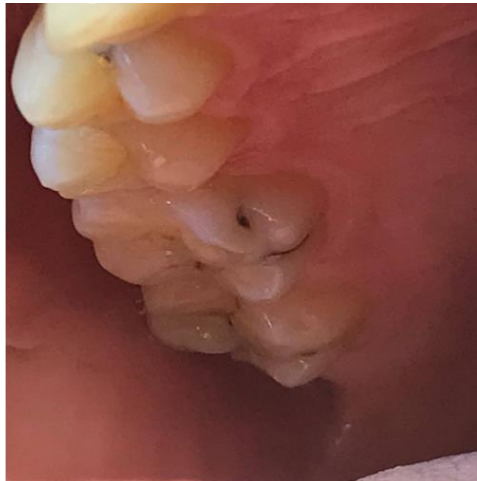

Figure (5): Prominent cusp infected with caries.

Table (1): Number and percent of cusped, grooved and smooth mesiopalatal surface

	first molars with prominent cusp	first molars with groove	first molars with smooth surface	total
<b>unilateral</b>	37 10%	48 13%	49 13%	354 100%
<b>bilateral</b>	38 13%	70 20%	112 31%	
<b>subtotal</b>	75 23%	118 33%	161 44%	354 100%

Table (2): Caries distribution in different types of mesiopalatal surface of upper first molars

	first molars with prominent cusp	first molars with groove	first molars with smooth surface
<b>Sound teeth</b>	59 78%	106 90%	155 96%
<b>Carious teeth</b>	16 22%	12 10%	6 4%
<b>total</b>	75 100%	118 100%	161 100%

## References

- (1) Simões R. J., Hugo F.V. Cardoso, Caldas I. M.. Prevalence of talon cusps in a Portuguese population: Forensic identification significance of a rare trait. *Dent Res J.* 2014, 11(1):45-48..
- (2) Stanley J. Nelson, Wheelers. *Dental anatomy, physiology and occlusion, the permanent maxillary molars*, 2015, tenth edition, (170-180) .
- (3) Sedeeq B. I. , Abdullah A. G.. Prevalence of Carabelli 's trait among Iraqi population [Salahdin-Tikrit] . *Eurasian Journal of Bioscience*, 2020, 14, 3491-3497
- (4) Subedi N., Paudel S., Sah S. and Pradhan A.. The Prevalence of the Carabelli Trait in Selected Nepalese Population Complete Peer review History, *British Journal of Medicine & Medical Research*, 2015, 7(4): 285-291.
- (5) Barry M O, Jeffrey G P, Bernard J B and David CR , Cusp of Carabelli : Observations of an Odontogenic Trait, *Dentistry: Advanced Research*, 2016, 1 (01) :2574-7347.
- (6) Fejerskov O. Nyvad.B, Kidd.E, Pathology of dental caries. *Dental caries: The disease and its clinical management*. Oxford: Wiley Blackwel. 2015, 3rd ed. 1:49-80.
- (7) Falomo OO. The Cusp of Carabelli : frequency, distribution, size and clinical significance in Nigeria. *West Afr J Med.* 2002, 21:322-4.
- (8) Shethri AS. The prevalence of the Carabelli cusp in selected Saudi population. *Saudi Dent J* 2011;2:13- 6. (P: 13-16)
- (9) Khan DB, Khan MA, Khattak M. Prevalence of CoC in permanent teeth in a group from Khyber Pakhtunkhwa, Pakistan. *Pak Oral Dent J* 2011;31:409-11. Pages 294-301
- (10) Bhavyaa R, Sujitha P, Muthu MS, Kirthiga M, Prevalence of Cusp of Carabelli and Its Caries Susceptibility – An Ambidirectional Cohort Study, *Aust Dent J.* 2020, 65(4):294-301
- (11) Sedano, H. O., Ocampo-Acosta, F., Naranjo-Corona, R. I., & Torres-Arellano, M. E. Multiple dens invaginatus, mulberry molar and conical teeth. Case report and genetic considerations. *Med Oral Patol Oral Cir Bucal*, 2009, 14(2), 69-72.
- (12) Kamatham, R., & Nuvvula, S.. Expression of Carabelli trait in children from Southern India-A cross sectional study. *Journal of Forensic Dental Sciences*, 2014 6(1), 51
- (13) Kaviani, R., Mackinejad, S. A., Rakhshan, V., & Falsafi, M. . Evaluating prevalence of talon and Carabelli 's cusps in tooth examination of patients referred to Dental School of Islamic Azad University of Tehran: A 2-year study. *Isfahan Dent Sch* 2014; 9(6): 551-57 *Journal of BioSciences, Eurasia J Biosci* 14, 3491-3497 (2020)
- (14) Shaweesh, A. Expression of Carabelli 's trait in the Jordanian population. *J. Stomat. Occ. Med.* 5, 77–82 (2012).