



## Distribution of Misdiagnostic Maxillofacial Nonmalignant Lesions and Conditions in Salah Alden Government

Noori Ali Tuma

Head of maxillofacial department - Salah Alden general hospital-ministry of health-Tikrit-Iraq.

### Article Info:

**-Article History:**

**-Received:** 30/8/2020

**-Accepted:** 18/11/2020

**-Available Online:**

Dec, 2020

**Keywords:** Destitution  
Misdiagnosis, maxillofacial,  
nonmalignant lesions&  
conditions.

### Corresponding Author:

**Name:** Noori Ali Tuma

**E-mail:**

nowri98@gmail.com

**Tel:** 07701975920

### Affiliation:

B.D.S. FIBMS, Head of  
maxillofacial department -  
Salah Alden general  
hospital-ministry of health-  
Tikrit-Iraq.

### Abstract

Diagnosis is the corner stone & entry to the treatment of lesions or conditions. Because misdiagnosis leads to incorrect treatment. It is very important to understand the distribution between the most common misdiagnosis nonmalignant lesions& conditions in the maxillofacial region as apart of whole misdiagnosis. Decrease patient complaining. Evaluate the most common misdiagnosis lesions& conditions in maxillofacial region. Decrease load to hospitals& clinics& decrease infections. The data collected by standardized formula for all patients& different patient clinical, radiological examination & methods used to confirm the diagnosis. Total no. are 30 patients, misdiagnosis lesions& conditions 13% (Sinusitis or dental pain), 20% (submandibular Lymphadenitis. or Sialadenitis), 20% (Otagia). 10%(Psychopath),10%(Trigeminal neuralgia),7%(migraine) ,7%( maxillary sinusitis),13%(submandibular saialidinitis). the true diagnosis was 13%,( Oroantral fistula),20%(oro-Cutaneous fistula),20%(Tmj pain),10%(Tmj dislocation),10%(dental pain),7%(dental pain),7%(Maxillary sinus cyst),13%(submandibular Salivary gland stone). The more unorganized medical &or surgical branches interference within region may lead to these misdiagnosis results. Poor educated patients, doctor's decision with inadequate examination& investigation participate in increase patients complaining.

### Introduction:

Misdiagnosis, a determination that a person has a specific disease or disorder, when in fact they have a different one <sup>(1)</sup> Diagnosis is the method of assessing patient's health as well as the subsequent opinions formulated by the clinician. Oral diagnosis is the art of using scientific knowledge to identify oral disease

processes and to distinguish one disease from another <sup>(2)</sup> occasionally; the diagnostician presented with a sign or a symptom that is pathognomonic for one specific disease. The diagnosis process is brief in such a case; the diagnostician merely compares the symptom with a mental file of disease presentations and

chooses the only disease with that symptom. Typically, however, the diagnostic process is more complicated. The formulation of a diagnosis results from a process. The amount of data gathered from the evaluation and the background of the patient could seem daunting, but when this data used correctly in the diagnostic process, it contributes to the diagnosis or remedy. The first step in the diagnostic process sequence is the compilation of particular bits of information about a person, often referred to as the baseline information. A routine sequence helps in this process, as in the analysis. In reality, the diagnostic process sometimes called the sequence of diagnosis. Ability in the diagnostic phase requires continuous learning, from the dental student's initial clinical experience to the most experienced dental practitioner<sup>(3)</sup>. A misdiagnosis describes a case where your doctor advises you that you have a certain disorder or disease, but it is incorrect<sup>(4)</sup>. A medicinal complication, or medical complication, is an adverse consequence of an illness, state of health, or care. The prognosis, or outcome, of a disease may adversely affected by complications.<sup>(5)</sup> Dispensing. The geographical distribution of a disease or complications. Oroantral Fistula & Dental Cutaneous Fistulae. A fistula is an irregular passage, contact between, or leading from an inner organ to the surface of the body or between two internal organs. In the formation of a fistula, different pathologic conditions are involved. Odontogenic infections such as periapical abscesses, extreme periodontitis and pericoronitis are common causes of fistulas in the oral and maxillofacial regions. Periimplantitis, osteomyelitis and osteoradionecrosis of the jaw, actinomycosis, post-extraction infection, traumatic infection, and surgical wound (surgical site infection) are additional etiologies. A fistula can also contain non-infective entities such as diseases of the salivary gland, oral malignant tumor, and iatrogenic induced Oroantral contact. The clinical characteristics and treatment of these fistulas linked to odontogenic infections (dental fistulas) discussed in this section. Dental fistulae are also

referred to as dental sinus tracts developed in the mouth are internal dental fistulae, and those formed on the face skin surface are referred to as cutaneous dental fistulae or extra oral dental fistulae (cutaneous dental sinus tracts) A fistula consists of granulation and/or epithelial tissues in terms of pathological characteristics<sup>(6)</sup>. TMJ & dental pain as "an uncomfortable sensory and emotional experience associated with, or defined in terms of, actual or possible tissue damage"<sup>(7)</sup>. Dislocation of TMJ (Condylar dislocation). A hypermobility state of the jaw is condylar dislocation or open lock. This happens when, during jaw opening or protrusion, the condyle is unintentionally located anterior and superior to the articular eminence, and cannot return to a closed position. It caused by trauma, prolonged opening times of the mouth, such as a lengthy dental appointment, or may be a symptom of joint hypermobility. This condition involves manually distracting the condyle below the crest of the articular eminence, so that the condyle may return freely to a closed location in the fossa. If a health professional needs to minimize the anteriorly located condyle, it called an open lock or dislocation. This same condition referred to as subluxation when the patient is able to return the jaw to a closed position to self-manipulate<sup>(8)</sup>. Sinus cyst maxillary. Cysts within the maxilla<sup>(9)</sup> may occupy the maxillary sinus Rock with salivary gland. Salivary duct stones are masses of crystallized minerals developed in the tubes through which saliva passes after it produced in the salivary glands. A disorder referred to as Sialolithiasis. The stone also referred to as the calculus of the salivary duct, occurs mostly in middle-aged adults. According to those I collected data from the patient and did this research, it is the most common cause of blockage in the salivary ducts<sup>(10)</sup>. Drugs or physiotherapy without other forms of care, such as surgical interference or prostheses, needed for the treatment of such cases, for those patients who mainly treated by instruction.

**Aims of the study:**

1. Decrease patient complaining.

2. Evaluate the most common misdiagnosis complication conditions in maxillofacial region.
3. Decrease load to hospitals& clinics. Decrease contamination& infections.

**Patients& Method:**

Across sectional study with a sample of 30 patients complaining of misdiagnosis maxillofacial nonmalignant lesions and conditions, this study done in Salah Alden government, from the period of October 2018 to October 2019. The data obtained from patients attending maxillofacial clinic. All information’s taken depend on patients or relative words, what doctors told them about their condition& the treatments with the patients given by doctors. Clinical examination, x-rays & investigations done to confirm or exclude patients says. All patients fully examined clinically & radiologically as fallow. Insertion periodontal prop through the fistula into the maxillary sinus, OPG reveal continuous radiolucency to the maxillary sinus in (oro antral fistula) cases Insertion of periodontal prop through the fistula to the bone, periapical X ray&, OPG reveal continuous radiolucency to the fistula in cases Oro-Cutaneous fistula. Pain pre auricular area by palpation & OPG reveal abnormal condylar surface with multiple teeth lost in cases of TMJ pain .Patient cannot close his mouth, difficult speech & swallowing, OPG reveal abnormal condylar position anterior to the eminence, in cases of TMJ dislocation. Pain with propping & periapical x-ray reveal continuous radiolucency of caries to the pulp in cases of dental pain as migraine. Pain with propping & periapical x-ray reveal continuous radiolucency of caries to the pulp in cases of dental pain as ITN. The x-rays reaves well defined radiolucency increase the sinus size, comparison with the other side& fluid content by fine needle aspiration in cases of Maxillary sinus cyst. Periapical film in occlusal position & the x-ray beam sub mentally reveal salivary gland stone & ultra sound for the gland these steps to obtain the true diagnosis. In cases of submandibular Salivary gland stone.

The standardized formula for all patients (Case sheet).

Pt name - Age - gender- Residence - occupation- Chief complaint -History of complaining

| Missed diagnosis criteria. | yes | No | Total no |
|----------------------------|-----|----|----------|
| 1. history                 |     |    |          |
| 2. clinical examination    |     |    |          |
| 3. general Investigation   |     |    |          |
| 4. specific Investigation  |     |    |          |
| 5. Inform diagnosis.       |     |    |          |
| 6. write diagnosis         |     |    |          |
| 7. Referral                |     |    |          |
| 8. consultation            |     |    |          |

| Past treatment history.      | Yes | No | Total no |
|------------------------------|-----|----|----------|
| 1. Instructions.             |     |    |          |
| 2. Physiotherapy             |     |    |          |
| 3. Antibiotics & analgesics. |     |    |          |
| 4. Analgesics.               |     |    |          |
| 5. Surgical interference     |     |    |          |

Past medical history.  
 Clinical examination.  
 Extra oral. Intra oral.  
 Investigation.  
 General.  
 Local. Radiological .U/S  
 laboratory  
 Diagnosis. .Treatment.  
 Fallow up.

**Results:**

The result was the total no. are 30 patients, 15 male & 15 female (50%) for each as in Table (1) & Fig. (1). According to age groups the result of patient was two patient (0-10year), three patient (10-20), 15 patient (20-30), 6 patient (30-40), 2 patient (40-50), 2 patient (50-60) as in Table (2) Fig.(2).From Table (3) Fig.(3) Misdiagnosis criteria, Can see that all patient susceptible to history & clinical examination. General investigation (20patient do, 10 not).specific investigation (8patient do, 22 not). All

patients informed about the diagnosis but no diagnosis written for all of them. (25) Patient not referred, five referred. (23) With no consultation, seven with consultation. Past history of treatment as in Table (4) Fig. (4) Instructions for all (30), Physiotherapy for (9 patient, 21 without). Antibiotics & analgesics for (25 patient, 5 without). Analgesics for (20 patient, 10 without) Surgical interference for (5 patient, 25 without). The patients no. misdiagnosis complication conditions. 4, (maxillary Sinusitis or dental pain) (13%). 6, (submandibular Lymphadenitis or Sialadenitis) (20%). 6, (Otalgia) (20%). 3, (psychopath) (10%). 3, (Trigeminal neuralgia) (10%). 2, (migraine) (7%). 2, (maxillary sinusitis) (7%). 4, (submandibular sialadenitis) (13%). As in Table (5) Fig. (5). the patient no. True diagnosis conditions. 4, (Oroantral fistula) (13%), 6, (oro-cutaneous fistula) (20%). 6, (Tmj pain) (20%). 3, (Tmj dislocation), (10%) 3, (dental pain) (10%). 2, (dental pain) (7%). 2, (Maxillary-sinus cyst) (7%). 4, (submandibular Salivary gland stone) (13%). As in Table (6) fig. (6). Table (7) show no. of patient for each misdiagnosis complication vs true one. Later on many Digital photograph & x-rays for patients who are complaining of misdiagnosis at the end as Fig (2-1, 2, 3, 4, 5, 6).

## Discussion:

Misdiagnosis occur in any site of maxillofacial region but distribution to these sites differ in this study. Various reasons why misdiagnosis occurs, to understand why these results occur in our government this study reveals. Misdiagnosis Oroantral fistula as (sinusitis). This study agree with Akhlaghi, F., Esmaelinejad<sup>(11)</sup>. OAF is a natural cause of odontogenic maxillary sinusitis and readily treated by endoscopy and closure of the fistula. To avoid misdiagnosis and prevent complications, maxillofacial surgeons and dentists should consider this issue. Misdiagnosis of Orocutaneous fistula as Lymphadenitis or Sialadenitis submandibular this study agree. Pandey, Rajeev, et al<sup>(12)</sup>.

Orocutaneous odontogenic lesions are rare and may often imitated as dermatological lesions. They are typically misdiagnosed and, therefore, delayed care leads to chronic injury and fistula enlargement and bone loss. For proper diagnosis and care, these cases require multi-specialty consultation. A case series of oro-cutaneous fistulae mentioned here, due to misdiagnosis, the treatment made was wrong, leading to lesion enlargement along with bony defect and tooth loss. Misdiagnosis (TMJ pain) as earache (otalgia) this agree with Kim, D. S., et al<sup>(13)</sup>. Secondary or referred otalgia will present the otolaryngologist with a diagnostic challenge. The differential diagnosis is long and, while the diagnosis can, identified by a detailed history and review, dental causes of referred otalgia may ignored. Indeed, up to 50 percent of all cases referred to the ENT clinic may account for secondary otalgia due to dental disorders. This can, in part, due to a lack of dental diagnostic skills. Complete oral cavity inspection, and dentition in particular, is a skill learned by formal training, as acquired through the course of the dental degree, and taught to a much lesser extent in formal medical training. (Dislocation of TMJ) as psychopathy, this study agree with Marbach, J. J., & Lund, P<sup>(14)</sup>. That say Depression, anhedonia and anxiety in temporomandibular joint and other facial pain syndromes. Misdiagnosis (dental pain) as migraine, this study agree with Mehta, Sujay A., Joel B. Epstein<sup>(15)</sup> Toothache, that is, is probably the most common type of headache. Treatment of non-odontogenic headache patients requires understanding of contributing factors, as well as knowledge of the medical management of these specific, often non-operative, pain conditions. For initial triage and referral, experience with common types of headache and nondental facial pain is important. Orofacial pain may lead to the problem of headache, and as a result, some sort of team management may be required to overcome some forms of headache or orofacial pain involving both dentists and doctors. There may be multiple pain problems with multiple causes in people with pain lasting 6 months or longer. Further examination

may involve pain that occurs without visible signs of oral or facial anomalies. Because of the complicated nature of non-odontogenic headache diagnosis and medical treatment, referral to experienced physicians is always necessary. Misdiagnosis (dental pain) as trigeminal neuralgia, this study agree with Silvia Regina Dowgan Tesseroli de Siqueira<sup>(16)</sup> That said, their clinical appearance and position are often very close to toothache, despite the usual characteristics of ITN. Other factors leading to misdiagnosis are the referral of ITN pain to the teeth, the difficulty and variability of their orofacial appearance, the low frequency of ITN, and the limited clinical experience of dentists and doctors with this particular neuralgia. Often the cavities not shown. Maxillary cyst of the sinus as sinusitis. This study agree with Kaya, Ömer, and Önder Bocutoğlu<sup>(17)</sup>. That fix a misdiagnosed giant dentigerous cyst involving the maxillary antrum and affecting the orbit. Misdiagnosis Salivary gland stone as Sialadenitis this study agree with Mehanna, Hisham, et al.<sup>(18)</sup> Parotid and submandibular gland swellings are often mistaken for cervical lymphadenopathy because of their anatomical location, as described in Salivary gland swellings. In addition, chronic Sialadenitis may misdiagnosed as salivary neoplasms, resulting in diagnostic delay. The more age group affected is (20-30 year) this group more active so it will more susceptible for complaining. Most patient have no specific investigation done. All informed the diagnosis (which was false) but without diagnosis written. Most patients need referral but not occur, most of them need consultation but some of them gain it. Most of them only take supportive measures like analgesic or antibiotic or physiotherapy or surgical interventions. The more conditions, oro-cutaneous fistula& TMJ pain, due to more than one branch of medicine deal with this area also many diseases share similar signs& symptoms. & decrease facilities for TMJ diagnosis. Other conditions may be due to inadequate investigation (OPG, MRI, and CBCT, for TMJ). (Sailography, u/s, occlusal x-ray for submandibular salivary gland), (culture& sensitivity test

for infection), (OPG, for dentition& maxillary sinus). Also, in most of cases depend on the treatment on extension of the disease & obligate the treatment of the causes. Some of the conditions due to patient neglected & poor education. Patient careless. Poor facilities, Doctors tend to order certain treatment depending on the symptoms described by the patient. Major and minor health conditions can have very similar symptoms that can sometimes confuse a doctor. Doctors will do no further testing if they believe that the condition is a minor one when in reality it was a serious problem. By doing so, a misdiagnosis and lack of treatment can result. Addition to general& special circumstances in the government, rare number of maxillofacial specialists, and all these factors could explain these results.

### **Conclusions:**

Misdiagnosis occur in any site of maxillofacial region but distribution to these sites differ according to this study. The more unorganized medical or surgical branches interference within region may lead to these complications results. Many diseases share similar signs& symptoms. & decrease facilities for TMJ diagnosis. Inadequate investigation. Treatment of extension of the disease & obligate the treatment of the causes. Patient neglected & poor education. Patient careless. Poor facilities, Major and minor health conditions have very similar symptoms sometimes confuse a doctor. Doctors will do no further testing if they believe that the condition is a minor one when in reality it was a serious problem leads to misdiagnosis.

### **Recommendation:**

Educating the patients those with chronic complaining in maxillofacial area to visit the specialist. Instruct the doctors who are dealing with this type of patients in this area to consult the maxillofacial specialist. Opening of multy consulting diagnosis clinic especially for chronic complaining nonmalignant conditions in each government. Provide the hospitals by maxillofacial facilities needed. Writing the diagnosis on the treatment paper.

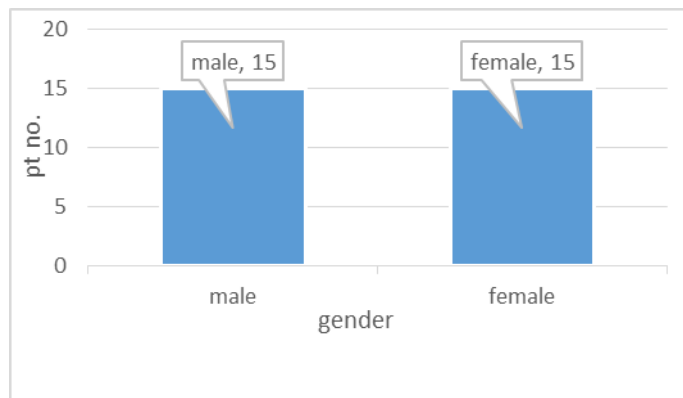


Fig.(1):- Distribution of patients according to gender.

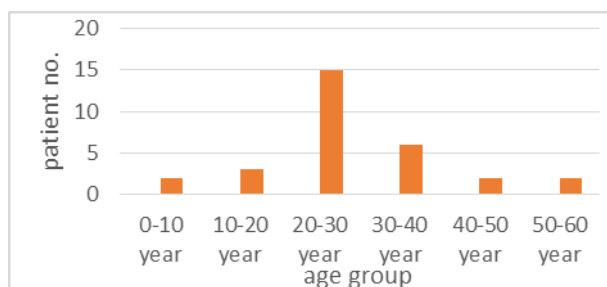


Fig.(2):- Distribution of patients according to age group.

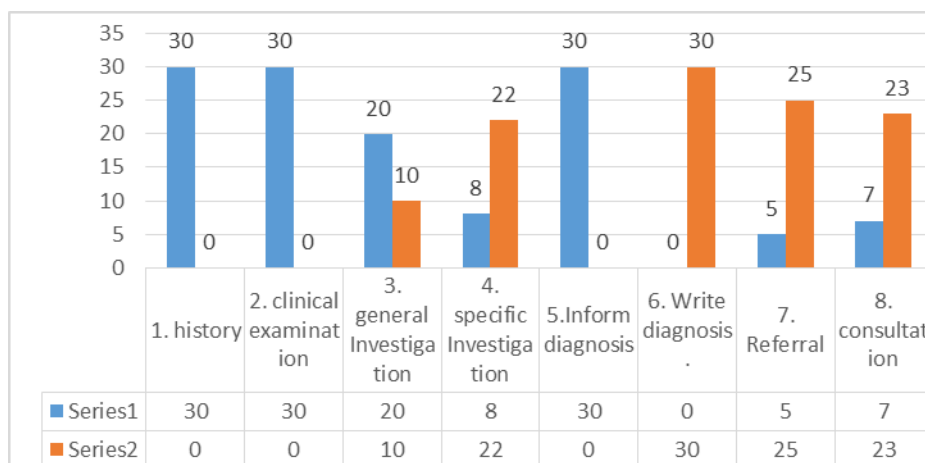


Fig.(3):- Misdiagnosis criteria by patients works.

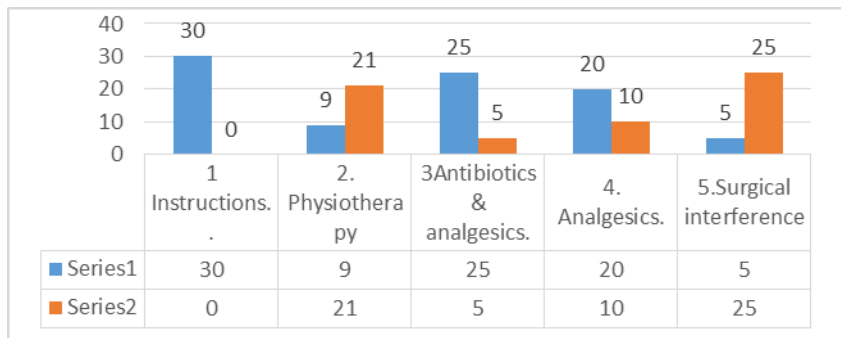


Fig.(4):- Past history of treatment.

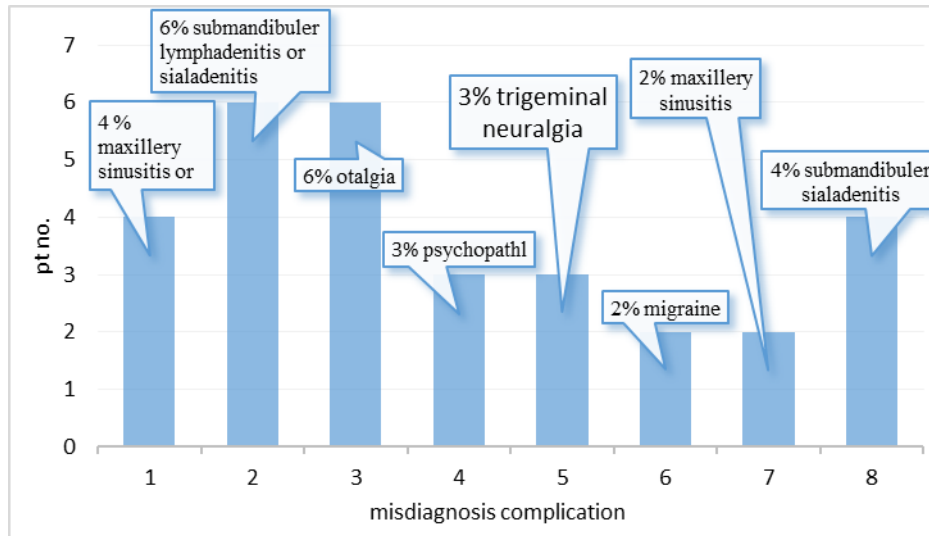


Fig.(5):- Distribution of patients according to misdiagnosis lesions & condition.

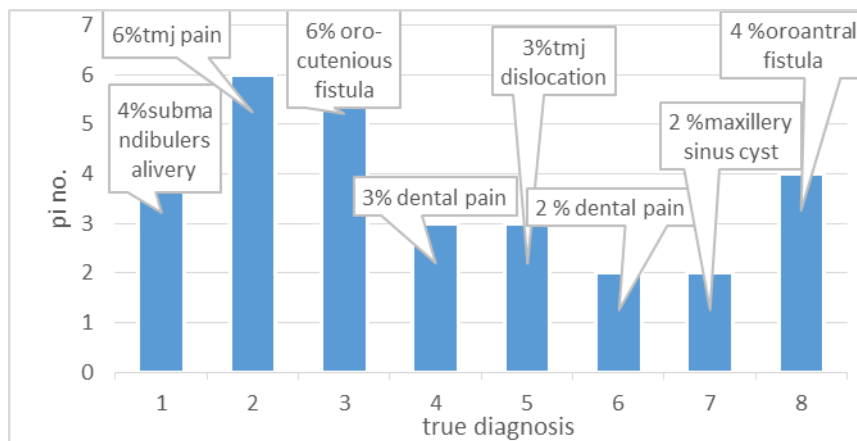


Fig.(6):- Distribution of patients according to true diagnosis conditions.

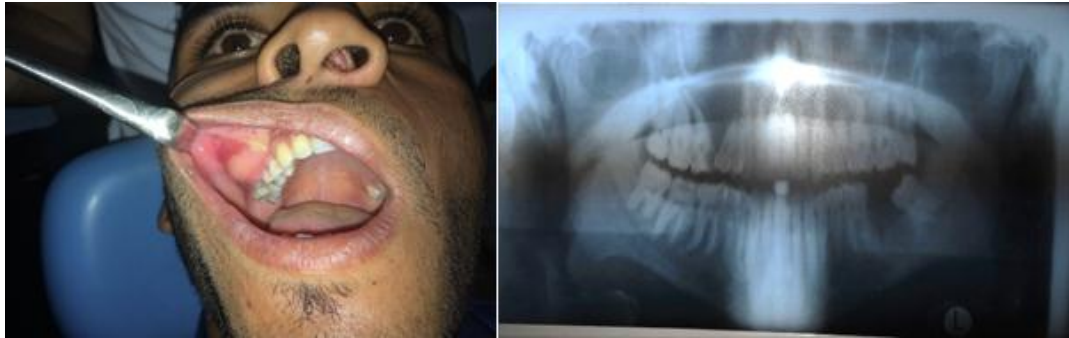

Fig. (2-1): Digital photograph & orthopantomograph x- ray show right side maxillary cyst.

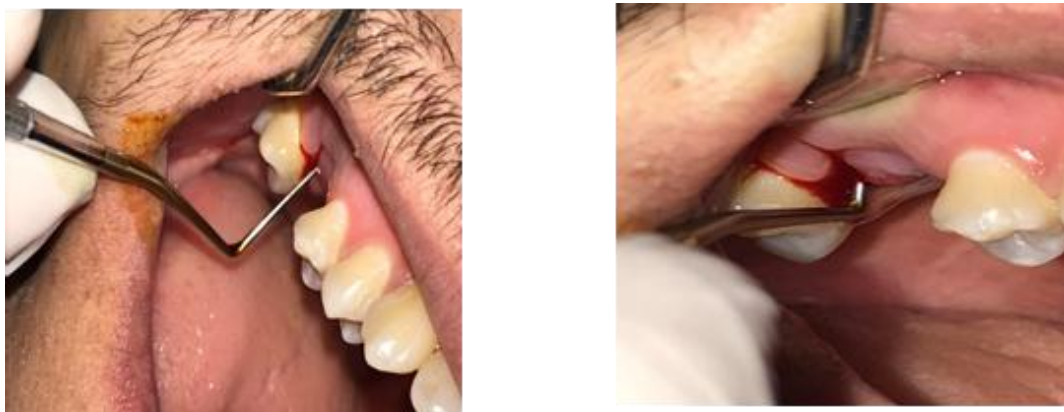


Fig. (2-2): Digital photograph show Oroantral fistula

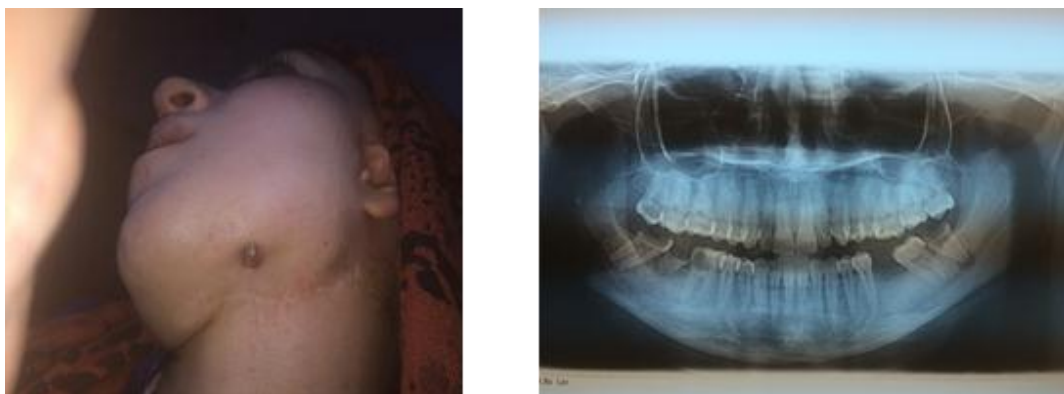

Fig. (2-3): Digital photograph show & orthopantomograph show oro-cutaneous fistula due to periapical infection.

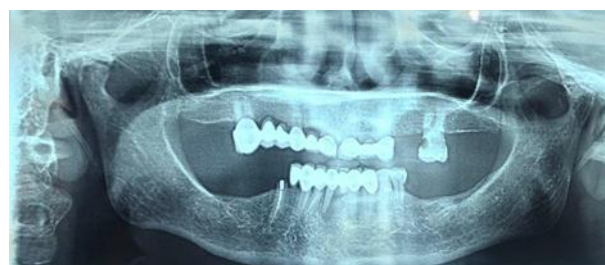

Fig. (2-4): Orthopantomograph show abnormal temporomandibular joint and condyle.

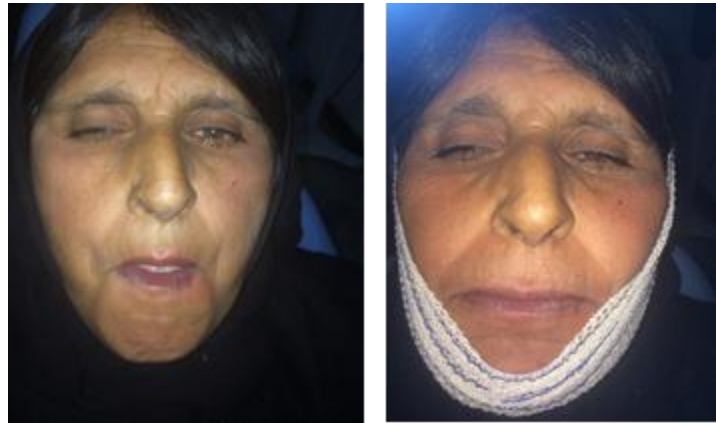

Fig. (2-5): Digital photograph show patient with temporomandibular joint dislocation before & after reduction.



Fig. (2-6): Digital photograph & occlusal x- ray show submandibular salivary gland

Table (1):- show no. of patient for each condition according to gender.

| Pt no. | Male | female |
|--------|------|--------|
| 4      | 2    | 2      |
| 6      | 4    | 2      |
| 6      | 2    | 4      |
| 3      | 0    | 3      |
| 3      | 2    | 1      |
| 2      | 0    | 2      |
| 2      | 2    | 0      |
| 4      | 3    | 1      |
| total  | 30   | 15     |

Table (2): show no. of patient for each condition according to age.

| Age group  | Pt. no. |
|------------|---------|
| 0-10 year  | 2       |
| 10-20 year | 3       |
| 20-30 year | 15      |
| 30-40 year | 6       |
| 40-50 year | 2       |
| 50-60 year | 2       |
| total      | 30      |

Table (3): Misdiagnosis criteria by Patient words

|                           | yes | No | Total no |
|---------------------------|-----|----|----------|
| 1. history                | 30  | 0  | 30       |
| 2. clinical examination   | 30  | 0  | 30       |
| 3. general Investigation  | 20  | 10 | 30       |
| 4. specific Investigation | 8   | 22 | 30       |
| 5. Inform diagnosis       | 30  | 0  | 30       |
| 6. Write diagnosis.       | 0   | 30 | 30       |
| 7. Referral               | 5   | 25 | 30       |
| 8. consultation           | 7   | 23 | 30       |

Table (4): history of treatment.

|                           | Yes | No | Total no |
|---------------------------|-----|----|----------|
| 1 Instructions.           | 30  | 0  | 30       |
| 2. Physiotherapy          | 9   | 21 | 30       |
| 3Antibiotics& analgesics. | 25  | 5  | 30       |
| 4. Analgesics.            | 20  | 10 | 30       |
| 5.Surgical interference   | 5   | 25 | 30       |

Table (5): show no. of patient for each misdiagnosis lesions& condition.

| Pt no. | misdiagnosis conditions                      |
|--------|--|
| 4      | maxillary Sinusitis or dental pain           |
| 6      | Submandibular Lymphadenitis. or Sialadenitis |
| 6      | Otalgia.                                     |
| 3      | psychopath                                   |
| 3      | Trigeminal neuralgia                         |
| 2      | migraine                                     |
| 2      | maxillary sinusitis                          |
| 4      | submandibular saialidinitis                  |

Table (6): show no. of patient for each true diagnosis conditions

| Pt no. true diagnosis conditions | True diagnosis                     |
|----------------------------------|------------------------------------|
| 4                                | Oroantral fistula                  |
| 6                                | Oro-Cutaneous fistula              |
| 6                                | Tmj pain                           |
| 3                                | Tmj dislocation                    |
| 3                                | dental pain                        |
| 2                                | Dental pain                        |
| 2                                | Maxillary sinus cyst               |
| 4                                | submandibular Salivary gland stone |

Table (7) show no. of patient for each miss diagnosis vs true one.

| Pt no. | gender |        | Misdiagnosis lesions&conditions              | true diagnosis conditions          |
|--------|--------|--------|--|------------------------------------|
|        | male   | female |  |                                    |
| 4      | 2      | 2      | maxillary Sinusitis or dental pain           | Oroantral fistula                  |
| 6      | 4      | 2      | Submandibular Lymphadenitis. or Sialadenitis | Oro-Cutaneous fistula              |
| 6      | 2      | 4      | Otalgia.                                     | Tmj pain                           |
| 3      | 0      | 3      | psychological                                | Tmj dislocation                    |
| 3      | 2      | 1      | Trigeminal neuralgia                         | dental pain                        |
| 2      | 0      | 2      | migraine                                     | Dental pain                        |
| 2      | 2      |        | maxillary sinusitis                          | Maxillary sinus cyst               |
| 4      | 3      | 1      | submandibular saialidinitis                  | submandibular Salivary gland stone |
| total  | 30     | 15     |  |                                    |

## References

- 1-(Definition of misdiagnosis from the Cambridge Advanced Learner's Dictionary & Thesaurus © Cambridge University Press).
- 2-Anil Govindrao Ghom, Savita Anil Ghom (Lodam) Textbook of ORAL MEDICINE.3ed edition 2014.chapter 1 page1.
- 3- Steven I. Bricker, D.D.S., M.S., F.A.C.D.
- 4- [www.verywellhealth.com](http://www.verywellhealth.com) › how-common-is-misdiagno. Wikipedia.text book of psychiatry.2020.
- 5-En.wikipedia.org › wiki › Complication\_(medicine)[https://en.wikisource.org/wiki/Fasting\\_for\\_the\\_cure\\_of\\_disease/Chapter\\_18.2013](https://en.wikisource.org/wiki/Fasting_for_the_cure_of_disease/Chapter_18.2013).
- 6-Oral and Maxillofacial Surgery Front Cover Lars Andersson, Karl-Erik Kahnberg, M. Anthony Pogrel John Wiley & Sons, Jan 10, 2012 page529
- 7-Lipton, S. "Pain mechanisms and management." British medical bulletin 47.3 (1991): i-iv.
- 8-<https://pocketdentistry.com/32-diagnosis-and-non-surgical-management-of-orofacial-pain/>
- 9- Oral and Maxillofacial Surgery Lars Andersson DDS, PhD, DrOdont Karl-Erik Kahnberg DDS, PhD, DrOdont M. Anthony (Tony) Pogrel DDS, MD, FRCS, FACS, Associate Dean for Hospital Affairs
- 10-<https://www.healthline.com/health/salivary-duct-stones>
- 11-Akhlaghi, F., Esmaeelinejad, M., & Safai, P. (2015). Etiologies and treatments of odontogenic maxillary sinusitis: a systematic review. Iranian Red Crescent Medical Journal, 17(12).
- 12- Pandey, Rajeev, et al. "Orocutaneous Fistulae Mimicking as Dermatological Lesion: A Diagnostic Dilemma."
- 13-Kim, D. S., et al. "Dental otalgia." The Journal of Laryngology and Otology 121.12 (2007): 1129.
- 14-Marbach, J. J., & Lund, P. (1981). Depression, anhedonia and anxiety in temporomandibular joint and other facial pain syndromes. Pain, 11(1), 73-84.
- 15-Mehta, Sujay A., Joel B. Epstein, and Charles Greene."PratiqueCLINIQUE." J Can Dent Assoc 72.9 (2006): 835-9.
- 16-de Siqueira, Silvia Regina Dowgan Tesseroli, et al. "Idiopathic trigeminal neuralgia: clinical aspects and dental procedures." Oral Surgery, Oral Medicine, Oral Pathology, Oral Radiology, and Endodontology 98.3 (2004): 311-315.
- 17-Kaya, Ömer, and Önder Bocutoğlu. "A misdiagnosed giant dentigerous cyst involving the maxillary antrum and affecting the orbit. Case report." Australian Dental Journal 39.3 (1994): 165-167.
- 18-Mehanna, Hisham, et al. "Salivary gland swellings." Bmj 345 (2012).