



## **Treatment of Distal Extension Edentulous Arches with Attachment Retained Cobalt Chromium Partial Dentures-A Case Report**

Hikmat Jameel Aljudy

Department of Prosthodontics, College of Dentistry, University of Baghdad. Baghdad-Iraq.

### **Article Info:**

#### **-Article History:**

**-Received:** 1/8/2020

**-Accepted:** 28/8/2020

**-Available Online:**  
Dec, 2020

**Keywords:** Precision Attachment, cast partial denture, partial edentulism, retention.

#### **Corresponding Author:**

**Name:** Hikmat J. Aljudy

**E-mail:**

**Tel:**

#### **Affiliation:**

Asst. Prof., Department of Prosthodontics, College of Dentistry, University of Baghdad. Baghdad-Iraq.

### **Abstract**

**Background:** The awareness and demand for quality of dental treatment is relatively increasing in recent generation and more so, as far as aesthetics are concerned, along with other functions of the prosthesis. In treating partially edentulous mouth, it requires more attention, principally for esthetics, in design. While achieving the goal, the components which are incorporated in removable partial denture may result in unsightly appearance. **Case Description:** A 77 year old patient reported to the replacement of his missing teeth for which a conventional maxillary complete denture and cast removable partial denture with precision attachments were planned to construct. Extra coronal resilient attachment was planned to re-claim support and thereby regain of lost esthetics in the mandibular arch. **Conclusion:** Use of precision attachment has amplified the aspects of retention and particularly, esthetics when compared to conventional removable partial dentures.

### **Introduction:**

Our ever-increasing knowledge of the oral environment, together with technological improvements and good armamentarium, has taken us to give a restoration which is esthetically pleasing and comfortable. This makes it all the more important to reconcile what is actually feasible with the patient's own expectations. Rehabilitation of partially edentulous situations can be challenging when it is distal extension situations where a fixed prostheses cannot be fabricated. Implant retained restoration are an option but this is sometimes not possible due to insufficient amount of bone or economic reasons <sup>(1)</sup>.

A removable partial denture with a retained attachment system is one of the treatment modalities which may assist a prosthodontist to achieve better functions and aesthetics in substituting missing teeth and oral structures. An attachment is defined as "A mechanical device for the fixation, retention and stabilization of prosthesis". It's a connector consisting of two parts, one part is connected to a root, tooth or implant and the other part to a prosthesis <sup>(2)</sup>. This type of prosthesis not only gives esthetics in addition also gives functional advantage of fixed denture that leads to decreased compression of

edentulous ridge and enhanced phonetics and mastication<sup>(3)</sup>

Precision attachment can give maximum comfort to the patient and can be inserted and removed easily by the patient. Precision attachments can be classified into four main groups:

1. Intra coronal attachments: Are mainly used in connecting units of fixed partial prosthesis, retaining restorations with distal extension or bounded removable prosthesis.
2. Extra coronal attachments: These types of attachments provide stability and attention for removable distal extension prosthesis.
3. Stud attachments: Usually in the form of ball and socket, this attachment serves primarily for over denture stabilization and retention of the prosthesis. Swiss logic, ZAAG, Zest anchor is example of stud attachments.
4. Bar attachments: Originally used for splinting groups of teeth, currently used for over denture retention and stabilization.<sup>(4)</sup>

Selection Criteria is Based upon Location, Function, Retention, Space and Economy. Depending on the Location, intra-coronal, extra-coronal, radicular/intraradicular stud type and bar type could be used. Intra-coronal type, as designed by Herman Chayes in 1906, consisted two parts, a slot (female) and a flange (male). The flange is connected to the removable prosthesis which fits into the slot embedded in a fixed restoration. Advantages being as occlusal forces which are close to the long axis of the tooth and better esthetics as attachment is within the crown of the abutment tooth; But also disadvantageous as it is not always possible to create box preparation for female element in every case. Radicular / intraradicular stud type composed of a projection soldered to a post-type crown and a corresponding female receptacle that is embedded in an overlay type of denture prosthesis<sup>(5)</sup>. Extra-coronal types have most of their mechanism outside of the diameter of abutment restoration. In most types, a projecting receptacle is soldered to the crown, and a corresponding fitting or housing is incorporated in the removable prosthesis. With this type of attachment,

there is usually a certain amount of movement between the two sections of the prosthesis however it can maintain normal tooth contour and requires minimal tooth reduction and thus less possibility of devitalizing the tooth<sup>(6)</sup>. Usually the choice of attachment is determined according to number, distance and location of remaining natural teeth or the discretion of the prosthodontist on his clinical experience. Thus, preservation of tooth along with the use of state of the art retention system i.e. precision or semi precision attachments is an effective way to improve the retention and support of the prosthesis. Precision attachment has long been considered the highest form of partial denture therapy. Attachment retained RPD is the treatment modality that can facilitate both esthetic and a functional replacement of missing teeth and oral structures<sup>(7)</sup>. So, the purpose of this report is to present a technique which is a more effective approach utilizing precision attachment in rehabilitating partially edentulous patient.

## CASE REPORT

A 77 year old male patient referred to the department of prosthodontics, college of dentistry, university of Baghdad. A chief complaint is to replace his missing teeth in the upper and lower arches. Intra oral examination revealed that the maxillary arch is completely edentulous, and the mandibular arch is partially edentulous with CL II mod 1 Kennedy classification Fig. (1,2). Treatment planned was attachment retained removable partial denture for the mandibular arch and conventional complete denture for maxillary arch.

## Treatment

Using stock tray, preliminary impressions with Impression compound (Hoveman – Germany) for maxillary arch and with alginate (Zhermack – Italy) for mandibular arch were made. A custom tray with conventional border molding procedure using low fusing impression compound (Hoveman-Germany) and final impression were made for maxillary arch with zinc oxide eugenol impression paste.

After final design decided on the study model, the treatment plan for mandibular arch is cobalt chromium (Co-Cr) partial denture with precision attachment on lower right first premolar. Tooth preparation was performed for porcelain fused to metal (PFM) and occlusal clearance was assessed by keeping space for arranging missing teeth Fig. (3). Final impression of the prepared tooth made with light body elastomeric impression material (Polyvinylsiloxane, Zhermack Italy) using dual impression procedure Fig. (4) and then poured with die stone (elite body, Zhermack-Italy). Bite record was taken in mouth and casts were mounted on articulator, wax patterns were fabricated for porcelain fused to metal crown. Dental surveyor, Guiding planes, rest seats were prepared in the wax pattern and Patrice's were added to the axial surface of the abutment. Male attachment is kept 1mm above the gingival to facilitate oral hygiene subsequently casting, finishing and veneering of fixed component was done. Margins and fit of the crowns were checked with the attachment in the patient's mouth Fig. (5, 6). A Custom tray was fabricated for mandible arch, border molding was done and pick-up impression was made of mandibular arch with light bodied elastomeric impression material. Impression was then poured in die stone, wax patterns were made for cast partial denture framework, and then casting, finishing and polishing was done with female attachment in place. Cast partial denture framework was tried in the patient's mouth and adjusted accordingly Fig. (7), wax rims were fabricated and jaw relation record was established, bite record was made Fig. (8). After patient's approval for esthetics and speech, cast partial framework was processed with Heat activated acrylic resin. Metal ceramic crowns were cemented with glass ionomer cement and cast partial denture was inserted in patient's mouth Fig. (9), deflective contacts were checked and corrected using articulating paper, and post insertion instructions were given. Patient is kept under observation for subsequent period. There are several treatment options for the rehabilitation of

partial edentulism. Depending on several given diagnostic factors and a patient's perspective, best treatment plan should be selected for the patient. Precision attachment has exceptional feature of being a removable prosthesis with improved aesthetics, less post-operative adjustments and better patient comfort.<sup>(8)</sup> The visibility of anterior tooth surfaces with lips at rest or during function is an important factor in determining prosthodontic outcome. Any prosthetic treatment, removable or fixed, that involves their replacement is considered to be critical<sup>(9)</sup>. In case of partially edentulous mouth, Retention provided by the usage of precision attachments which may be related to comfort, satisfaction, chewing ability, as well as adequate distribution of occlusal loads to, and preservation of abutment teeth in patients with removable partial dentures<sup>(2)</sup>. Retentive ability increases significantly over time in the metal alloy precision attachment group. Charkawi HG *et al*<sup>(10)</sup> evaluated and quantified changes in retention ability and weight change over time and thus reported Metal-alloy and plastic inserts precision attachments preserve supporting teeth and alveolar bone ridges when associated with at least two splinted abutments<sup>(10)</sup>. Holst *et al*<sup>(11)</sup> cited as it is difficult to evaluate precision attachments' effects on treatment longevity based solely on *in vitro* results since other factors such as continuous ridge resorption, changes in saliva flow and composition, and occlusal considerations may affects its long-term success. The decision to use attachments in removable partial denture design should be carefully considered. Clasp-type removable partial dentures should be used whenever practical because of their lower cost, ease of fabrication and maintenance, and the predictability of results. However, if an attachment removable partial denture is the treatment of choice because of esthetics, abutment alignment, or the need for greater cross-arch bracing, it must be used with a thorough knowledge and understanding of prosthodontic principles and attachment use, as well as an awareness of the intricacies and special problems associated with attachments. In

treatment using the attachment-retained distal extension removable partial denture, the development of a stress-directing attachment design as well as the proper distribution of forces between the residual ridge and abutment teeth should be goals for successful treatment.

### Conclusion

The success of prosthesis depends on careful treatment planning and attention to the prosthodontics problems; the mechanical ingenuity of the attachment is important, but must take second place. Precision attachments present a challenge in the technical skill. A thorough

understanding of the biomechanics of maxillo mandibular function, different attachments and knowledge of material science is essential in treating a case of precision attachment. Unfortunately, most often precision attachments are chosen from descriptions in manufacturer's catalogues which leads to failure of precision attachment cases. Precision attachments serve the function of retention, stress distribution and aesthetics successfully provided the case is planned based on sound biological and technical grounds and proper care is rendered by the dentist and the patient during the maintenance phase.



Fig.(1):pre-operative photograph

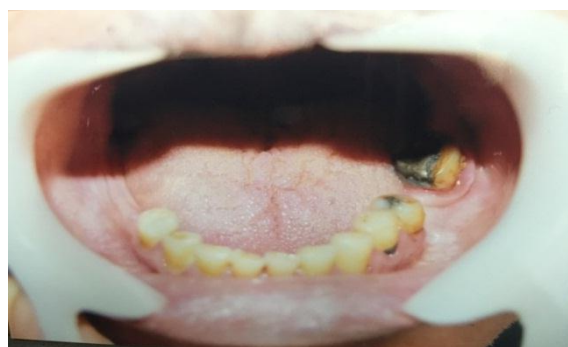

Fig.(2): Intra- oral picture

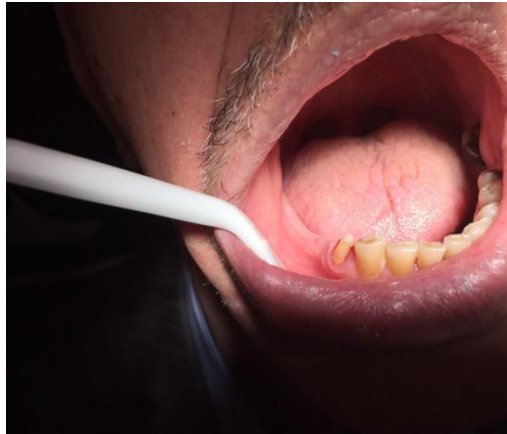

Fig.(3): Tooth preparation.

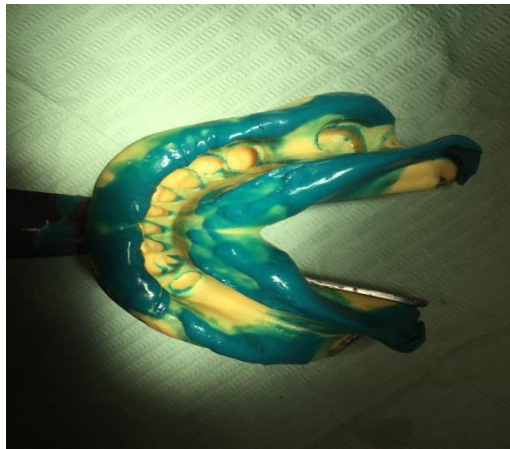

Fig.(4): Final impression.

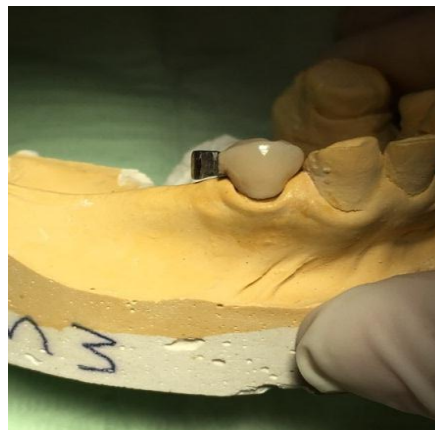


Fig.(5): PFM with Patrice attached.

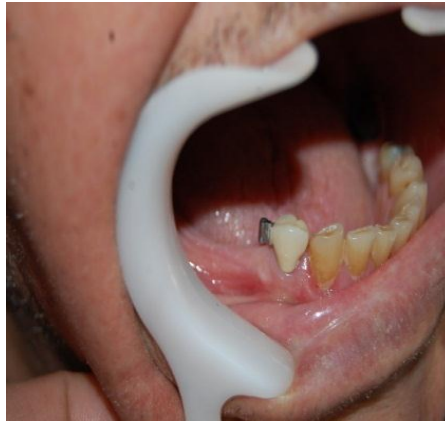

Fig.(6): PFM crown trial in the mouth.

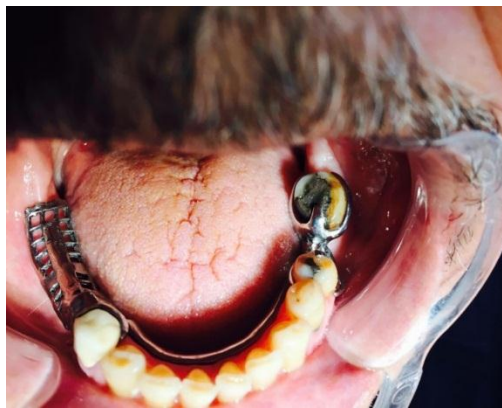

Fig. (7): partial denture frame trial in the mouth.

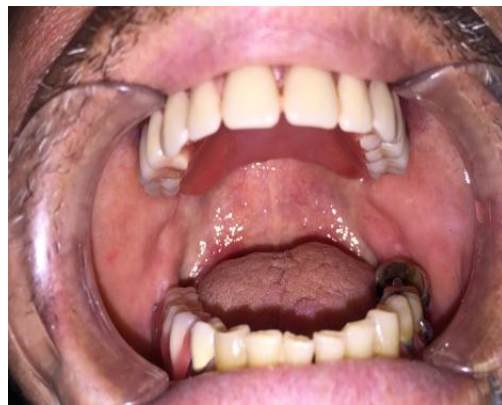

Fig. (8): waxed denture trial in the mouth

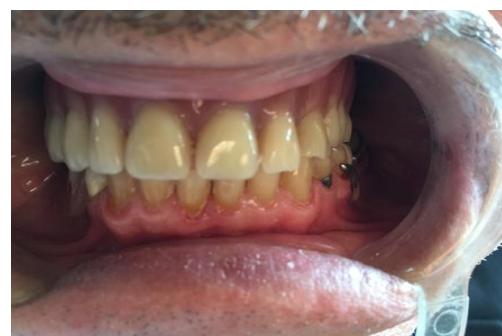

Fig. (9): final prosthesis in patient's mouth.

## References

- 1- Makkar S, Chhabra A, Khare A. Attachment Retained removable partial denture: A case report. *Int. journal of clinical Dental science* 2011;2(2):39.
- 2- Patel H, Patel K, Thummer S, Patel RK. Use of precision attachment and cast partial for long - span partially edentulous mouth-A case report *Int. Journal of Applied Dental Sciences* 2014; (1): 22-25.
- 3- Tomar GK, Garhaya K M, Das SS, Ray S. cast partial denture retained using precision attachment. A case report. *IOSR- JDMS* 2016;5(7):94-99.
- 4- Shakeel SK. Removable prosthesis using extra coronal precision attachment: A case report *Gulf Medical Journal, ASM* 2013; (S1): S126-129.
- 5- Elliot Feinberg, Edward M. Feinberg. Attachment retained partial denture. *Nys Dental Journal* march 1984; 3:161-164.
- 6- Burns DK, Ward JE. A review of attachments for removable partial denture design: Part 2. Treatment planning and attachment selection. *Int J Prosthodont* 1990; 3:169-174.
- 7- Mistry S, Ahuja S, Karani J, Bhatnagar V. Enhancing retention of overdentures with semi precision attachments - A case Report. *Journal of Applied Dental and Medical sciences* 2016; 2(2):85-89.
- 8- Shetty PK, Shetty BY, Hegde M, Prabhu BM. Rehabilitation of long-span Kennedy class IV partially edentulous patient with a custom attachment-retained. *The Journal of Indian Prosthodontic Society* 2016; 16(1): 83-86.
- 9- Shetty NB, Shetty S, Nagaraj E, Shetty O, D'souza R. Precision attachments for Aesthetics and function: A case - report. *Journal of clinical and diagnostic Research*. 2014;8(1):268-270.
- 10- Charkawi HG, Wakad MT. Effect of splinting on load distribution of extracoronar attachment with distal extension prosthesis in Vitro. *J Prosthet Dent* 1996; 76(3):315-320.
- 11- Holst S, Blatz MB, Eitner S, Wichmann M. In Vitro wear of different material combinations of intracoronar precision attachments. *Int J Prosthodont* 2006; 19(4):330-332.