

Minor Salivary Gland Tumors a Clinicopathological Study and Management

Natheer A.Jassem.⁽¹⁾
Ali F.Al-Zubaidee.⁽²⁾

Key words:
minor salivary gland, tumors, clinical pathology, management.

Abstract

Salivary gland tumors are uncommon and most reported series include tumors affecting both major and minor glands. Very few series have focused solely on intra-oral minor salivary gland tumors. Is to report the clinicopathological data of intra-oral minor salivary gland tumors in sample of patients in Baghdad, Most important characteristic features of benign and malignant tumors, different pathological behavior and the importance of pathological classification in changing the management plans. Thirty five patients with tumors of minor salivary gland were analyzed clinicopathologically and the management of these tumors is discussed. 19 female and 16 male patients, age range from 9-79 years. The range of duration of tumors was about 3 years and the size range from 1-7cm. The most common site was the palate followed by floor of mouth, lips, cheek, and the maxillary alveolar ridge respectively. Different methods of surgical management of minor salivary gland tumors from simple excision of tumors mass to total maxillectomy were also described.

Introduction:

Tumors of minor salivary glands (MSG) constitute an important area in the field of oral and maxillofacial surgery, although such tumors are uncommon, they are by no means rare. Tumors of minor salivary glands are not as common as tumors of the parotid gland, these tumors in every way identical to those occurring in the major salivary gland and are minor in name only, any surgery apply to such tumors depend on two important factors⁽¹⁾⁽²⁾

1. Histopathological study
2. Site of tumors

Some different features are present in management of minor's salivary gland tumors as compared with those occurring in the major salivary glands.⁽³⁾

Anatomy of minor salivary gland:

The minor salivary glands have been classified according to their location as:

- (1) Specialist of maxillofacial surgery in al- Wasity hospital, Baghdad.
- (2) Specialist of maxillofacial surgery in al- Wasity hospital, Baghdad.

1. The labial salivary gland hundreds of which line the upper and the lower lips.
2. The buccal salivary glands include aggregate of larger molar and retro molar glands.
3. The palatine salivary glands a complex of approximately 230 minor salivary gland, which are situated in the mucosa of soft palate and posterior part of hard palate.
4. Lingual salivary glands which involve Glands situated in the floor of mouth and tongue⁽¹⁾.

Stephen Paget described palatal tumors of MSG origin and received 31 cases in 19 the century literature (Paget)⁽⁴⁾.

Christopher Health illustrated in his Jechsonian prize essay of the Royal College of Surgeons, England in 1884 (Health), and Scotland reports appeared in the next 75 years, referring to ectopic or accessory salivary glands.

The fact that the minor salivary glands are not ectopic would seem to have been overlooked. Sir John Bland-Sutton (1907) made no mention of tumors of MSG origin

in the fourth edition of tumors; Innocent and Malignant (Bland Sutton) but had rectified this by seventh edition.

Demographic features; According to AFIP (the registry of the armed forces institute of pathology) study in Washington D.C, a collection of 14000 epithelial tumors of major and MSG determine that (63.2%) of tumors were benign and (36.8%) were malignant, tumors of MSGs accounted for (23.2%) of the AFIP collection. Overall, (51, 3%) of MSGs tumors were benign and (48.7%) were malignant, AFIP data confirm the palate as the most common site of MSGs accounting about (44%) of their total, site was followed in frequency by cheek (12.3%) and upper lip (12.3%)^{(4) (5)} AFIP show the tongue, floor of mouth, retro molar pad and lower lip as sites with a substantially greater proportion of malignant MSG tumors.^(4,6)

Clinical features:

The MSG tumors may occur at any age, rarely in children, and there is slight preponderance of female patients in some series. They are rarely bilateral (Praytor 1966). The age of the patient ranged from 13 -79 years and 61 of 98 tumors were benign⁽²⁾.

The most common description of a MSG tumors is that firm, slowly growing sub mucosal mass, tumors of hard palate are firmly fixed, tumors of tongue tend to feel indurated and fixed to overlying mucosa, tumors intraorally mostly appear well circumscribed and seldom is allowed to attain greater than 1-2 cm. Pain is uncommon feature in MSG tumors but may be first draws the patient's attention to lesion, ulceration specially in palatal lesion is usually related to masticatory trauma or an ill-fitting appliance, but spontaneous ulceration should be viewed with greater suspicious of malignancy tumors. Paraneesthesia is rarely sign in MSG tumors even in case of malignant tumors.^{(2) (6) (7) (8)}

Classification of MSG neoplasm based on the AFIP;

A. Primary benign epithelial tumors which include

1. Pleomorphic adenoma.
2. Myoepithelioma

3. papillary cystadenoma lymphomatosum (Warthin's tumors)

4. Canalicular epithelial tumor.

5. Basal cell adenoma

6. Oncocytoma.

B. Malignant tumors of MSG.

1. Adenoid cystic carcinoma.

2. mucoepidermoid carcinoma.

3. Polymorphous low grade adenocarcinoma.

4. Acinic cell adenocarcinoma

5. Adenocarcinoma not otherwise specific.^{(3) (9) (10)}

The primary treatment of these neoplasms, both benign and malignant is surgical. Despite the emphasis on surgeon, there is evidence of tumor control in adenoid cystic carcinoma and some adenocarcinoma with radiotherapy.⁽¹¹⁾ Mucoepidermoid carcinoma show less response to the radiotherapy (Millon1982, Healy1970). The traditional view point that malignant salivary tumors are radioresistant is due to the slow mitotic rate of these lesions⁽¹²⁾, which means that regression in response to radiation therapy also may be slow, although radiation has a role, both adjuvant to surgery and for inoperable salivary gland malignancies, little evidence support any role for chemotherapy. So that the objective of surgical treatment of MSG tumors is complete removal of lesions with (cuff) of normal tissue histopathological diagnosis. The difficulty in achievement of complete removal is determined by the extend and site of tumor. The extent of benign tumor is determined by size of tumor itself and involvement of vital structures; the extent of malignant tumor is assessed by the TNM system^{(11) (13)}.

Materials and method:

The study compromised 35 patients with intraoral salivary gland tumors, the variable record include the patient age, sex, and the estimated duration of tumor before diagnosis, size, site, and the nature of surgery in those cases which has been operated. The period of study extend from 2001 to 2004. All patients live in Baghdad except 6 from Mosul and 3 from Salah ald-Din city. All cases diagnosed in the oral pathology department in dentistry

collage of Baghdad University. The case sheet include the following notes; name, age, sex, address, chief complain clinical examination (location of mass, its size, duration, color of mucosa, presence or absence of ulcer, teeth condition lymph node enlargement). Established diagnosis (ordinary x-ray if needed, CT scan or MRI, FNA, biopsy) and surgical operation.

The histological typing of these tumors are based on the WHO classification in 1991 which classify the tumors into; benign tumors as pleomorphic adenoma and monomorphic adenoma and malignant tumors as mucoepidermoid carcinoma, adenoid cystic carcinoma, adenocarcinoma and acinic cell tumor.

Fine needle aspiration biopsy; uses in ten patients with MSG tumors when result compare with incisional or excisional biopsy only 5 patients confirmed the diagnosis.

All **benign MSG tumors** treated by excision of all tumors with 0.5 cm. cuff of normal tissues.

Malignant tumors; 3 patient underwent total maxillectomy 2 with mucoepidermoid carcinoma and one with adenoid cystic carcinoma, 2 patient treated with radical maxillectomy with exenteration of the orbit due to involvement of orbital content with tumors one with adenoid cystic carcinoma and other one with mucoepidermoid carcinoma).

One female patient age 65 years with adenoid cystic carcinoma treated with radical neck dissection due to involvement of cervical lymph node.

Results:

General over view; 19 (54.3%) were male and 16 (48.6%) female patients, 18 patient had malignant tumor (51.4%) and 17 patient (48.6%) had benign tumor fig 1 and 2.

tumors were involve all age group (9 – 79 years)the mean age was about (39.4 years).we found benign tumors were more frequent at the first, second, and third decades as in fig 3

The size was averrable median size for all tumors was 28 .06 and we take a diameter

of lesion in round mass and long axis in oval one, smallest tumor was monomorphic adenoma of lower lip which about 1cm. and the biggest one was 7cm. in dimeter which mucoepidermoid carcinoma of palate (fig. 7).

The most commonly affected site was the hard palate, especially the posterior part of hard palate (25 patient 71, 42%), 12 patients (48%) were benign and 13 patients (52%) were malignant. Lips affected in 4 patient (11.42%)of sampleall tumors of lip were benign ,floor of mouth affected in 4 patient (11.42) all tumors were malignant 1 mucoepidermod carcinoma and 2 adenoid cystic carcinoma and one acinic cell tumor . Cheek was affected in one patient with pleomorphic adenoma. And lastly maxilla involved in one patient.

Duration of tumors; the median duration for all tumor was 23.6 months the range was from 5 months in patient with monomorphic adenoma to 7 years in patient with mucoepdermid carcinoma fig.7.

Benign tumor, was 17 (48.57%) of patients, pleomorphic adenoma account for (42.85%) and basal cell adenoma were 2 (5.71%)

Malignant tumor; there were 18(51.42%) Mucoepidermoid carcinoma were 7(38.88) cases , 5 cases classified as low grade, one case as moderate and one as high grade Adenoid cystic carcinoma which about (17.14%) 6 patients, low grade polymorphus adenocarcinoma, involved 4 patient (22.22%) 3involve palate and one involve floor of mouth. Acinic cell tumor, only one case (5.55%) affected male in the floor of mouth.

Discussion:

Tumors of MAGs are unordinary and equal to about 20% of all salivary glands tumors, there are many literatures approved racial and geographic variety.⁽¹⁴⁾⁽¹⁵⁾ most literatures of salivary glands tumors involve both major and minor salivary gland in the artcils.so that we decided to concentrate on minor salivary glands tumors alone. MSGs tumors may affected any part of upper aerodigestive tract but we found the palate was most

affected site, but lesion may involve cheek mucosa ,retromolar area, lips, nasal cavity, paranasal sinuses and oropharynx ⁽¹⁷⁾ in this study the palate was mostly affected site (71,42%) this percentage less than Waldron (42.5%)⁽¹⁶⁾, but similar to many other studies^(14,17,18) which represented (65-80%)affected palate. followed by lips(11.42%),floor of mouth (11.42%) and cheek mucosa (2.8%). in study of Olivia ⁽¹⁹⁾ palate was affected by(49%)followed by lips (22%), cheek mucosa (11%). Behavior of MSGs tumors in our study was (51%) malignant and (49%) was benign. The percentage of malignant MSG tumors is close to 50% in the different studies published in articles⁽¹⁹⁾.In this study, Pleomorphic adenoma was most common benign tumors (48,57%) and this coincide with many other studies ^{(14) (18) (19)} that mention the incidence between (40-72%) were the palate was most common site. regarding malignant MSG tumors, mucoepidermoid carcinoma was most common (38.8%)followed by adenoid cystic carcinoma (17.14%) and this similar to result of Wei-Yung 2005. adenocarcinoma may occur in different sites with preference for the palate ,the percentage in our study has (11.42%) this number is larger than (2.5%) in study of Quan (1987) and similar to result of Eveson and Cawson (1985)⁽²⁰⁾.MSGs is growth take long time with an estimated time between 3-6 years this coincide with our study which may extend to 7 years in one case. The diagnosis of cases depend on biopsy (excisional or incisional), CT scan is very helpful in the diagnosis and to see the extension of tumors. the accuracy of FNA is varies according to skill of pathologist in study of (Young 1993)⁽¹⁷⁾give accurate result from 81 to 100%, in present study only 50% of sample gain the accurate result and this may be due to all FNA done in the lab. of our hospital which considered as not specialist in oral diseases. The treatment of choice for benign MSG tumors is surgical resection with safe margin. Treatment of malignant MSG tumors was surgery with larger safe margin with post radiotherapy is the treatment of choice in


this study the involvement of lymph node was rare only one case with adenoid cystic carcinoma underwent radical neck dissection.

Conclusion:

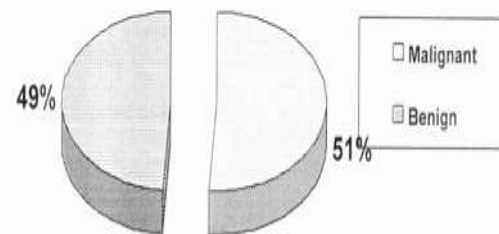
1. Tumors of MSG are minor in name only and histologically are similar to tumors affected major salivary glands.
2. Tumors of MSG may involve paranasal sinuses, naso. oro., laryngopharynx , larynx , trachea and ear.
3. The pain is not main symptom in both malignant and benign tumors.
4. The extend, size, anatomical site and histopathologic diagnosis determine the management of these lesions.
5. Surgery consider to be primary treatment modality
6. Clinically clear margin of not less than 1-1, 5 cm. and d the exclusion of perineural infiltrate are recommended.
7. Long term follow up is recommended since five year is not adequate period of supervision and many authors had experienced recurrence after 10-13 years.

Recommendation

Study on relation between different genes expert ion and MSG tumors.



(Fig.1)



(Fig.2)

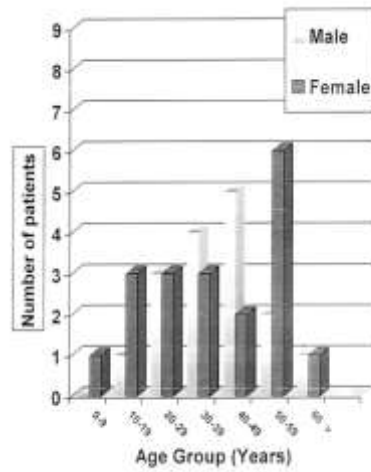


Fig (3): Distribution of patients according to age groups

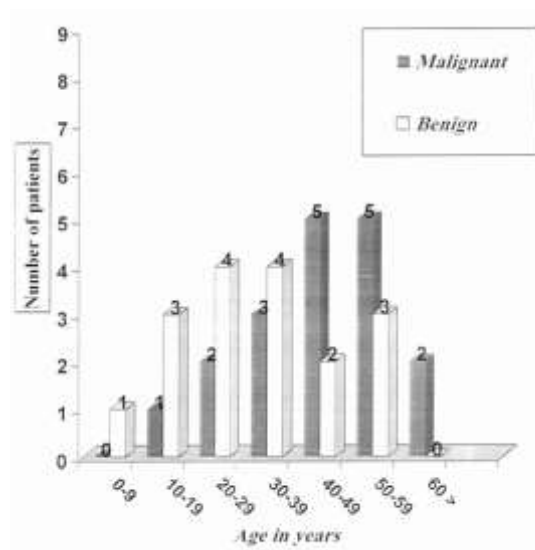


Fig (4): Distribution of patient according to behavior of tumors.

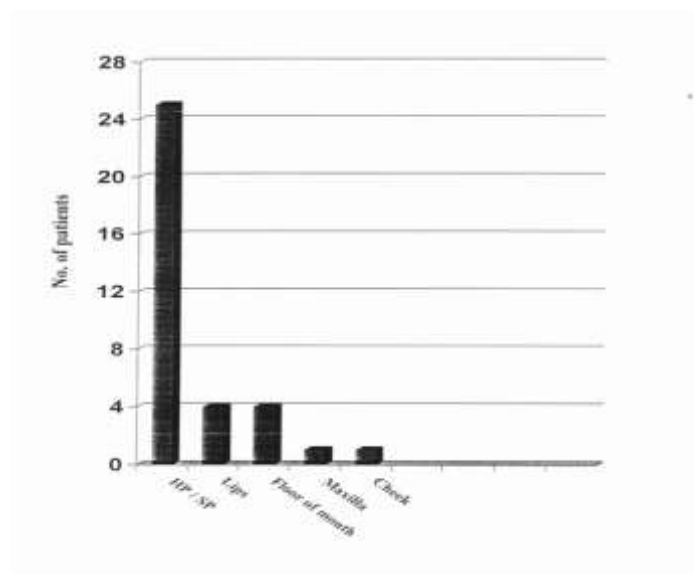


Fig (5): Distribution of MSG tumors according to the location in the mouth

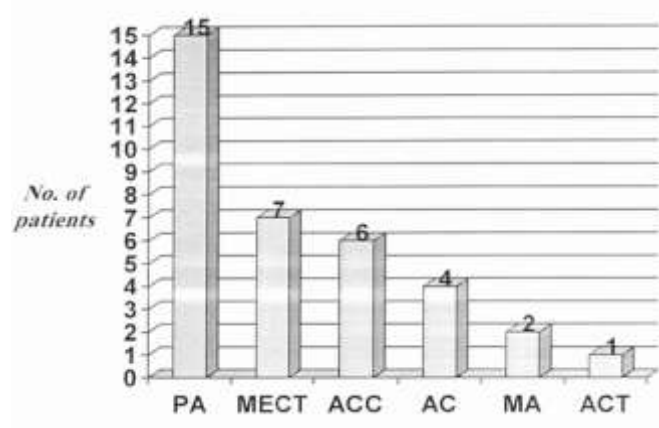


Fig (6): Pathological classification of minor salivary gland tumors.

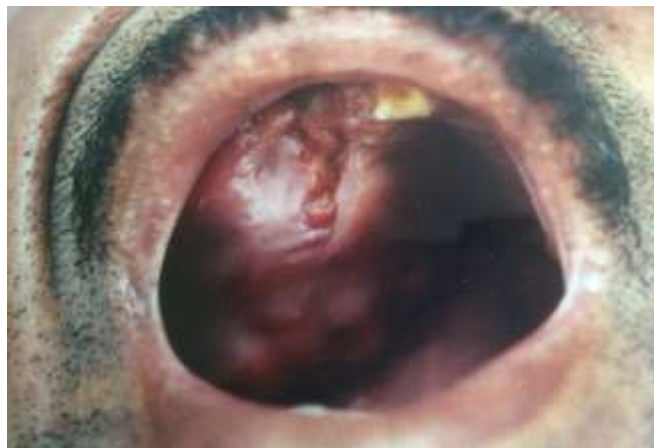

Fig (7): Mucocoeppidermoid carcinoma of 7 years duration

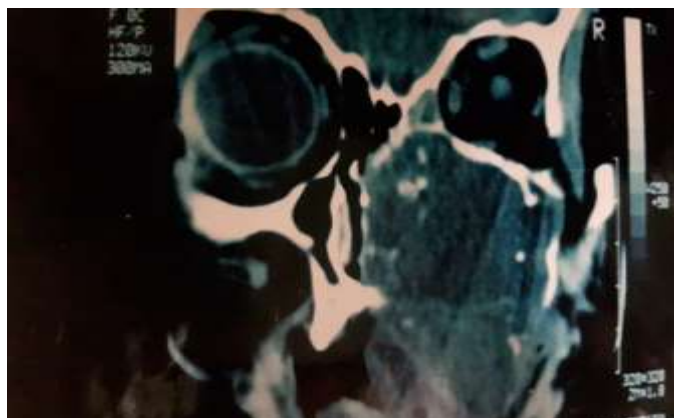


Fig (8): CT scan of same patient in fig. 7

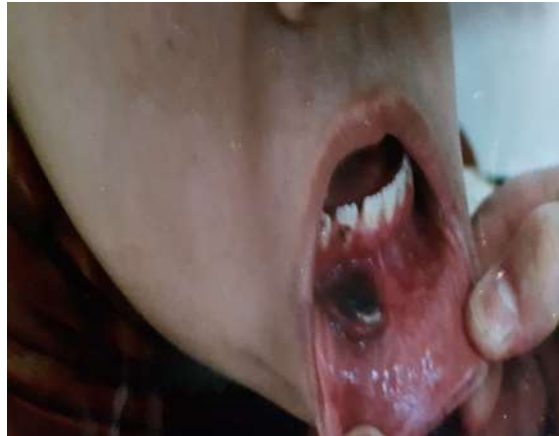

Fig (9): basal cell adenoma of lower lip



Fig (10): pleomorphic adenoma of upper lip.

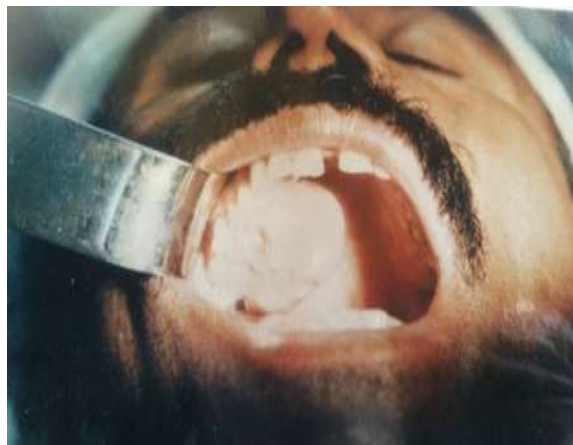

Fig (11) Adenocystic carcinoma 2 years duration.

References:

1. A.P. Tencate (1994): Oral histological development, structure and function, 4th ed.:PP.359-360.
2. Chau NY and Radder BG (1986): Intraoral salivary gland neoplasm: A retrospective study of 98 cases. *J Oral Pathology*: 15; 339-342.
3. CiilaR,Schort R,et al (1980):Adenoid cystic carcinoma of the head and neck :controllable and un controllable, factors in the treatment andprognosis.*J.Otorhinolaryngol.Relat. Spec.*42:346.
4. Ellis GL,Auclair PL,et al(1991);Salivary glands.Philadelphia,W.B.Saunders.PP. 135-164.
5. Eveson HL, Batsakis JG (1986):Warthin's tumors (cystadenolymphoma) of salivary Gland: A clinicopathological investigation of 278 cases. *Oral surgery*.61:256-262.
6. Chidzonya MM.Protilla AL. (1995): Clinical pathological study of 206 cases in Zimbabwe .*Oral surgery,oral medicine and Oral pathology* ,79:6:747.
7. Chaudhry AP, Baby GR, and Watkins KU (1984): A clinicopathologic study of 189 intraoral minor salivary gland tumours. *J. Oral Med.* 93; 58
8. Randal S, Mark Palmar, et al (1989): Minor salivary gland tumours of the lip and buccal mucosa, *Laryngoscope j.* 99(1):6-9 · February 1989
9. Albert Abrams, Raymond Melrose (1978): Actinic cell tumors of minor salivary gland origin; *O Surgery, O Medicine O Pathology j.*46:2:PP.220.
- 10.Batsakis JG, Luna MA et al... (1991): basaloid monomorphic adenoma .*Am. Otol.Rinol, Laryngol.*100 (8):687-690.
- 11.Millon PR, Cussissi NJ, et al...(1982): Minor salivary glands Aclinicopathological study of 45 cases .*Oral Pathology*, 2:314.
- 12.Conley J,Tinsly P(1985):Treatment and prognosis of mucoepidermoid carcinoma in the pediatric age group . *Arch Otolaryngology*, 111:322-324.
- 13.Union International Control Cancer (1987) TNM classification of malignant tumors, Stuttgart, Springer-Verlay NY inc., pp30-31.
- 14.Toida M, Shimokawa K, et al. Intraoral minor salivary gland tumors: a clinicopathological study of 82 cases. *Int J Oral Maxillofac Surg.* 2005 Jul; 34(5):529-31.
- 15.Ito FA, Ito K,et al... Salivary gland tumors in a Brazilian population: a retrospective study of 496 cases. *Int J Oral Maxillofac Surg.* 2005 Jul; 34(5):532-7.
- 16.Waldron CA, El-Mofty SK, Gnepp DR. Tumors of the intraoral minor salivary glands: a demographic and histologic study of 426 cases. *Oral Surg Oral Med Oral Pathol.* 1988 Sep;66(3):323-33.
- 17.Otoh EC, Johnson NW, Olasoji H, Danfillo IS, Adeleke OA. Salivary gland neoplasms in Maiduguri, north-eastern Nigeria. *Oral Dis.* 2005 Nov;11(6):386-91.
- 18.Speight PM, Barrett AW. Salivary gland tumours. *Oral Dis.* 2002 Sep;8(5):229-40.
- 19.Olivia P., Nieves Almendros,et al...Minor salivary gland tumors: A clinicopathological study of 18 cases*Med Oral Patol Oral Cir Bucal.* 2008 Sep1;13(9):E583-9.
- 20.Eveson JW, Cawson RA (1985). Salivary gland tumours. A review of 2410 cases with particular reference to histological types, site, age and sex distribution. *J Pathol* 146: 51-58.
- 21.Young JA, Smallman LA (1990) Fine needle aspiration of the salivary glands. *Cytopathology*, 1; 25-33.