

## Tilted Implant Technique Solved Numerous Limitation of Straight Technique

Natheer A.Jassem. <sup>(1)</sup>  
Nabaa A. Ali. <sup>(2)</sup>

### Key words

dental implant,  
angled implant,  
upright, straight  
implant

### Abstract

Present of important anatomical structures in both upper and lower jaws make challenge during planning for implant procedures in the atrophic alveolar bone and to overcome this problem need bone augmentation which still complex and difficult procedures make it not accepted by large number of patient. In this study we spot light on the teeth implant in an area where short bone or insufficient height of alveolar ridge and inclined alveolar ridge so when we place implant should be tilted either palatelly, mesially or distally in bone around and we compare the success rate between angled placed implant and up right placed implant. 61 patients came to clinic asking for tooth or teeth implant, 300 implant fixtures were placed in both upper and lower arch 203 implants were straight and 97 were tilted. After 24 months follow up in the upper and lower alveolar arches of dental implant (97.54%) of upright implant were success and (97.94%) of tilted implant were success. Results indicate that the use of tilted implants effective and safe method over bone augmentation procedures and nerve transferring.

### Introduction:

An alternative to bone grafting and short implants following the loss posterior teeth and alveolar bone is the use of tilted implants<sup>(1)</sup>. Inserts fixture at positions off the vertical axis have been known as "tilted fixtures" or "off-axis implants" These might be put to keep away from different anatomical structures or to wipe out the requirement for bone graft and nerves repositioning procedure <sup>(2)</sup>. In case of alveolar bone of pre maxilla after extraction of teeth the Placement of fixtures in the premaxilla offers its own particular one of a kind set of difficulties. Not at all like the posterior ridge or the lower anterior, The bone of the premaxilla has a slant that tips the fixtures labially when set inside the limits of the available bone.

An examination of normal maxillary anterior teeth uncovers that the teeth have an adjustment in angulation at the cervical so that the roots follows the angulation of premaxilla however the coronal directed more vertically. At the point when a standard fixtures is put and the fixtures directed with the pivot of the normal tooth, the prosthetic parts is situated too far labially, particularly when the inclination of the bone is more extreme than ordinary that what we called triangle of bone <sup>(3,4)</sup>.

In cases of maxilla bone here with less volume and poor quality is often found in these areas, in addition to the existence of the maxillary sinus and restricted vertical space are two different hurdles encountered when setting fixtures in this area <sup>(5)</sup>. In addition to that, placement of implant in the molar or premolar areas are shorter than the ones situated in the incisive or canine areas<sup>(6)</sup> It is found that shorter fixtures have a higher failure rates than longer one. Thus, dental implants when placed in atrophic maxilla usually

(1) Specialist of maxillofacial surgery in al- Wasity hospital, Baghdad.

(2) Specialist of maxillofacial surgery in al- Wasity hospital, Baghdad.

results in a compromised biomechanical condition with a combination of short implants sited on a straight line in low quality bone in areas exposed to high loading force. <sup>(6,7)</sup> The solve for this problem by bone grafting or bone augmentation of maxillary sinus even though this procedure were described as effective in creating condition for implant placement <sup>(8,9)</sup>, the occurrence of several complications were reported in the literatures<sup>(10)</sup>. Tilted implant were used to overcome bone augmentation this procedure was proved by scientific.

Literature regarding implant success of survival in short and in medium terms, describing that the use of angled implants was not correlated to an increased in the resorption of bone <sup>(11)(12)</sup>. In case of mandible with high level of inferior dental canal and mental foramen consider as a limitation anatomical structure for long implant position, grafting alone seldom solve this clinical situations and is not able to be predicted in a gaining desired results ;so implant placement in the posterior and inferior alveolar ridge, nerve transferring may be necessary .With its post –surgical complications (ie,paresthesia), reposition of nerve may not be selected by the patient ,so that putting of implant with angled mesial to mental foramen is good idea in addition we can use long implant to accommodate loading force in the posterior region of mandible.<sup>(13)</sup>

### Materials and method:

Sixty one patients were came to privet clinic in Baghdad asking for implant for replacing missing tooth or teeth involve both upper and lower arches ,6 patients were completely edentulous, inclusions criteria were all patient with good health and immune-compromised patients were excluded from this study. All patient above 18 years old, the age range from (20 to 75) years with average (47.5). 35 female and 26 male then we examine patient intraorally.

Examine tools involve ;mirror ,probe ,inspection of alveolar ridge and palpation ,Local anesthesia infiltrate in area of missing tooth and measure the width of alveolar ridge bucco-palately or lingually

by bone gauge. (The width of bone should above 4.5 mm in diameter).

Radiographic examination which include; Periapical dental radiograph to see if there was any lesion in area of implant and orthopantograph (OPG} 1:1 magnification to estimate height of alveolar bone, level of nasal floor, sinus floor and distance of inferior dental nerve to alveolar ridge. The condition of bone clarified by cone beam computerized tomography (CBCT) to study 3 dimensions of bone in selected cases.

The system of implant were use in the study was Dentium (for dentist by dentist)system from south Korea which provide two angled abutment (15<sup>0</sup> and 25<sup>0</sup>) were available to make tilted implant possible ,surgical kit for hole preparation and fixture placement and also bone expander kit when necessary.

Treatment plane proceed if there was enough bone and straight implant placed in area of missing tooth or teeth, but incase with low level of maxillary sinus and high level of inferior dental canal and mental foramen, an angled implant were decided. The surgical procedure include alveolar crest flap ,exposure of bone ,hole preparation and fixture loading then suture with 000 silk suture and gingival former procedures was performed 4 to 6 months after implant placement (average 19 weeks) .After one month from gingival former placement the abutment placed over the implant .

### Results:

61 patients were 35 (57.4%) female and 26 (42.6%) male patients received 300 implant. From these 300 implants we decided to place 203fixtur straight within the bone. and 97 fixture tilted within the bone in relation to occlusal surface ,follow up patient after 6 months, 12 months, 16 months and 24 months examination of patient clinically and by x-ray (OPG), any mobility of fixtures or bone resorption exceed 2mm consider as failure implants, we use different length and diameter of implant, length were range from 7 to 14 and diameter (3.4,3.8,4.0and 4.5) were used and the number of each size as

appear in table below for axial implant as in table no.1.

All patients with low level of maxillary sinus or high level of inferior dental canal and mental canal whom refused to do bone augmentation or repositioning of mandibular nerve they are directed towards tilted implant if there was enough bone around these anatomical structures and the patients were told about these procedures.

The success rate of straight implant was (97.54%) and the success rate for tilted implant was (97.96%) after 24 months follow up and percentage of success and failure rate of implants in (fig1). Failure implant in case of straight implant were 2 in upper premolar area and 2 in lower premolar area and one in lower molar area .while in case of angled implant both are in premaxilla area .in some patient we use both angled and straight implant procedures in same arch which give good results as in fig.no.2. In fig no.3 we see how tilted implant which about 15 to occlusal plane in premaxilla region. The measurement of length of alveolar was achieved by (OPG) and (CBCT) as in fig 9 we see how tilted implant to distal side parallel to anterior wall of maxillary sinus to replace upper six on right side and upper second premolar in the left side and avoid shallow alveolar bone in area and we see the measure of bone anterior to maxillary sinus about 9.4 with inclination posteriorly while in area of upper six was less than 4 mm and if use straight implant in this area bone graft become inevitability.

### Discussion:

This study discusses an alternative mode of treatment in cases where there is too much of bone resorption which limited implant treatment and to avoid insertion of very short implant which susceptible to high rate of failure and avoid invasive procedures like bone augmentation and sinus lift. And In clinical record the most reported parameter to assess the viability of an implant -supported prosthetic part was the survival rate, which means whether the fixture is still physically in the mouth or has been evacuated and in

general the accepted criteria for the evaluation of implant success were, absence of clinical mobility, absence of pain and bone resorption less than 3mm. Various studies are supported this procedure strongly; most of these studies have demonstrate excellent success rate over period of time (1-10 years) with an average of success rate more than 95%. Aparicio (2001) <sup>(15)</sup> with follow up for 5 years had mention (93%) survival rate, Malo (2007) <sup>(14)</sup> had mention (97.8%) success rate Agliard (2010) with 30 months fellow up have (100%) success rate our result is not different from these value (97.96%) and its within that range of success and is acceptable within range of success rate of straight implant placement. Even the rate of success of tilted implant was more but the different was not significant (0.42). Various studies carried out regarding success rate of angulated implants have shown same or less amount of Cristal bone loss in comparison to axial implant <sup>(16)(17)(18)</sup>. However in many studies the authors use only full arch rehabilitation I mean over dentures while other study on partial edentulous arch, in our study involve both partially edentulous and complete edentulous arch (6 patient). so, the present study demonstrate that the use of tilted implants to rehabilitate maxilla and mandible could be a viable alternative to complicated surgery like bone augmentation in maxilla and nerve preposition in the mandible and give a good functional and aesthetic patients' satisfaction.

### Conclusion:

The benefit of tilted insertion is;

1. Stability even in least bone volume (longer fixture can be utilized)
2. Accepted clinical result.
3. Eliminates the requirement for bone replace.
4. Can normally be performed in patients with different medically compromised disease who are frequently contraindications for excessive surgery.
5. Prevent damage important vital structures.
6. Good prognosis. <sup>(16,19)</sup>.

**Recommendation:**

Long follow up with measure of bone loss around fixture after 5 years by CBCT is advisable and comparison with larger

angle implant (30) manufactured by other company.

Table (1)

Length of fixture(mm)	Width of fixture (mm)				sum
	3.4	3.8	4.0	4.5	
7	80	10	5	7	102
8	47	14	6	4	75
10	10	10	2	2	24
12	4	2	0	0	6
sum	147	36	13	13	203

Table (2)

Length of fixture(mm)	Width of fixture (mm)				Sum
	3.4	3.8	4.0	4.5	
7	8	6	3	3	20
8	41	7	2	1	51
10	8	5	0	1	14
12	9	4	0	0	13
Sum	66	22	5	5	98

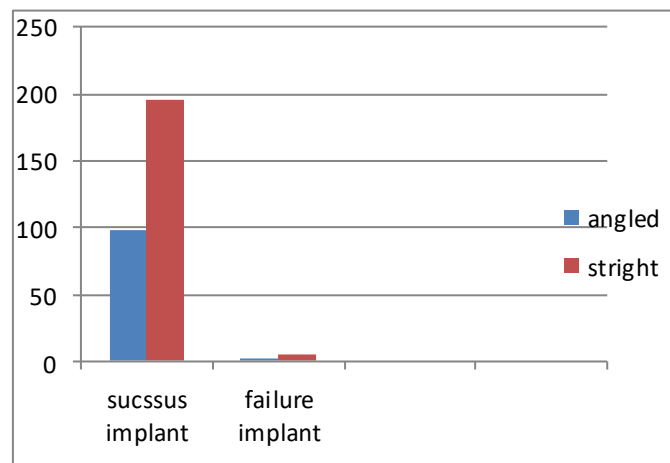


Fig (1)

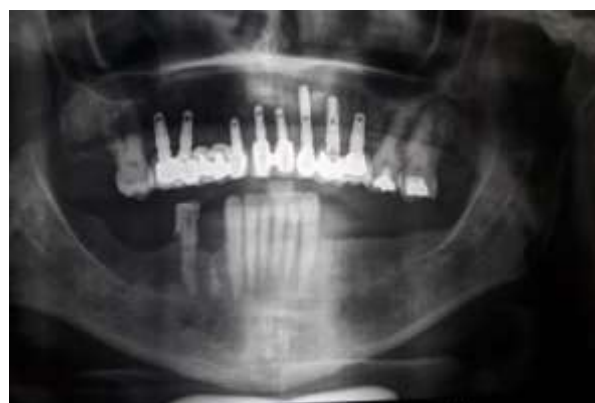

Fig (2)

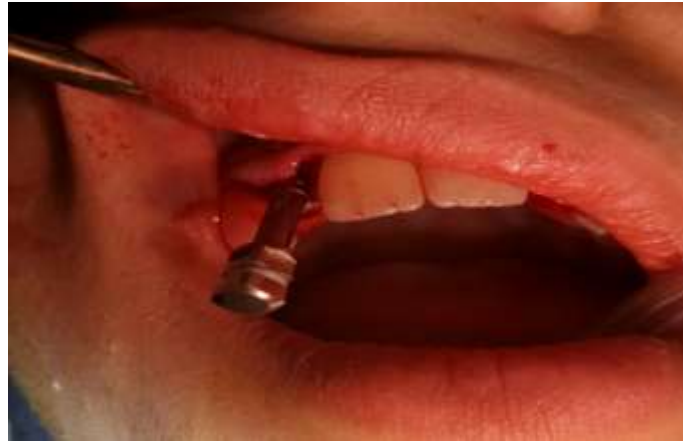

Fig (3)

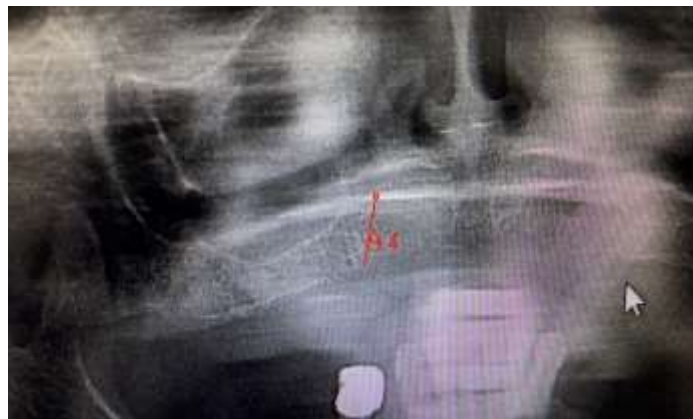

Fig (4)

## References:

1. Chrcahovic BR, Albrektsson T, et al... (2015) Tilted versus axially placed dental implants: a meta-analysis. *Dent. Feb*;43(3):149-170.
2. Gregori M, Douglas F.et al.. ;( 2008); Off-Axis Implant Placement for Anatomical Considerations Using the Co-Axis Implant. *Inside Dentistry*: web site
3. Ganz SD. (1995): The triangle of bone—a formula for successful implant placement and restoration. *Implant Soc.*; 5(6):12-60.
4. Ganz SD(2005). Use of conventional CT and cone beam for improved dental diagnostics and implant planning. *AADMRT Newsletter*, Spring Issue. March 29, 2006.
5. Tatum H. (1986)Maxillary and sinus implant reconstruction ,*Dent Clinic North Am*;30:217-229.
6. VanSteenbergher D, Lekholm U.et al...1990)The applicability of Osseo integrated oral implants in rehabilitation of partial edentulous :a prospective multicenter study of 558 fixtures. *Int J Oral Maxillofacial Implant*; 5:275-281.
7. Rangert B, Sennerby L. et al..Load factor analysis for implants in the posterior maxilla. In: Jensen T,ed.*The sinus bone graft* .Chigago:Quntessence, 1999:167-178
8. 4. 8-S. S. Wallace and S. J. Froum, (2003) “Effect of maxillary sinus augmentation on the survival of endosseous dental implants. A systematic review *Annals of Periodontology*, vol. 8, no. 1, pp. 328-342.
9. M. Del Fabbro, G. Rosano, and S. Taschieri (2008). “Implant survival rates after maxillary sinus

- augmentation,” *European Journal of Oral Sciences*, vol. 116, no. 6, pp. 498
10. A. Katranji, P. Fotek, and H. L. Wang, (2008) “Sinus augmentation complications: etiology and treatment,” *Implant Dentistry* vol. 17, no. 3, pp. 338-348
  11. L. Francetti, D. Romeo, S. Corbella, S. Taschieri, and M. Del Fabbro (2012) “Bone level changes around axial and tilted implants in full-arch fixed immediate restorations” *Clinical Implant Dentistry and Related Research*, vol. 14, no. 5, pp. 650-654
  12. P. Malo, M. de Araujo Nobre, A. Lopes, C. Francischone, and M. Rigolizzo, ““All-on-4” immediate-function concept for completely edentulous maxillae: a clinical report on the medium (3 years) and long-term (5 years) outcomes,” *Clinical Implant Dentistry and Related Research*, vol. 14, no. 1, 40 2012
  13. Gregori M, Kurtzman, et al ..(2011); Off-axis implant placement for anatomical consideration using the co axis implant .*International Dentistry* 26, 4.779.
  14. Malo P, De Arajo Nobre M, Rangert B. Implants placed in immediate function in periodontally compromised sites: a five-year retrospective and one-year prospective study. *J Prosthet Dent*.2007;97(6 suppl):S86-S95.
  15. Aparicio C, Perales P, Rangert B. Tilted implants as an alternative to maxillary sinus grafting: a clinical, radiologic, and periotest study. *Clin Implant Dent Relat Res*. 2001;3(1):39-49.
  16. Rosen A, Gynther G. Implant Treatment Without Bone Grafting in Edentulous Severely Resorbed Maxilla: A Long-Term Follow-Up Study. *Journal of Oral and Maxillofacial Surgery*.2007;65(5):1010-17.
  17. Tomatis M, Calandriello R. Simplified treatment of the atrophic posterior maxilla via immediate/early function and tilted implants: A prospective 1-year clinical study. *Clinical Implant Dentistry and Related Research*. 2005;7(1):S1-12.
  18. Clerico M, Agliardi E, Ciancio P, Massironi D. Immediate loading of full-arch fixed prostheses supported by axial and tilted implants for the treatment of edentulous atrophic mandibles. *Quintessence international*. 2010;41(4):287.
  19. Bellini CM, Fabbro MD, Romeo D, Francetti L. Tilted Implants for the Rehabilitation of Edentulous Jaws: A Systematic Review. *Clinical Implant Dentistry and Related Research*. 2012;14 (4):614.