

Evaluation the Quality Three Different Obturation Technique Using Multi-Slice Computed Tomography: An In-Vitro Study

Huda A. Abdullallah BDS, MSc. ⁽¹⁾

Omar B. Taha BDS, MSc. ⁽²⁾

Ahmed M. Jasim BDS, MSc. ⁽³⁾

Key words

obturation
technique, voids,
multi-slice ct.

Abstract

After endodontic space has been completely cleaned, shaped and disinfected, a three-dimensional obturation of this space will be the ultimate objective of endodontic therapy. With a durable three dimensional obturation any communication with the periodontium will be eliminated and prevented. The aim of this study was to use multi-slice CT scanning to determine: (i) number of voids (ii) diameter or length of voids and (iii) presence of voids at material/tissue interfaces in root canals obturated with: (a) E & Q Master (b) Lateral Condensation, and (c) Soft Core system. Thirty freshly extracted human mandibular premolar teeth were used in this study. After preparation of the root canals, the teeth were divided into three groups with 10 teeth in each groups. G1 obturated with E&Q master, G2 obturated with Lateral Condensation, and G3 was obturated with Soft Core. GuttaFlow was used as sealer for all groups. After obturation all the specimen were analyzed with multi-slice CT, the data obtained was statistically analyzed using ANOVA test followed by Duncan's multiple range test ,a value of $p < 0.05$ was considered statistically significant. Voids are observed in all groups, Neither technique was free of voids or perfectly smooth. Overall, the canals that obturated with E&Q master showed the lowest number of voids (3.0), whereas those obturated with lateral condensation showed the highest number (3.9) and the differences was statistically significant. The canals that obturated with Soft core showed the highest mean of voids diameter (0.77 mm) , whereas those obturated with E&Q master and lateral condensation had the lowest mean (0.62 mm and 0.61 mm) respectively, and the differences were statistically significant. The percentage of outer voids was higher for all techniques than the inner voids. The presence of inner voids was the highest in canals that obturated with soft core system (9.230%). Conclusion: E&Q master of obturation show the lowest number of voids. Obturation with Soft core show the highest mean of voids diameter. In all obturation techniques, the outer voids was higher than inner voids.

Introduction

After endodontic space has been

completely cleaned, shaped and disinfected, a three-dimensional obturation of this space will be the ultimate objective of endodontic therapy. With a durable

(1)Lecturer, Department of Conservative Dentistry, College of Dentistry, University of Tikrit.

(2)Ass. Lecturer, Department of Oral Diagnosis , College of Dentistry, University of Tikrit.

(3)BDS, MSc. Department of Conservative Dentistry, Al Mamoon Center of Dentistry.

three dimensional obturation any communication with the periodontium will be eliminated and prevented⁽¹⁾. The current accepted method of obturation of prepared canals employs the use of a solid or a semisolid core such as gutta-percha and a root canal sealer. Gutta-percha has no adhesive qualities to dentine regardless of obturation technique used. Therefore, use of root canal sealer along with solid core plays a major role in achieving the hermetic seal by filling the accessory root canals, voids, spaces and irregularities and hence reducing the chances of failure of root canal treatment⁽²⁾. Ingle found that nearly 60% of endodontic failures were due to the incomplete obturation of the root canal system⁽³⁾. Among numerous obturation techniques and filling materials available, gutta-percha continues to be the material of choice, owing to its unique chemical and physical properties⁽⁴⁾. Lateral condensation technique has proven to be a very popular technique utilizing gutta-percha filling material; however its ability to conform to the internal surfaces of the root canal has been questioned⁽⁵⁾. Thermafil system can produce a homogenous mass of gutta-percha and recently, similar products were introduced: soft core. The Soft-Core System uses a similar strategy to achieve root canal obturation. The Soft-Core obturator consists of a plastic core which is coated with thermoplastic alpha phase gutta-percha. It offers many advantages such as the reduction in chair-side time and rapid set of the gutta percha⁽⁶⁾. GuttaFlow is a root canal filling paste that is a modification of RoekoSeal sealer. Guttaflow contains gutta-percha particles as filler. It is eugenol free radiopaque form which can be injected into root canals using an injectable system in which gutta-percha in powder form is combined with resin sealer in one capsule⁽²⁾. A variety of thermoplasticized gutta-percha techniques have been introduced recently and a number of investigations have evaluated the apical seal obtained by these techniques. Computed Tomography and Micro Computed Tomography are currently the leading technologies for endodontic research⁽⁷⁾. with spiral computed tomography three dimensional

volume analyses are possible without sectioning the specimen and thus avoiding the loss of material during sectioning⁽⁸⁾. And it is possible to reconstruct overlapping structures at arbitrary intervals and thus the ability to resolve small objects is increased⁽⁹⁾. The aim of this study was to use multi-slice CT scanning to determine: (i) number of voids (ii) diameter or length of voids and (iii) presence of voids at material/tissue interfaces in root canals obturated with: (a) E & Q Master (b) Lateral Condensation, and (c) Soft Core. and GuttaFlow was used as sealer for all groups.

Material and Methods

We selected 30 freshly extracted human mandibular premolars with single straight canal for this study. These teeth were mature and non-carious and has been extracted for orthodontic reasons. Any soft tissue remnant on the root surface will be removed with sharp periodontal curette and stored in 0.1 % thymol solution at room temperature⁽⁹⁾.

Tooth Preparation

Following access cavity preparation, the working length was determined by inserting #10 k-file into the canal until it was just visible at the apical foramen, then subtracting 1 mm from the measured length. The canals were then instrumented using standard step-back technique with k-filles (Dentsply, Maillefer, Switzerland). Root canal irrigation was performed using 5.25% NaOCl.

Obturation of the Root Canals

After drying of the canals with paper points, the teeth were randomly divided into three groups of 10 teeth each for obturation with different technique and GuttaFlow used as sealer for all groups.

Group 1 (E & Q Master): Cordless Pen tip was pre-fitted in the canal, then the stopper was used to mark 5 mm short of the working length. GuttaFlow was applied into the canal before and the

master cone was inserted to the measured working length. The cordless heat-carrier pen was then used to cut the excess gutta percha over orifice. For backfilling, the gutta percha bullets were loaded in the gun and the temperature of cordless gun was regulated to (170°C) and the flow of material was checked outside the canal.

Group 2 (Lateral Condensation): GuttaFlow was applied into the canal before and the master cone was inserted in the canal after which endodontic finger spreader was introduced in the canal with the master cone in place for 5 seconds. An accessory cone (size #20) was placed, after dipping in GuttaFlow sealer.

Group 3 (Soft Core system): While the obturator was heated, GuttaFlow sealer was applied into the canal. When the oven indicated that the obturator was ready with a beep sound and a green diode light, the obturator was carefully removed from the oven. The plasticized Soft-Core was then inserted to the apical stop with apical pressure. After the gutta percha had been cooled, the handle and insertion pin were removed by a bending motion.

All the experimental specimens were mounted on ELIZA test micro plate by wax sheets and placed on the couch of the computed tomography machine for analysis. it was moved longitudinally towards the Gantry at the pitch1 and exposure 120kv and 180ma was done for one second. CT scan machine which was used in this study is multi-slice computed tomography scanner (Brilliance 64) manufactured by Philips Electronics U.S.A. in Tikrit teaching hospital.(fig. 1). From the apex of the root, six horizontal sections of 2 mm thickness were made which was followed by three dimensional reconstruction of the sections. The following parameters were recorded:

1. Number of voids
2. Diameter or length of voids
3. Presence of voids at material/tissue interfaces in root canals.

Statistical Analysis

The data was statistically analyzed using

the Minitab program. One-Way analysis of variance (ANOVA) was used. The differences of the means were analyzed by Duncan's multiple range test and a value of $p < 0.05$ was considered statistically significant.

Results

Mean (\pm SD) number of voids are shown in table 1. Voids are observed in all groups, Neither techniques was free of voids or perfectly smooth. Overall, the canals that obturated with E&Q master showed the lowest number of voids (3.0), whereas those obturated with lateral condensation showed the highest number (3.9) and the differences was statistically significant. In the apical third, at 2 mm and 4 mm, the canals that obturated with E&Q master showed the lowest mean of number of voids(2.0) with no significant differences from the canals that obturated with soft core (2.33). There was statistically significant differences in mean of number of voids between E&Q master and Soft core with canals that obturated with lateral condensation. In the middle third, at 6mm and 8mm, canals that obturated with Soft core was the highest mean of voids number (4.0) with significant differences from other group. In the coronal third, at 10 mm and 12 mm, canals that obturated with lateral condensation technique was the highest mean(5.0, 7.0), whereas those obturated with E&Q master showed the lowest mean (3.0,5.0) with significant differences among the three groups. Mean and standard deviation of voids diameter demonstrated in table 2. Overall, the canals that obturated with Soft core showed the highest mean of voids - diameter (0.77 mm) , whereas those obturated with E&Q master and lateral condensation had the lowest mean (0.62 mm and 0.61 mm) respectively. The differences was statistically significant. In table 3, the presence of inner voids was the highest in canals that obturated with soft core (9.230%) where as those obturated with lateral condensation showed the lowest (2.816 %).

Discussion

The detection of voids is important as it has been established that adequate filling of the canal space after instrumentation is one of the essentials for the success of root canal therapies. However, successful root canal treatments in general suggest that the presence of defects may not always lead to endodontic failures. Still, it is possible that obturation defects may serve as niches where viable microorganisms may lodge. In addition, when those defects form continuous structures to the apex, they may provide a route for the migration of microorganisms to the periradicular tissues thus causing re-infection of the canal or the periradicular areas. Some studies have concluded that some bacteria may persist in the root canal even after obturation as a result of inadequate canal preparation and debridement, and apical or coronal leakage through defective restorations^(3, 11). Such persistent bacteria have often been cited as the cause of most endodontic failures, rather than whether the root canal was satisfactorily obturated or not⁽¹²⁾. Multi-slice computed tomography was chosen over other diagnostic aids for analysis of the specimens because of its various advantages like three-dimensional volume measurements are possible without sectioning the specimens and thus avoiding the loss of material during sectioning and three-dimensional reconstructions. Vannier et al demonstrated the feasibility of spiral volumetric CT for quantitative study of oral hard tissues in the presence of metal restorations⁽¹³⁾. Nandini *et al.* used spiral CT for the volumetric analysis to assess the efficiency of two calcium chelators namely 17% EDTA solution and 10% citric acid combined with ultrasonic agitation, in the removal of calcium hydroxide placed as an intracanal medicaments⁽⁸⁾. Senthil et al conclude the spiral computed tomography was very useful tool for checking the density of obturation in endodontics.⁽¹⁴⁾ In this study, Lowest number of voids was shown by E&Q master followed by soft core. Lateral condensation showed the highest number of voids. This result agree with Kqiku et

al, found that All the thermoplastic filling systems tested demonstrated acceptable root canal filling and good adaptation to the root canal wall with no statistically significant difference between them and in comparison to lateral condensation when compare five different obturation techniques (thermafil, ultrafil, obturaII, warm vertical condensation and lateral condensation techniques)⁽¹⁵⁾. Studies have shown that thermoplastized guttaperch techniques reproduce the internal root canal anatomy better than lateral condensation, including a better dentine wall adaptation, and usually produce a more homogeneous mass of gutta-percha when compared to lateral condensation. Both E&Q master and soft core are thermoplastized gutta-percha obturation techniques that claim possess these advantages over the cold lateral condensation technique^(16,17). Senthil et al, compare density and homogeneity of root canal obturation with GuttaFlow using backfilling technique and lateral compaction technique using spiral CT, and found that lateral condensation technique was inferior in the apical and middle third⁽¹⁴⁾. Chokkalingam et al, found that conventional lateral condensation technique showed maximal inadequacy of obturation and thermafil obturation technique showed the least inadequacy of obturation when the volume of the specimens were calculated and reconstructed⁽¹⁸⁾. This can be explained by the fact that lateral condensation unable to adapt to the walls as explained by Schilder and unlike vertical condensation, does not create a homogenous mass of guttapercha⁽¹⁹⁾. Gorden et al indicated that the single cone results were not significantly different from the lateral condensation results, indicating that the method was comparable with lateral condensation⁽²⁰⁾. On the other hand, thermoplasticized gutta-percha techniques on application of heat, flows and adapt well into the walls of the root canal. Application of heat by plugging further compensates for any voids within the mass and results in a whole compact mass with good marginal adaptation to the canal walls. This is effectively depicted in the difference in the number of voids between

the EQ Fil and lateral condensation technique. Brayton et al reported that in lateral condensation technique, incomplete fusion of gutta-percha cones, lack of surface adaptations, voids and spreader tracks were seen. Voids in the core of gutta-percha were due to the accessory gutta-percha points not seating to the full length of the spreader penetration⁽²¹⁾. Eguchi et al also reported that this technique result in excessive amounts of sealer and apical voids⁽²²⁾. Qureshi et al state that although lateral condensation technique is still the most widely used technique in the world but in terms of quality, obturation by thermafil technique is better as it produces less voids and more radiodense obturation⁽²³⁾. In the present study, Soft core showed the highest mean of voids diameter and highest percentage of inner voids when compared with E&Q master and lateral condensation. These inner voids were remarkably

enclosed within the material, and hence exhibited good adaptation to dentinal walls. Only Critique of carrier based obturation is the possibility of the plastic carrier being stripped of gutta-percha, especially in the apical third allowing the carrier to be in direct contact with the canal walls. Jarrett et al found that root canals filled with thermafil revealed the carrier directly against the wall of the canals⁽²⁴⁾.

Conclusion

1. E&Q master obturation technique show the lowest number of voids.
2. Obturation with Soft core system show the highest mean of voids diameter.
3. In all obturation techniques, voids occur between filling material and dentine (outer voids).

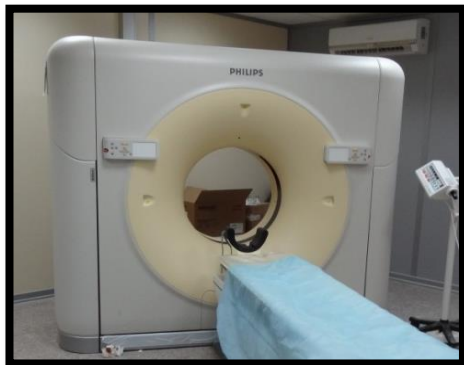

Fig.(1):- Multi-slice computed tomography machine (PHILIPS Brilliance 64) used for analysis of the specimens.

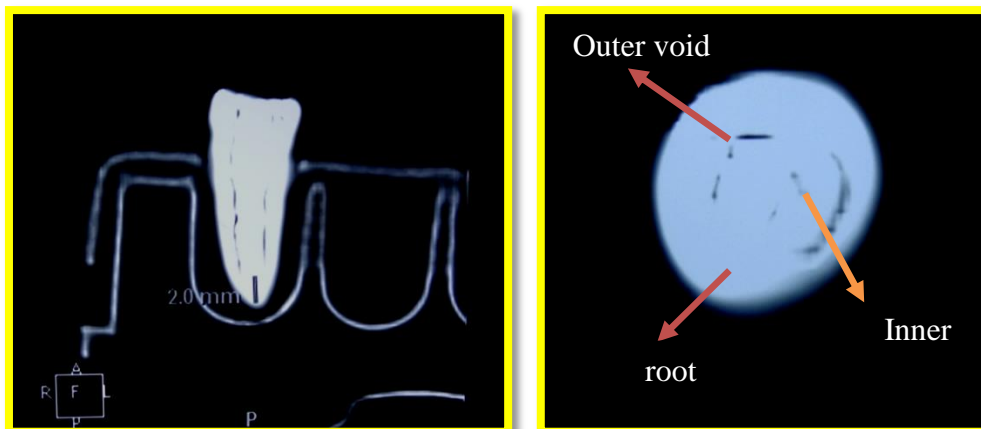


Fig.(2):- 2D slice showing root filling with voids

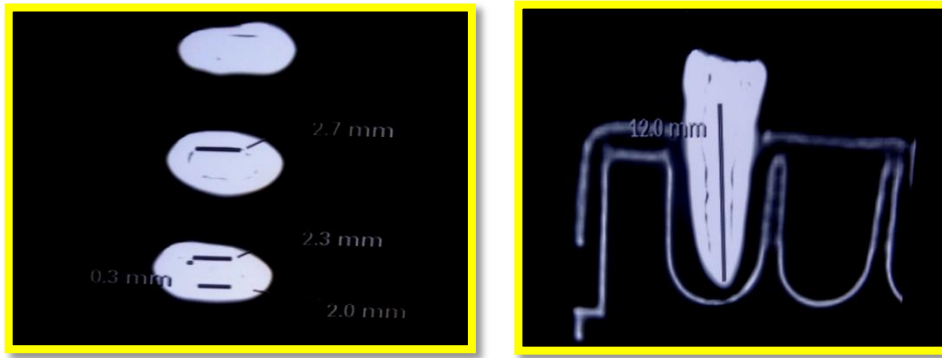


Fig.(3):-2D slice showing the measurements of voids diameter.

Table(1):- Mean and Standard Deviations of Number of Voids at each Section Level for Different Obturation Techniques.

Section level	G 1 E&Q	G 2 Lateral condensation.	G 3 Soft core
2 mm	2.0 ± 2 E	2.67 ±1.528 de	2.33 ± 2.517 E
4 mm	2.0 ± 1 E	3.0 ± 1 d	2.33± 1.528 E
6 mm	3.0 ± 1 D	3.0 ± 0 d	4.0± 1.732 C
8 mm	3.0 ± 0 D	3.0 ± 1 d	4.0 ± 2 C
10 mm	3.0 ± 0 D	5.0 ± 2 b	4.0 ± 1.732 C
12 mm	5.0 ± 1 B	7.0 ± 0 a	5.0 ± 0 B
overall	1.0 ± 0.833 B	3.95± 0.921 a	3.61± 1.584 A

F-test=2.72 * P≤0.05
Different letters indicate significant differences

Table(2):-Mean and SD of Diameter of Voids (mm) in different obturation techniques.

Section level	G 1 E&Q	G 2 Lateral condensation	G 3 Soft core
2 mm	0.33 ± 0.1862 A	0.42 ±0.2964 A	0.41 ±0.1676 a
4 mm	0.35 ± 0.1643 B	0.38 ±0.2369 B	0.55 ±0.2149 a
6 mm	0.53 ±0.1936 A	0.64 ±0.2833 A	0.51 ±0.4174 a
8 mm	0.70 ±0.3708 A	0.68 ±0.4076 A	0.85 ±0.6097 a
10 mm	0.75 ±0.3812 B	0.71 ±0.5397 B	1.0 ±0.9959 a
12 mm	0.75 ±0.5805 B	0.66 ±0.5151 B	0.97 ±0.5561 a
Overall	0.62 ±0.4138 B	0.61 ±0.4379 B	0.77 ±0.6289 a

Different letters indicate significant differences
F- test =2.19* p ≤0.05

Table(3):-Presence of Voids -percentage in different obturation techniques.

<i>Groups</i>	Inner voids %	Outer voids %	Total voids %
<i>G1 E&Q master</i>	3.703 %	96.297%	100
<i>G2 Lateral Condensation</i>	2.816%	97.184%	100
<i>G3 Soft Core system</i>	9.230%	90.77%	100

References

- 1-Ingle JL. Endodontics Lea and Febiger, Philidelphia, 3rd edition, 1985.
- 2-Garg N, Garg A. textbook of endodontics. 2nd edition, 2010 chapter 18 ,265p.
- 3-Ingle JJ. Obturation of the radicular space. 5th. Endodontics; 2002, p. 571
- 4-Gulsahi K, Cehreli ZC, Onay EO, Tasman-Dagli F, Ungor M. Comparison of the Area of Resin-based Sealer and Voids in Roots Obturated with Resilon and Gutta-Percha. JOE 2007; 33: 1338-1341.
- 5-Gençoğlu N, Oruçoğlu H, Helvacioğlu D. Apical leakage of different gutta-percha techniques: thermafil, js quick-fill, soft core, microseal, system b and lateral condensation with a computerized fluid filtration meter. Eur J Dent 2007; 1: 97-103.
- 6-Özer SY, Aktener BO. Outcome of Root Canal Treatment Using Soft-Core™ and Cold Lateral Compaction Filling Techniques: A Randomized Clinical Trial. J Contemp Dent Pract 2009; 10: 74-81.
- 7-Uyanik OM. Comparative Evaluation Of Three Nickel- Titanium Instrumentation Systems In Human Teeth Using Computed Tomography. Journal Of Endodontics 2006; 32:668-70.
- 8-Nandini S, Kandhaswamy D. Removal Efficiency Of Calcium Hydroxide Intra Canal Medicament With Two Calcium Chelators: Volumetric Analysis Using Spiral CT – An In Vitro Study. Journal of Endodontics 2006; 32: 1097-1100. 1. Ray HA, Trope
- 9-Gopikrishna V, Bhargavi N. Endodontic Management of Maxillary First Molar with a Single Root and Single Canal Diagnosed With the Aid of Spiral CT: A Case Report. Journal of Endodontics 2006; 32:687-90.
- 10-Lipski M. Root surface temperature rises in vitro during root canal obturation with thermoplasticized gutta percha on a carrier by injection. JOE 2004; 30: 441-3.
- 11-Nair PN, Sjogren U, Krey G, Kahnberg KE, Sundqvist G: Intraradicular bacteria and fungi in root-filled, asymptomatic human teeth with therapy-resistant periapical lesions: a long-term light and electron microscopic follow-up study. Journal of Endodontics 1990; 16: 580-8.
- 12-Lin LM, Rosenberg PA, Lin J: Do procedural errors cause endodontic treatment failure? Journal of the American Dental Association 2005; 136: 187-193.
- 13-Vannier MW, Hildebolt CF, Conover G, Knapp RH, Yokoyama-Crothers N, Wang G. Three-dimensional dental imaging by spiral CT, A Progress report. Oral surg Oral Med oral Pathol oral Radiol Endod. 1997;84:561-70.
- 14-Senthil K p , Vivekananda Pai A. R. ,Kundabala M. A Three-Dimensional Evaluation of Density and Homogeneity of Root Canal Obturation with Gutttaflow® using Backfilling Technique in Comparison with Conventional Lateral Compaction Technique using Spiral Computed Tomography - An In Vitro Study. Endodontology.2008; 20(2): 43-50.
- 15-Kqiku L, Weiglein A, Städtler P. A Comparative Study of Five Different Obturation Techniques. Acta Stomatol Croat. 2006; 40: -11.
- 16-Gencoglu N. Comparison of 6 different gutta-percha techniques Part II: Thermafil, JS Quick fill, Soft core, Microseal, System B, and Lateral condensation. Oral Surg Oral Med Oral Pathol Oral Radiol Endod 2003; 96: 91-95.
- 17-Budd CS,Weller RN,Kulld JC. A comparision of thermoplastized injectable guttapercha obturation techniqes. J Endod 1991:17:260-264.
- 18-Chokkalingam M, Ramaprabha, and Kandaswamy D. Three-dimensional helical computed tomographic evaluation of three

obturation techniques: *In vitro* study. J Conserv Dent. 2011 Jul-Sep; 14(3): 273–276.

19-Bal AS, Hicks ML, Barnett F. Comparison of laterally condensed .06 and .02 tapered gutta-percha and sealer in vitro. J Endod. 2001;27:786–8.

20-Gordon MPJ, Love RM, Chandler NP. An evaluation of .06 tapered gutta-percha cones for filling of .06 taper prepared curved root canals. Int Endod J. 2005;38:87–96.

21-Brayton SM, Davis SR, Goldman M. Gutta-percha root canal fillings. Oral surg oral med oral pathol 1973; 35_226-231.

22-Eguchi DS, Peter D, Hollinger JO, Lorton L. A comparison of the area of root canal space occupied by gutta-percha obturations techniques using procosol sealer. J Endod 1985; 11:66-75.

23-Qureshi B. Munir B. Akbar I. A comparison of thermafil and lateral condensation Techniques in obturation of root canal systems. Pakistan Oral & Dental Journal. 2012; 32(3).

24-Jarrett IS, Marx D, Karmazin M, Lavin M, Gound T. Percentage of canal filled in apical cross section-an in vitro study of seven obturation techniques.int Endod J.2004;37 :392-8.