

## Evaluation of Carisolv in the Chemico-Mechanical Removal of Carious Dentine in Primary Molars (In vivo study)

Huda E.A. Al-Rubaye BDS, MSc.<sup>(1)</sup>

### Key words

chemo-mechanical, carisolv, arrested caries, soft caries.

### Abstract

Caries removal by the Chemo-mechanical technique involves the application of chemical agents, to cause a selective softening of the carious dentine and facilitate removal by gentle excavation. Carisolv is one such new chemical agent used in this minimal invasive technique of carious dentine removal. The aims of this study was to evaluate the efficacy of Carisolv in the chemo-mechanical removal of carious dentine in primary teeth, the time taken for caries removal and to evaluate the restorations radiographically. Forty primary 1<sup>st</sup> and 2<sup>nd</sup> molars with dentinal carious lesions were excavated using this technique of caries removal. After isolation of the involved tooth, the Carisolv "new gel" marketed by Mediteam Dental AB (Goteborg, Sweden) was applied then the superficial softened carious dentine was gently excavated and scraped using a spoon excavator, the procedure repeated until the cavity was free from caries and the cavity was checked for remaining caries using an explorer. The time taken for the removal of carious dentine, beginning from the application of the gel until the completion of the procedure was evaluated using a stopwatch. After the placement of the restoration an intra-oral periapical radiograph was taken for immediate evaluation and after a period of six months, the longevity of the restorations and the presence of secondary caries at the restoration- dentine interface were evaluated radiographically. The statistical analysis of the results showed that the soft carious dentine was removed more effectively than the hard carious dentine and the removal of the soft carious dentine required a shorter period of time ( $4.96 \pm 0.99$ ) minutes when compared to the removal of hard carious dentine ( $6.09 \pm 1.04$ ) minutes and on radiographic evaluation of the restoration, none of the treated lesions showed the presence of secondary caries. In conclusion, the chemico-mechanical caries removal technique using Carisolv proved to be an effective atraumatic treatment modality with potential interest for use in clinical pediatric dentistry.

### Introduction

Pain during the invasive treatment of dentinal caries is quite a common phenomenon often inducing fear and anxiety in children. The minimal removal of infected carious dentine, together with the use of a therapeutic restorative

material is a fundamental requirement of modern operative dentistry. Minimal intervention dentistry eliminates the pain associated with the removal of carious dentine, thereby providing a gentle introduction to dental treatment in children<sup>(1)</sup>. The principles of modern cavity preparation were first defined in 1896 by

(1) Ass. Lecturer, Department of POP, College of Dentistry, Al-Mustansiria University.

Dr. G.V. Black, a man considered by many to be the "father of modern restorative dentistry". When his original sequence of cavity preparation was described, "Extension for Prevention" of recurrent decay was one of the most important considerations of cavity design. However, the degree of cavity extension is considerably less today because of the realization that caries, primary or secondary, can be more effectively controlled and prevented by greater emphasis on oral hygiene by the patient. In recent years, with the advent of adhesive restorative materials and the subsequent developments in minimal cavity design, the widely accepted principle of "Extension for Prevention" in the operative treatment of carious lesion has been challenged and is now considered too destructive method for caries removal<sup>(2)</sup>. The other techniques used in carious dentine removal include the mechanical rotary or non-rotary instruments, chemo-mechanical caries removal system and lasers. The non-rotary, non-invasive techniques include air-abrasion, air-polishing, ultrasonic and sono-abrasion<sup>(3)</sup>. The chemo-mechanical caries removal system, based on the principle of minimal invasive dentistry involves the application of substances like Caridex and Carisolv<sup>(2,3,4)</sup>. In the 1980's, the chemo-mechanical caries removal system involving the application of (Caridex™, USA) was tried, but its use in clinical practice was limited because of difficult clinical handling, the need for increased volumes of the solution, prolonged period of time to complete the procedure, and a short shelf-life of opened packages<sup>(5,6)</sup>. To overcome these limitations, a new product for chemo-mechanical caries removal named Carisolv was launched with renewed interest. It selectively removes carious dentine, thereby avoiding the painful removal of sound dentine. It involves the chemical softening of carious dentine within a short period after application, followed by removal with gentle excavation<sup>(3,7,8)</sup>. Carisolv "new gel" is a gel based chemico-mechanical caries removal system, it consists of two basic components, one is a transparent liquid containing sodium hypochlorite solution

0.95%, the other component is uncolored gel containing three amino acids (glutamic acid, Leucine, Lysine), sodium chloride, Na-CMC (Carboxymethylcellulose) to enhance the viscosity, sodium hydroxide provides a pH of 11 and purified water act as a vehicle<sup>(9,10,11)</sup>. To optimize the efficiency and effectiveness of Carisolv gel with respect to chemical caries dissolution and minimal effect on healthy dentine, a new, modified gel has been developed. The original Carisolv red gel contains three differently charged amino acids which are mixed with sodium hypochlorite prior to treatment. The new Carisolv gel has no color agent, it contains half the concentration of amino acids and a higher concentration of sodium hypochlorite<sup>(12,13,14)</sup>. Special hand instruments are also included in the Carisolv system for the removal of dissolved carious dentine (Figure 1). The excavation of deep carious lesions carries the risk of perforating the pulp chamber because Carisolv hand instruments could cause iatrogenic damage and Carisolv might then come into contact with vital pulp tissue. Until now, there has been no data available about the reaction of vital pulp tissue to the 'new' Carisolv gel<sup>(15,16)</sup>. However, previous research has shown that the original Carisolv caused no, or only minor deviations to pulp tissue after direct or indirect contact<sup>(17)</sup>. It is still necessary to examine possible reactions of pulp tissue in direct contact with Carisolv 'new gel' in order to exclude local toxic effects. Before applying Carisolv 'new gel' to deep cavities it must be ensured that there is no enhanced risk to vital pulp tissue<sup>(18)</sup>. No study has been attempted on a population of Iraqi children to evaluate the efficacy of Carisolv in the removal of carious dentine in the primary teeth, therefore, this study was conducted with the following aims and objectives:

1. To clinically evaluate the efficacy of Carisolv in the removal of carious dentine in primary teeth.
2. To evaluate the time taken for caries removal.
3. To radiographically evaluate the restorations, immediately and after a period of six months.

## Materials and Methods

Twenty two healthy children of both sexes with an average age of (5-10years) were included in this study. They came to dental clinic (private dental clinic in Baghdad city) for routine dental examination and treatment. Questionnaires were taken from parent's children included complete information about general health and complain, parental consent was obtained prior to the procedure, accordingly, forty primary 1<sup>st</sup> and 2<sup>nd</sup> molars having dental caries on the occlusal surface (class I) were restored using this technique of excavation of carious dentine. The following teeth were excluded prior to selection ( badly carious teeth, teeth with proximal caries, teeth with sings and symptoms (history) of pulp involvement). The procedure was done without local anesthesia. After isolation of the involved tooth, drilling preferably was used when the cavity needs to be opened up, for adjustment of cavity periphery or when there were large amounts of caries and when the risk to affect healthy tissue was minimal, however, drilling was used to increase the view or accessibility of the cavity. Carisolv "new gel" marketed by Mediteam Dental AB (Goteborg, Sweden) is a viscous substance for chemo-mechanical caries removal. The material was used according to manufacture instructions. The delivery system is termed as the "new Carisolv twin Multimix Syringe Dispenser" (Figure 2). It mixes the two components in equal proportions, resulting in the active gel, which is then applied onto the carious lesion. It consists of 3 parts (Figure 3): (1) a syringe containing the dual components of Carisolv, (2) static mixer that mixes the two components and (3) a plunger to dispense the mixed gel. The Carisolv gel was mixed using the Multimix Syringe Dispenser. The required amount of active gel (few drops) was dispensed into a suitable container , drops of the gel were removed from the container with a Carisolv instrument figure (1), and It was then applied to the carious dentine. The carious lesion was completely soaked by the gel to let chemistry work for at least 30

seconds but not more than 60 seconds. Following this, Carisolv instruments were selected to match the size, position and accessibility of the cavity. The superficial softened carious dentine was gently excavated and scraped using a spoon excavator, flushing or drying the cavity was avoided. On application, the gel was clear, but became opaque or cloudy when it was contaminated with the debris during removal. Then gradually new gel was added and continued excavated and scraped. The procedure was repeated until the gel was no longer cloudy and the cavity surface was felt hard with the excavator. The cavity was checked for remaining caries using an explorer, when the cavity was felt free from caries it was wiped with a moistened cotton pellet or rinsed with water.

## The Evaluation Criteria

The efficacy of caries removal was then evaluated by the visual and tactile criteria<sup>(19)</sup>. The visual criteria included the absence of any discoloration. The tactile criteria included the smooth passage of the explorer and absence of a catch or a "tug-back" sensation. The efficacy of caries removal was graded as complete, partial, and incomplete<sup>(7)</sup> and numerically scored 0, 1, 2, 3, 4, 5 (Table 1).The time taken for the removal of carious dentine, beginning from the application of the gel until the completion of the procedure was evaluated using a stopwatch. After the placement of the restoration (in this study amalgam restoration was used to restore the teeth), an intra-oral periapical radiograph was taken for immediate evaluation. After a period of six months, the longevity of the restorations and the presence of secondary caries at the restoration- dentine interface were evaluated radiographically, using the criteria proposed by Frencken et al<sup>(20)</sup> (Table 2).

## Results

The data thus collected was subjected to statistical evaluation. The comparison of the carious removal status between the soft and hard carious lesions was assessed by

the chi-square test ( $\chi^2$ ). Table(3) shows the number of the soft and hard carious lesions. Figure (4) shows The comparison of the caries removal status scores between the soft and hard carious lesions that indicated a very high significant statistical result. For the soft carious lesions 83.33% showed the complete removal of soft carious dentine, while the hard carious lesions 68.75% showed a partial removal of the carious dentine. The time taken for caries removal between the soft and hard carious dentine was assessed by the (t-test), P-value was( 0.0017) which indicate a highly significant difference at level ( $P < 0.01$ ), table (4) represents the time taken for the removal of carious dentine, the removal of the soft carious dentine required a shorter period of time ( $4.96 \pm 0.99$ ) minutes when compared to the removal of hard carious dentine ( $6.09 \pm 1.04$ ) minutes. The difference between the radiographic evaluation scores on immediate and six-months follow-up examination were assessed by the chi-square test ( $\chi^2$ ), table (5) shows the number of the carious lesions representing the immediate radiographic evaluation scores. Figure (5) shows that on immediate radiographic evaluation, 75% of the soft carious lesions showed the absence of a gap between the restoration-dentine interface and 25% showed the partial presence of the gap, while for the hard carious lesions 25% showed the presence of the restoration and the absence of a gap between the wall and the base of the cavity and 75% showed the partial presence of a gap at the restoration-dentine interface. Table (6) shows the number of the carious lesions representing the six-months follow-up radiographic evaluation scores of the restorations. Figure (6) shows that after a six month radiographic examination, 54.17% of the soft carious lesions showed the presence of the restoration, 37.50% showed the partial presence of a gap between the restoration-dentine interface and 8.33% showed the absence of the restoration. None of the treated lesions showed the presence of secondary caries. While for the hard carious lesions after six months, 12.50% showed the presence of the restoration, 62.50% showed the partial

presence of the restoration and 25% showed the absence of the restoration. None of the treated lesions showed the presence of secondary caries formation on radiographic evaluation. Figure(7) show some of the radiographic evaluation immediately and after six-months follow-up examination scores of the restorations.

## Discussion

Philosophies of dental treatment change with time and now there is more than ample evidence provided by research for a reappraisal of the traditional approaches to caries treatment<sup>(20)</sup>. The minimal intervention technique of chemo-mechanical caries removal using Carisolv represents one such new approach to restorative dentistry. Results from the initial laboratory based experiments testing effectiveness, have shown this technique to be a more selective method of removal of carious dentine<sup>(5,7)</sup>. However, no study has been attempted to evaluate the efficacy of Carisolv in the removal of carious dentine in the primary teeth. In this study, 83.33% of the soft carious lesions showed complete removal of the soft carious dentine, and 68.75% of the hard carious lesions indicated partial removal of the carious dentine. Although Carisolv did not completely remove the hard carious dentine, there is strong evidence to support the concept that the partly demineralized, minimally infected inner carious dentine can be safely left behind, provided that the bonding of the restorative material to the tooth surface is adequate, this is agreed with Frencken, 1999 and Hossain, et al 2003<sup>(20,21)</sup>. Also, due to the high pH of Carisolv, only the organic phase of dentine is affected this is agreed with Ericson, 1999 and Yoshishige, et al 2007 who improved that hard carious dentine is less susceptible to removal<sup>(19,22)</sup>. The dentinal carious lesion can be distinguished into two zones. An outer layer of infected dentine in which the collagen fibers are partially degraded and cannot be remineralized, and an inner layer of affected dentine which is partially demineralized with intact collagen fibers and can be remineralized<sup>(7)</sup>. A chemo-

mechanical caries removal system acts by causing further degradation of the partially degraded collagen in the infected dentine<sup>(23,24)</sup>. The mechanism of action of Carisolv satisfies this criteria in the chemico-mechanical removal of carious dentine. The active ingredient in Carisolv is sodium hypochlorite, when mixed with amino acids it generates chloramines. This results in the chlorination of the partially degraded collagen and the conversion of hydroxyproline to pyrrole – 2 – carboxylic acid, which initiates the disruption of collagen fibers and a selective softening of the outer layer of carious dentine<sup>(23,24)</sup>. Due to a high pH of 11, only the organic phase of dentine is affected. The high viscosity of Carisolv facilitates accurate placement and decreases the volume of the material needed<sup>(19,22)</sup>. The time taken for the removal of soft carious dentine and hard carious dentine was  $4.96 \pm 0.99$  minutes and  $6.09 \pm 1.04$  minutes respectively, this result is in conformity with the result obtained in a study by Ericson et al<sup>(19)</sup>. Since the technique does not require the use of local anaesthesia, it avoids the induction of pain and anxiety, that is caused due to the trauma during the injection procedure and the fear of the needle. In this study, none of the patients experienced any discomfort on excavation. Thus, it is a virtually painless, non-invasive procedure with an added advantage of patient cooperation during treatment. Additionally, this technique has also proved to be safe in preventing the progress of the carious lesions as noted in our six months follow-up of the restorations, through clinical and radiographic evaluation, this result is in agreement with the result of Frencken, et al<sup>(20)</sup>. Though directly not evaluated in this study, the toxicity of Carisolv has been investigated in experimental animals and was considered to be safe for use in the oral cavity<sup>(25,26,27)</sup>. Hence, the Chemo-mechanical caries removal technique using Carisolv can be considered as an effective atraumatic treatment modality. In an environment, in which “*extraction is the rule rather than an exception*” as in the developing countries, unconventional tooth preserving approaches such as the atraumatic restorative treatment have an

opportunity to evolve. Application of this approach, which does not rely on electricity or expensive dental equipment, makes it possible to provide a cost effective treatment for large populations<sup>(20,28,29)</sup>.

## Conclusion

This study evaluating the efficacy of Carisolv showed that:

1. The soft carious dentine was removed more effectively than the hard carious dentine.
  2. The removal of soft carious dentine required a shorter period of time, when compared to the removal of hard carious dentine.
  3. On radiographic evaluation of the restorations, none of the treated lesions showed the presence of secondary caries.
- Hence, Carisolv a virtually painless, non-invasive technique of caries removal appears to be of potential interest for use, in clinical pediatric dentistry and in combination with the atraumatic restorative treatment of dental caries in large populations.



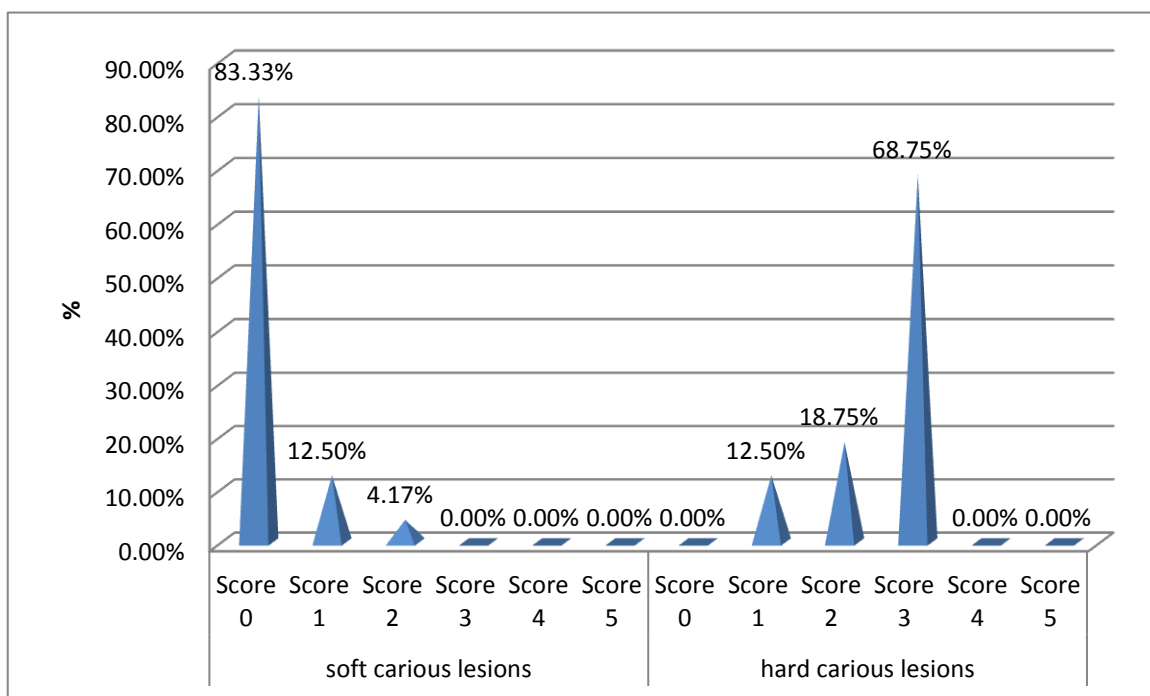
Fig.(1):-Carisolv instrument kit.



Fig. (2):-The Carisolv twin Multimix Syringe Dispenser.



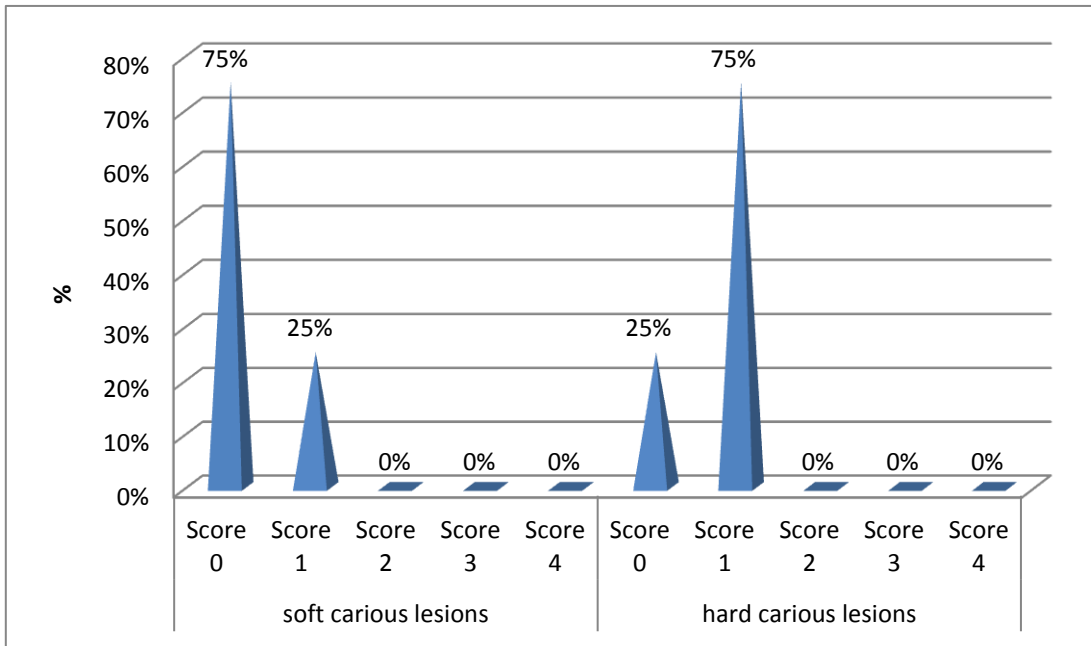
Fig.(3):-The parts of the Carisolv twin Multimix Syringe Dispenser: syringe, static mixer, plunger.



( $\chi^2$ ) between Soft & Hard carious; DF=3; P-value=0.000;

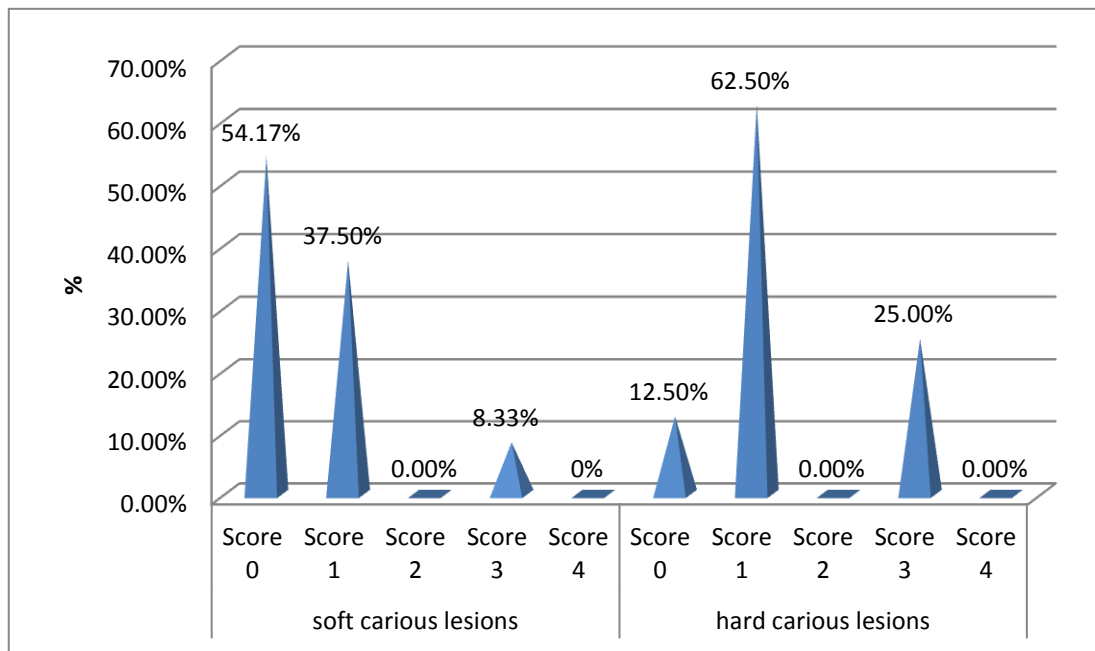
HS=p<0.001; lesions = 31.875

Fig.(4):-The comparison of the caries removal status scores between the soft and hard carious lesions.



( $\chi^2$ ) between Soft & Hard carious; lesions = 9.697; (DF) = 1; P-value = 0.002 ; HS: P < 0.01.

Fig.(5):-The comparison between soft and hard carious lesions on immediate radiographic evaluation scores of the restorations.



( $\chi^2$ ) between Soft & Hard carious ; lesions = 7.485; (DF) = 2; P-value = 0.024; HS: P < 0.05.

Fig.(6):-The comparison between soft and hard carious lesions after six-months follow-up radiographic examination.

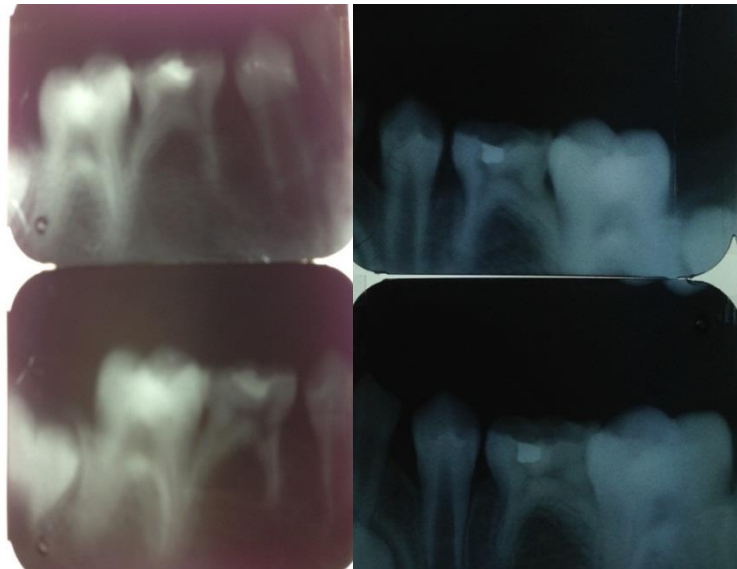


Fig.(7):-Radiographical evaluation immediately and after six-months follow-up examination scores of the restorations.

Table (1):-The definition of the caries removal status scores.

Score	Definition
0	Caries removed completely.
1	Caries present in the base of the cavity.
2	Caries present in the base and/or one wall.
3	Caries present in the base and/ or two walls.
4	Caries present in the base and /or more than two walls.
5	Caries present in the base, walls and margins of the cavity.

Table (2):-The definition of the radiographic evaluation scores of the restorations.

Score	Criteria
0	Restoration present. No gap between the wall and the base.
1	Gap and/or restoration present partly. No signs of caries.
2	Gap and/or restoration present partly. Signs of caries.
3	Restoration not present. No signs of caries.
4	Restoration not present. Signs of caries.

Table (3):-The comparison of the caries removal status scores between the soft and hard carious lesions.

	Soft carious lesions		Hard carious lesions	
	Count	Percentage	Count	Percentage
Score 0	20	83.33 %	0	0.0 %
Score 1	3	12.50 %	2	12.50 %
Score 2	1	4.17 %	3	18.75 %
Score 3	0	0.0 %	11	68.75 %
Score 4	0	0.0 %	0	0.0 %
Score 5	0	0.0 %	0	0.0 %

Table (4):-The time taken for caries removal and the patient comfort on caries excavation (Comparison between the soft and hard carious dentin)(Time taken in minutes)

	Sample size	Mean	±SD	t-test	P-value	Sig.
Soft carious dentin	24	4.96	0.99	3.43	0.0017	HS*
Hard carious dentin	16	6.09	1.04			

\*HS: highly significant at level P < 0.01

Table (5):-Number of the carious lesions representing the immediate radiographic evaluation scores of the restorations.

	Soft carious lesions		Hard carious lesions	
	Count	Percentage	Count	Percentage
Score 0	18	75%	4	25%
Score 1	6	25%	12	75%
Score 2	0	0%	0	0%
Score 3	0	0%	0	0%
Score 4	0	0%	0	0%

Table (6):-Number of the carious lesions representing the six-months follow-up radiographic evaluation scores of the restorations.

	Soft carious lesions		Hard carious lesions	
	Count	Percentage	Count	Percentage
Score 0	13	54.17%	2	12.5%
Score 1	9	37.50%	10	62.5%
Score 2	0	0.0%	0	0.0%
Score 3	2	8.33%	4	25.0%
Score 4	0	0.0%	0	0.0%

## References

- 1-Rahimtoola S, Maher R. Pain related to treatment of caries lesion. J Dent Child 2000; 67: 123-127.
- 2-Elderton RJ. New approaches to cavity design with special reference to class II lesions. Br Dent J. 1984; 157: 421-427.
- 3-Ajilal SK, Jonathan R, Renjith B, Premila S. Morphological changes in the caries excavated dentin prepared by rotary, carisolv and YSGG laser (Biolase) instruments: A scanning Electron microscope evaluation. 2012; 2(1): 1-6.

- 4-A.Banerjee A, Watson TF, Kidd EAM. Dentine caries excavation. A Review of current clinical techniques. *Br Dent J.* 2000; 188: 476-481.
- 5-Vouigionklakis G, Parmosis D. The Caridex® system. *Hell Stomatol Chron.* 1988; 32: 97-102.
- 6- Heinrich-Weltzien R, Kneist S. Deep cavities. In: Albereksson T, Bratthall D, Glantz P, Lindhe J, editors. *Tissue preservation in caries treatment.* London: Quintessence; 2001; 263-274.
- 7-Beeley JA, Yip HK, Stevenson AG. Chemomechanical caries removal. A review of techniques and latest developments. *Br Dent J.* 2000; 188: 427-430.
- 8-Azrak B, Callaway A, Grundheber A, Stender E, Willershausen B. Comparison of the efficacy of chemomechanical caries removal (Carisolv™) with that of conventional excavation in reducing the cariogenic flora. *Int J Pediatr Dent.* 2004; 14 : 182-191.
- 9-Zinc JH, McInnes-Ledoux P, Capdeboscq C, Weinberg R. Chemo-mechanical caries removal a clinical evaluation. *J Oral Rehab.* 2008; 15: 23-33.
- 10-Silva LR. A new system for chemo-mechanical caries removal- case report. *Rev. Paul Odontol.* 2009; 16: 4-8.
- 11-Banerjee A, Watson TF, Kidd EA. Dentine caries excavation: A review of current clinical techniques. *Br Dent J.* 2000;188:476-482.
- 12-Banerjee A, Kidd EA, Watson TF. In vitro evaluation of five alternative methods of carious dentine excavation. *Caries Res* 2000; 34: 144-150.
- 13-Fure S, Lingstrom P. Evaluation of the chemomechanical removal of dentine caries in vivo with a new modified Carisolv gel. *Clin Oral Investig.* 2004;8:139-144.
- 14-Lager A, Thornqvist E, Ericson D. Cultivable bacteria in dentine after excavation using rose-bur or Carisolv. *Caries Res.*2003; 37: 206-211.
- 15-Dammaschke T, Stratmann U, Mokrys K, Kaup M, Ott KHR. Histocytological evaluation of the reaction of rat pulp tissue to Carisolv. *J Dent* 2001; 29: 283-290.
- 16-Bulut G, Zekioglu O, Eronat C, Bulut H. Effect of Carisolv on the human dental pulp: a histological study. *J Dent* 2004; 32: 309-314.
- 17-Dammaschke T, Stratmann U, Mokrys K, Kaup M, Ott KHR. Reaction of sound and demineralised dentine to Carisolv in vivo and in vitro. *J Dent* 2002; 30: 59-65.
- 18-Dammaschke T, Stratmann U, Danesh G, Schafer E. Reaction of rat pulp tissue to carisolv "new gel" a histological evaluation. *Aust Dent J* 2006; 51(1): 57-63.
- 19-Ericson D. Efficacy of a new gel for chemo-mechanical caries removal. *J Dent Res.* 1999; 77: 1252. Abstract 360.
- 20-Frencken J. The A.R.T. – Review and global trends. *Community Dent and Oral Epidemiol.*1999; 27: 421- 453.
- 21-Hossain M, Nakamura Y, Tamaki Y, Yamada Y, Jayawardena JA, Matsumoto K. Dental composition and Knoop hardness measurements of cavity floor following carious dentine removal with carisolv. *Oper Dent* 2003; 28: 346-351.
- 22-Yoshishige Y, Mozmmal H, Yukio N, Koukichi M. Artificial plaque removal with carisolv system :Aclinical approach. *J Clin Pedia Den.* 2007; 31(3): 201-203.
- 23-Goldman M, Kronman JH. A preliminary report on chemomechanical removal of caries. *J A D A* 1976; 93: 1149 –1153.
- 24-Cederlund A, Lindskog S, Lomlof J. Effect of a chemical caries removal system (Carisolv TM) on dentine topography of non-carious dentine. *Acta Odonto Scand.* 2003; 57: 185-189.
- 25-Dammaschke T, Stratman U, Ott K. Histocytological evaluation on reaction of pulp and dentin to Cavisolv®. Paper Presented at AFG – Jahrestatging Mainz, Jan 1999.
- 26-Ericson D, Zimmerman M, Raber H, Gotrick B, Bornstein R, Thorell J. Clinical evaluation of efficacy and safety of a new method for chemico-mechanical removal of caries. A multi-center study. *Caries Res* 2006; 33: 171-177.
- 27-Yazici AR, At\_lla P, \_zg\_naltay G, M\_ft\_oglu S. In vitro comparison of the efficacy of Carisolv and conventional rotary instrument in caries removal. *J Oral Rehabilitation* 2003; 30: 1177-1182.
- 28-Splieth C, Rosin M, Gellissen B. Determination of residual dentin caries after conventional, mechanical and chemo-mechanical caries removal with carisolv. *Clin Oral Invest.* 2011; 5: 250-253.
- 29-Hosoya Y, Kawashita GW, Marshall J, Goto G. Influence of carisolv for resin adhesion to sound human primary dentin and young permanent dentin. *Journal of Dentistry.* 2010; 29(3): 163-171.