

Treatment of Recurrent Aphthous Stomatitis with 940nm Diode Laser

Muhamed I. Hazeem BDS, MSc. ⁽¹⁾

Muthenna Sh. Rajab BDS, MSc. ⁽²⁾

Raed A. Badeia BDS, MSc. ⁽³⁾

Key words

diode laser,
aphthous, ulcer,
RAS

Abstract

Background & objectives: Ulcers in the mouth (recurrent aphthous stomatitis) are very common and may vary in size from very small to very large. The exact cause of mouth ulcers isn't known but acidic foods and stress are thought to be factors, as well as local traumatic damage such as that caused by vigorous toothbrushing. Although uncomfortable, small ulcers are tolerable, but large ulcers can last for up to 2 weeks and greatly affect the ability to eat, drink and even talk. This study aimed to evaluate the efficacy of treatment of recurrent aphthous stomatitis by application of 940 nm diode laser irradiation & its effect on the duration and pain sensation. **Materials and methods:** A total number of 32 patients having at least 2 ulcers for each. Those patients were enrolled in this study using a split mouth design. The study included two groups, The experimental (study group) consisted of thirty two ulcers (in the 32 patients) were subjected to 940 nm laser irradiation & control group comprised of thirty two ulcers (in the same 32 patients) left without laser irradiation. Pain scores were recorded before and after laser treatment. The patient subjected to follow-up visits until complete healing of the ulcers occurred. **Results:** There were immediate changes in the pain scores of the experimental group just after diode laser application. The duration of the control group lesions ranged between (7-14) days, while the lesion in the experimental group subsided with a range between (4-12) days. **Conclusion:** 1. Single session of diode laser irradiation can be used to produce immediate, dramatic and sustained analgesic effect on RAS lesion. 2. The lesion duration was significantly reduced to about 40% from that of control lesion.

Introduction

Aphthous ulcer or recurrent aphthous stomatitis (RAS), commonly referred to as canker sores, are inflammatory lesions of the mucous lining of the mouth which may involve the gingivae, mucogingival area,

cheeks, gums, tongue, lips, and roof or floor of the mouth ⁽¹⁾. They are characterized by painful, recurrent, small, round or ovoid ulcers with circumscribed margins, erythematous haloes, and yellow or gray floors, typically first presenting in childhood or adolescence ⁽²⁾. The epithelial lesion causes exposed nerve endings, resulting in pain or soreness especially when eating spicy food or citrus fruits ⁽³⁾.

(1)Lecturer, Department of Periodontology, College of Dentistry, Tikrit University.

(2)Ass. Prof., Conservative Dentistry, College of Dentistry, Tikrit University.

(3)Ass. Prof., Department of Periodontology, College of Dentistry . Al-Mustansiriyah University.

The manifestations of the disease can range from mild to severe and, in extreme cases, even hinder a person's ability to ingest foods, thereby making the person susceptible to malnutrition⁽¹⁾. There are three clinical presentations of RAS: minor aphthous, major aphthous and herpetiform ulcer. Minor aphthous (Mikulicz ulcer) are the most prevalent form (80-95% of all RAS lesions). They are white ulcerative lesions that may be round or oval and single or multiple⁽⁴⁾. Two to eight lesions occur per year, heal without scars after seven to fourteen days⁽⁵⁾. Major aphthous (Sutton's ulcer), accounts (10-15% of RAS) cases and is characterized by large lesions with 1-2 lesions occurring at the same time. These lesions may last for six weeks or more with severe pain commonly in immune-deficient patients⁽¹⁾. Herpetiform ulcers are the least common form (5-10%). Unlike minor and major aphthous, herpetiform ulcers appear on both keratinized and non-keratinized mucosa⁽⁴⁾. Minor aphthous ulcer is amongst the most common form of oral ulcerative disease and affects (15-20%) of the population worldwide. It has been documented as being as high as (50-66%) in some populations⁽⁶⁾. The exact cause of many aphthous ulcers is unknown, but it is likely an auto-immune mediated condition⁽²⁾. There is considerable evidence that aphthous ulcers are related to a focal immune dysfunction in which T lymphocytes have a significant role⁽⁷⁾. Etiology of these lesions is not thought to be viral or bacterial in origin but some predisposing factors may be identified for RAS such as: Trauma, stress, deficiency of iron, folic acid or vitamin B12, cessation of smoking, food allergy and gastrointestinal disorders⁽⁸⁾. Aphthae can also occur as widespread lesions in association with systemic diseases including Bacet's syndrome, and malabsorption disorders like Crohn's and Celiac diseases^(1,4). Similar epithelial damage resulting from trauma, an immunological attack as in lichen planus, pemphigoid or pemphigus; damage because of an immune defect as in HIV disease and leukemia; infections like tuberculosis, herpes viruses and syphilis; cancers and nutritional defects⁽¹⁻³⁾. The

ulcers begin with a tingling or burning sensation at the site that progresses after a few days to a yellow or white oval surrounded by an inflamed red border. The ulcer is severely painful to palpation, especially during intake of spicy or acidic foods, and can become secondarily infected at times. Use of a toothpaste containing Sodium Lauryl Sulfate (SLS) can trigger attacks in some patients. Typically, dentists have looked at using topical agents like Debacterol (chemical cauterizing agent), or topical steroid agents (Kenalog in Orabase). There is no curative treatment for RAS. The best that can be achieved is to avoid local traumatic precipitation, lessen the pain and duration of ulceration by suppressing the local immune response, and prevent secondary infections⁽⁸⁾. The use of lasers have several potential applications in periodontology and other fields of dentistry, these applications include laser gingivectomy, gingivoplasty, distal wedge procedure, curettage, sterilization of root surfaces and periodontal pockets, as well as laser scaling, frenectomy, crown lengthening, biopsies, tongue lesions, white lesions, aphthous ulcers, laser root planing, and tuberosity reduction⁽⁹⁾. Diode lasers are semiconductors that use solid state elements to change electrical energy to optical energy. Diode laser wavelength ($\lambda=810-980\text{nm}$) approximate the absorption coefficient of soft tissue pigmentation (melanin, hemoglobin and oxyhemoglobin). Therefore, the light energy from the diode is highly absorbed by the soft tissues and poorly absorbed by teeth and bone^(10,11). A 940 nm laser can be used to coagulate, cut or ablate soft tissue, in a contact mode for enhanced surgical precision and tactile feedback, or in a non-contact mode. Pulsed mode have been developed which allow a range of soft tissue procedures to be completed without local anaesthesia. This is possible by using very short pulse durations (≤ 100 microseconds) which are shorter than both the thermal relaxation time of soft tissue and the receptor range of nociceptor pain responses⁽¹²⁾. High power diode laser can be used as low power laser when it is defocused. The advantages of this adaptation are to enable both high and low

power functions with same laser device. Defocused diode laser is based on physical parameters that produce only biomodulatory effects on the tissue without thermal damage or ablation. It has been applied to induce analgesia and acceleration of wound repair⁽¹³⁾. The aim of the present study is to evaluate the efficacy of diode laser irradiation in reduction of duration and pain sensation of the recurrent aphthous stomatitis.

Materials and Methods

Subjects

A total number of 32 patients having at least 2 ulcers (1 study & 1 control) for each patient. A split mouth design was used in this study which included two groups, The study group consisted of thirty two ulcers were selected from patients who attended the teaching hospital of the college of dentistry in Tikrit university seeking treatment of painful ulcers from (January to April 2013). The second group of the study was a control group comprised of thirty two ulcers from the same patients. Pain scores were recorded before and after laser treatment. The patient subjected to follow-up visits until complete healing of the ulcers. The study group of ulcers was subjected to 940nm laser irradiation & the control group ulcers left without diode laser irradiation. Pain scores were recorded before and after laser treatment. The patient subjected to follow-up visits until complete healing of the ulcers. Patients with systemic disorders and /or less than 16 years old, smokers, and the patients who used local chemical medication were excluded from the study. All of the patients were informed about the nature of the study and asked to commit to the follow up visits and consents were taken from them.

Method

The lesions from the experimental group were irradiated with diode laser (Ezlase, Biolase, USA) fig(1). The laser parameters used in this study were listed in table (1). Within the first visit, pain score were estimated according to the patient perception in a scale (1-10)for all patients

(experimental and control groups). After the lesions irradiation the pain scores were recorded again for the experimental group. All patients were examined every 24 hours until complete subside of the ulcers occurred. The duration of each ulcer (experimental and control) was recorded taking in consideration the periods after and before the first visit.

Statistical Analysis

Collected data including duration of the ulcers and pain scores were tabulated in excel tables (Microsoft office 2010). Means, standard deviations, ANOVA test and p values were calculated using IBM SBSS 19.0.0 statistical package for windows.

Results

Table (2) has shown the mean values, standard deviations and the significance of the differences in the pain scores of the patients just before and after irradiation of the lesion. There were immediate changes in the pain scores of the experimental group just after diode laser application. The patient felt pain relief and decreased pain scores in a range (4-8) and the mean reduction in the pain scores is as high as 6 in a scale of (1-10). The mean values and standard deviations of the lesions duration (in days) were listed in table (3). The duration of the control group lesions ranged between 7-14 days, and the mean was 10.28 days, while the lesion in the experimental group subsided with a range between 4-12 days with 6.66 days in mean. There was a highly significant reduction in the lesions duration in the irradiated ulcers. Figures (2) represents lesion at the treatment session(A), and complete healing of the same lesion without scar after 72 hours (B).

Discussion

The result of this study showed that a single session of diode laser irradiation can be used to produce immediate, dramatic and sustained analgesic effect on RAS lesion. In addition, the lesion duration were significantly reduced to

about 40% from that of control lesion. Early studies in this field depended on the thermal and ablation effects of the laser on RAS lesions. Colvard and Kuo got 88% pain free result by using carbon dioxide laser in ablative manner to treat aphthous ulcers. However, laser with these parameters could not be used without local anesthesia⁽¹⁴⁾. Zand et al found more promising results by using low intensity, non-thermal and subablative dose of carbon dioxide laser⁽¹⁵⁾. The pain of RAS lesions derives from inflammatory sensitization of small diameter nerve endings that form a plexus at the junction of the epithelial and subepithelial layers. Branches of the plexus extend upward, into the epithelial layer; thus, RAS produces a superficial, focal, inflammatory lesion that is directly associated with exposed sensory nerve endings⁽¹⁶⁾. So in an aphthous ulcer, carbon dioxide laser irradiation can reach the exposed nerve endings easily⁽¹⁵⁾. Low level laser therapy (LLLT) involves the use of specific laser wavelengths ranged from visible red to near infrared with the tissue in order to stimulate and improve healing, as well as reduce pain.⁽¹⁷⁾ Laboratory studies suggest that irradiation with LLLT stimulates collagen production, alter DNA synthesis, and improves the function of damaged neurological tissue. Different mechanisms have been suggested for the main therapeutic effects with LLLT, some of these theories are as follow; the mitochondria produces more ATP and cellular oxygen consumption is decreased, the serotonin and endorphin are increased, prostaglandin synthesis is decreased, expression of cytokines and growth factors is inducted and inflammation will be decreased then wound healing occurs.⁽¹⁸⁾ De Souza TO et al reported that LLLT can cause reduction in pain and a total regression of the lesion after 4 days⁽¹⁹⁾. Khademi H et al reported that low level laser can decrease the healing time, pain intensity and also decrease the time of pain relief in patients with aphthae⁽²⁰⁻²³⁾. In the current study, all the patients from the experimental group claimed reduction of the pain after single session of diode laser. That is much more than the previous studies. The lesion also showed quicker

healing. These findings may be due to the use of the third generation diode laser technology. In this study diode laser source emitted radiation with 940nm wavelength which absorbed strongly in haemoglobin and water. This wavelength corresponds to the peak absorption for oxygenated (arterial) blood in this region of the spectrum and also higher absorption into deoxygenated (venous) blood than 810 or 980 nm diode lasers, giving this laser type more efficiency⁽¹²⁾. The wavelength of this laser rendered it very effective biostimulation device at the same time the output parameters rendered it very efficient thermal laser. In other words, diode laser with 940nm wavelength combine the effect of thermal subablative lasers with the wanted effect of LLLT.

Conclusions

1-Single session of diode laser irradiation can be used to produce immediate, dramatic and sustained analgesic effect on RAS lesion.

2-The lesion duration were significantly reduced to about 40% from that of control lesion.



Fig. (1):- Laser device used in this study.

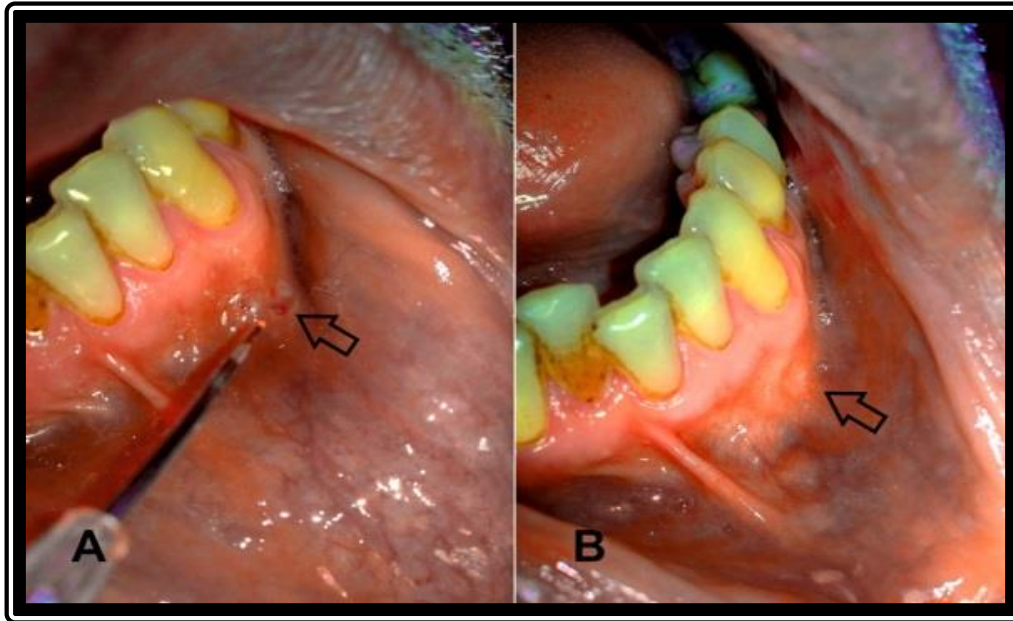


Fig. (2):- Aphthous ulcer at the treatment session(A), and after 72 hours later (B).

Table (1):- Laser parameters used to irradiate the experimental lesions.

| Laser device | Wavelength | Pulse duration | Exposure time | Total energy | Mode |
|----------------|------------|----------------|---------------|--------------|-------------|
| Diode (Ezlase) | 940 nm | 1.00 μ s | 30-40 s | 150-200 J | Non-contact |

Table (2):- Statistical analysis between experimental and control groups according to pain score difference in the first visit.

| groups | pain score difference | |
|--------------|-----------------------|-------------|
| | mean | SD |
| experimental | 5.96875 | 1.141088661 |
| control | 0 | 0 |
| P-value | 1.72E-37 | |
| Significance | HS | |

Table (3):- Statistical analysis between experimental and control groups according to lesion duration in days.

| groups | duration (days) | |
|--------------|-----------------|----------|
| | mean | SD |
| experimental | 6.65625 | 1.962291 |
| control | 10.28125 | 2.08018 |
| P-value | 1.71E-09 | |
| Significance | HS | |

References

- 1-Cafaro A, Albanese g, Arduino PG, Mario C, Massolini G, Mozzati M, Broccoletti R. Effect of low-level laser irradiation on unresponsive oral lichen planus: early preliminary results in 13 patients. *Photomed Laser Surg*. 2010 Oct;28(2):99-103.
- 2-Jurge S, Kuffer R, Scully C, Porter SR. Recurrent aphthous stomatitis. *Oral Dis* 2006;12:1-21.
- 3-Scully C, Felix DH. Oral medicine-update for the dental practitioner. Aphthous and other common ulcers. *British Dent Journal*. 2005;199(5):259-264.
- 4-Tilliss TSI, McDowell JD. Differential diagnosis: is it herpes or aphthous? *J Contemp Dent Pract* 2002;(3)1:001-015.
- 5-Jurge S, Kuffer R, Scully C, Porter SR (2006). "Mucosal disease series. Number VI. Recurrent aphthous stomatitis". *Oral Dis* 12 (1): 1–21.
- 6-http://en.wikipedia.org/wiki/Aphthous_ulcer (retrieved Nov. 20th, 2011).
- 7-Wray D, Ferguson M, Hutcheon W, Dagg J (1978). "Nutritional deficiencies in recurrent aphthae". *J Oral Pathol* 7 (6): 418–23.
- 8-Donnarumma G, De Gregorio V, Fusco A, Farina E, Baroni A, Esposito V, Contaldo M, Petruzzi M, Pannone G, Serpico R. Inhibition of HSV-1 replication of laser diode irradiation: possible mechanism of action. *Int J Immunopathol Pharmacol*. 2010;23(4):1167-76.
- 9-Cauwels RG, Martens LC. Low level laser therapy in oral mucositis: a pilot study. *Eur Arch Paediatr Dent*. 2011;12(2):118-23.
- 10- Jablonski's Dictionary of dentistry, 1992. P 742.
- 11-Scully C and Porter SR. Recurrent aphthous stomatitis: current concepts of etiology, pathogenesis and management. *J Oral Pathol Med* 1989;18(1):21-27.
- 12-Shashy RG, Ridley MB. Aphthous ulcers: a difficult clinical entity. *Am J Otolaryngol* 2000;21:389-393.
- 13-Scully C and Porter SR. Oral mucosal disease: recurrent aphthous stomatitis. *British Dent Journal*. 2008;46(3):198-206.
- 14-Colvard M, Kuo P. Managing aphthous ulcers laser treatment applied. *J Am Dent Assoc* 1991;122:51-53.
- 15-Zand N, Fashtami LA, Djavid GE, Fateh M, Alinaghizadeh MR, Fatemi SM, Kalati FA. Relieving pain in minor aphthous stomatitis by a single session of non-thermal carbon dioxide laser irradiation. *Lasers Med Sci* 2009;24(4):515-520.
- 16- Lomke MA. Clinical applications of dental lasers. *General dentistry* 2009;1:47-59.
Walsh, Laurence J. Maximising gingival aesthetics using lasers. *Australasian Dental Practice* 2010;4:48-52.
- 17- Vasques MT, Alves MAV, Benetti C, Aranha ACC, Zezell DM, Corrêa L. Temperature measurement and Hsp47 immunexpression in oral ulcers irradiated with defocused high-energy diode laser. *Journal of Photochemistry and Photobiology* 2013;118:42-48.
- 18- Mohammed M. Jawad, Sarah T. AbdulQader, B.B. Zaidan, A.A. Zaidan, Ibraheem T. AbdulQader, A.W. Naji. An Overview: Laser Applications in Dentistry. *International Journal of Pharmacology* 2011;7:189-197.
- 19-De Souza TO, Martins MA, Bussadori SK, FERNANDES kp, Tanji EY, Mesquita-Ferrari RA. Clinical evaluation of low-level laser treatment for recurring aphthous stomatitis. *Photomed Laser Surg* 2010;28(2):S85-88.
- 20- Khademi H, Shirani A, Nikegbal F. Evaluation of low level laser therapy in recurrent aphthous stomatitis. *Shiraz Univ Dent J* 2009;10(2):160-162.
- 21- Parker S. Low-level laser use in dentistry. *BDJ* 2007;202(3):131-138.
Basirat M. The effect of low power lasers in healing of oral ulcers. *JLasers Med Sci* 2012;3(2):79-83.
- 22-Kravitz ND, Kusnoto R. Soft tissue lasers in orthodontics: An overview. *Am J OrthodDentofacialOrthop*. 2008;133:S110-S114.
- 23-Saxen MA, Ambrosius WT, Rehemtula AKF, Russell AL, Eckert GJ. Sustained relief of oral aphthous ulcer pain from topical diclofenac in hyaluronan: a randomized, double-blind clinical trial. *Oral Surg Oral Med Oral Pathol Oral Radiol Endo* 1997;84:356-361.