

Comparison of Three Dimensional Dental Software Computed Tomography Findings with Real Time Surgical Approaches for Impacted Teeth

Nazhat M. Abdlkareem BDS, MSc. ⁽¹⁾

Shefaa H. AL-Nuome BDS, MSc., MAX.R and DOS ⁽²⁾

Haider A. Rassul BDS, MSc. ⁽³⁾

Taha Y.Hamad BDS, MSc. ⁽⁴⁾

Key words

the dental soft
ware computed
tomography,
impacted teeth.

Abstract

An exact localization of impacted teeth is often difficult to assume by using two dimensional conventional radiological techniques like OPG or dental films. In contrast to these two dimensional imaging method, the Dental slice Software Computed Tomography offers a three-dimensional imaging of maxilla-facial region, providing the opportunity to study objectives in all standard plans with three-dimension, reconstructed and multisection views. The aim of this study is to prove the effectiveness of the Dental slice Software Computed Tomography in evaluating the position of impacted teeth as a presurgical diagnostic aid. 25 patients with total of 40 impacted teeth were classified and evaluated by three sets .The first set of radiographs consist of traditional two dimensional images(per apical , occlusal films and OPG).The second set comprised three-dimensional views obtained from a Dental slice Soft ware Computed Tomography and a third set which was surgical interventions results. Teeth crowns were classified into: type I (buccal or labial), type II (palatal or lingual), type III (half distance of the labio-palatal or bucco-palatal ,labio-lingual or bucco-lingual) according to their position within dental arches. The dental soft ware Computed Tomography succeeded to identify the exact situations of whole 40(100%) impacted teeth crowns that were confirmed surgically in the same anatomical locations. On the other hand there was a Failure of 33(82.5%) crowns that could not be determine their positions by two dimensional images and proved surgically in opposite sides. Three dimensional Computed Tomography is a helpful and stimulating tools by providing the surgeons a perfect multislices: axial, coronal, sagital, two dimensional and three dimensional images in one visit and once exposure and permits the oral surgeons to visualize the position and surgical anatomy of the tooth as it will be in the operating theatre, thus establishing sufficient patterns for adequate surgical planning ,reduce of need for exploratory procedures with less morbidity to the osseous structure and time saving.

(1)Ass. Lecturer, Department of Oral and Maxillofacial surgery, College of Dentistry, Al-Mustansiria University.

(2) Department of Maxillofacial and surgery, Al-Kurkh Hospital, Ministry of health.

(3)Ass. Lecturer, Department of Oral and Maxillofacial surgery, College of Dentistry, Al-Mustansiria University.

(4)Ass. Lecturer, Department of Oral and Maxillofacial surgery, College of Dentistry, Al-Mustansiria University.

Introduction

Impaction of tooth is a situation in which an unerupted tooth is wedged against another tooth (or teeth) otherwise located so that it

cannot erupt normally⁽¹⁾. Clinicians should be able to evaluate the prognosis of the treatment before treatment is started⁽²⁾. An exact localization of impacted teeth is often difficult to assume by using conventional radiological techniques like OPG or dental films⁽³⁾. A series of plain film radiographs obtained at divers angle will show the impacted tooth variously superimposed on the roots of adjacent tooth⁽⁴⁾. It is absolutely necessary to precisely determine the location of enclosed teeth ,to better plan the procedure .Even though the conventional radiological techniques, such as the per apical, occlusal ,and panoramic, are commonly used to detect the presence of such teeth ,they can present deficiencies and limitation such as distorted and superposed images^(5,6). Where dental extraction presents a high degree of difficulty, we cannot bypass additional examination⁽⁵⁾. During the past years various studies have been published to validate Dental Computed Tomography (DCT) as an excellent tool for diagnosing dental related pathologies⁽⁷⁻¹¹⁾. Dental CT has become an established method for anatomic imaging of jaws. More recently, this Dental CT imaging technique has gained importance in diagnosing dental-associated diseases of the mandible and maxilla⁽¹²⁾. Today with a properly prescribed three-dimensional(3D) scan ,practitioners have gained the ability to collect much more data with single scan⁽¹³⁾. The Digital Volume Tomography (DVT) offers a three-dimensional imaging of maxilla facial region ,providing the opportunity to study objectives in all standard plans with three-dimension reconstruction multisection views⁽³⁾. It combined with traditional panoramic and cephalometric radiographs^(14,15). This Software CT (SCT) consists of several programs that allow different individualized tracings to be made and measured on the radiographs, applying them to diagnosis in different odontogenic disciplines .such as orthodontics, implantology ,and oral surgery⁽¹⁶⁾. Choosing the most suitable surgical exposure procedure on the basis of an accurate positional diagnosis can minimize surgical trauma and improve the periodontal prognosis of the outcome^(17,18). Specific software CT that allows the three-dimensional manipulation and reconstruction of the image represent an excellent alternative to plan such procedures⁽⁶⁾.

The aim of this study is to compare between 3DCT and conventional x-ray like perapical, occlusal or OPG and to observe the effectiveness of 3DCT in evaluating the position of impacted teeth as presurgical diagnostic aid.

Material and Method

The study was carried out on 25 patients, 12 males and 13 females aged between 10-55 years old, who attended the Dental Clinic in Oral and Maxillofacial Surgery Department in AL-Mustansiriyah University-College of Dentistry. Most of these patients were referred by their orthodontists at the same college for surgical removal of impacted and ectopic teeth on a typical position .The patients had already 2-Dimensional(2D) radiographs (panoramic, occlusal and perapical film) and the position of 40 impacted teeth crowns of incisors, canines, premolars and molars were classified as:

1-Type I: crown located in the buccal or labial side.

2-Type II: crown located in the palatal or lingual side.

3-Type III: crown located in the half distance of the labio-palatal or bucco--palatal,labio-lingual or bucco-lingual area.

Clinically the location of all impacted and ectopic teeth were examined on dental chair intraoral by inspection the abnormal orientation of adjacent teeth and palpation of the labial , palatal, buccal, and lingual sides of the ridge in the immediate area of the teeth in both jaws before referring to the Dental Computed Tomography Department .

Dental CT Investigation

All 3- Volumetric dentition images obtained from soft ware CT scan procedures for our patients were done by an experienced maxillofacial radiologist in the CT department of AL-Kurk hospital who unaware of patients physical findings . 25 patients instructed not to move or swallow during scan .The investigation performed in supine position with the cervical spine slightly over extended backward .The head strapped to the head rest and positioned as symmetrically as possible, immobilizing the jaw by having the patient bite on a cotton roll . Human bone segments of toothed jaw with 16 upper impacted and 24 lower impacted teeth were scanned by

(philips -Brilliance 64) 3- Dimensional Dental(3D) soft ware multislice CT. Image data obtained for complete dental / maxillofacial volume with scan time vary from about 2.3-3.5 second for regional scan, thickness of slice: 0.67-1 mm, KVp: 120, mAs : 25-390 per slice. A large field of dental soft ware CT images be viewed in the full 360 degree range and in any desired plane -around the immediate area of interest in order to classify and evaluate the exact position of crowns and their relationships with adjacent teeth and important anatomic structure to decide which of them must be extracted and plan the surgical access and which of them must be exposed crown for orthodontic management. All surgical procedures to remove 29 teeth was performed by an experienced maxillofacial surgeon through 2-sided ,3-sided ,palatal and enveloped flap according to the position of crown and 11 crowns exposed by the same surgeon to fix the brackets for orthodontic treatment figure (1). The patients were prescribed antibiotic, analgesic and mouth wash for 7 days of the postoperative period and given all the other postoperative recommendations. Data were subjected to analyze and assess our results. Descriptive statistics which includes: tables, pie and bar chart, mean, standard deviation and comparism percentages were calculated for the study variables.

Results

The total sample consist of 25 patients who had completely 40 impacted teeth .The proportion of females 13(52%) was higher than males 12(48%) as in figure (2), their ages ranged from 10 to 55 years with mean of 25.24 years and standard deviation 13.25 as in figure (3). According to the clinical examination the study sample was classified into two teeth groups in relation to the dental arch .Mandibular impacted teeth had showed higher percentage 24 (60%) than maxillary 16(40%). Lower molar impacted teeth were more involved 19(47.5%) than other teeth groups in both dental arches followed by impacted upper canine 7(17.5%) ;then upper premolar 6(15%);then lower premolar 3(7.5%); then lower canine and upper molar 2(5%) for each; and finally upper incisor 1(2.5%) as in table(1). Table (2) illustrates the positions of 11crowns of impacted teeth were identified

and evaluated by traditional two-Dimensional(2D) radiography and then compared with the results of surgical exposing crowns that depending on the 3D CT images for orthodontic treatment .It had been found that in 2D radiographs the maxillary impacted canine had the largest misdiagnosed positioned crowns. 3 out of 4 crowns which was considered as type I, and 1 out of 2 crowns as type II , but by 3DCT images reviewed to be 3 crowns as type II, and the anthers as type I. They were proved surgically to be 3 crowns located palataly and the others labially, as they noticed in 3DCT views. The 2D images failed to determine the position of 8(72.72%)crowns which were confirmed to be on opposite sides whereas it could diagnose the position of only 3(27.27%).crowns including the impacted lower premolar crown as type I. The location of 29 impacted teeth crowns were observed by 2D radiographs and 3DCT scans and correlated with the surgical procedures results. 19 crowns of lower molar were detected by 2D images ,9 crowns were classified under type I , 4 crowns as type II , and 6 crowns as type III ,but by 3DCT images reviewed to be 8 out 9 crowns as type II the another one as type I, 2 out of 4 crowns as type II, finally 4 out of 6 crowns as type II, later all these were proved surgically to be in the same locations as they observed in 3DCT views. Maxillary impacted canine 2D radiographically was noticed to be in labio-horizontal direction as type I while was identified and proved to be palato- horizontal(type II) by 3DCT and surgical finding respectively. As a result of these data the conventional 2D radiographies were misdiagnosed of 25 (85.3%) crowns positions which were confirmed to be on the other sides surgically, whereas only 4(13.7%)crowns could be diagnosed by traditional 2D films and proved surgically at the same positions. Meanwhile the determining the localization of 29 (100%) crowns by soft ware 3D CT scans achieved to be in the same anatomical situation which was confirmed surgically to be in the exact sides, for more details see table (3). Comparison between 2D Traditional radiographies and 3DCT multislice views and surgical results of 40 positions of teeth crowns are summarized in table (4).In this study the conventional films enabled to diagnoses the positions only of 7(17.5%) crowns ,otherwise the dental soft ware CT succeeded to identify the exact situations of whole 40(100%) crowns

that were proved surgically in the same anatomical locations. Failure of 33(82.5%) crowns to determine their positions by 2-D images which confirmed surgically in opposite sides.

Discussion

The true and etiology of ectopic impacted of mandibular third molar remain unknown. Several theories have been suggested to explain the ectopic eruption, including aberrant eruption, lesion, trauma, in adequate space or ectopic formation of germs of the teeth. This agreed with Wang CC, et al⁽¹⁹⁾. Who thought that an aberrant eruption pattern occurred when the tooth has displaced by lesion, usually an odontogenic cyst. Impaction of lower third molar was a common findings in this study and had the greatest percentage followed by impacted maxillary canine among the whole sample of our study. This agreed with^(20,21,22) who found that canine is the second most frequently impacted tooth after the lower third molar and has an incidence of proportionally 1:3 percent. Several teeth had an upward, downward, inward or out ward inclinations or even inverted crowns positions. In our study impacted lower third molar were most frequently localized lingually 14(type II) rather than buccally 3(type I) and bucco-lingually 2 (type III) in ratio nearly (5:1) and (7:1) respectively. The surgical removal of such teeth may difficult without determine the exact situation of teeth and their relationship with the surrounding structure, especially impacted lower teeth which related with inferior alveolar nerve (IAN), mandibular canal and roots. The 3D reconstructions allows us to subtract the tooth from the bone structure which rounded it. Thus it can be determined the form of crown and roots and its orientation by 3DCT, see figure (4). The precise location of the impacted teeth in both jaws, enabling the surgeon to view pertinent anatomy, while planning type of surgical guides procedures such as: IAN, mandible canal, foramens, nasal cavity, maxillary antrum, apex roots, roots shapes and all dimensions of mandible and maxilla, see figure (5). This comes in agreement with many studies^(4,14) who said that low sensitivity shows in the panoramic findings creates a clinical dilemma for the patients who represented a high risk of injury to IAN, mandibular canal which deviated,

narrowing of dental roots. For these patients the recommendation is to proceed with CT with all 3-Dimensionals of structures. The risk of injury to IAN is dramatically increased when there is contact between the IAN and dental roots. Our results showed that impacted upper canine were more situated in palatal sides (type II) than in labial (type I) in ratio 2:1, see figure (6). This agreed with results of^(20, 21,23) who found that more maxillary canine in palatal impactions are twice or more as likely as buccal impaction in population. Our explanation for that was the developmental process of canine is relatively is long in both in temporal duration and in its path of eruption this agreed with Dewel⁽²⁴⁾ who suggested that the canine is therefore more at risk for abnormal eruption patterns while other including Peck^(25, 26) have looked for genetic basis for impaction found in conjunction with palatally displaced canine and tendency for impacted to be found in multiple members of the family. A pair of perapical radiographs is in adequate because 2D images give the initial position of impacted tooth and show only the length and breadth of the anatomy with distortion and should put in our considerations the superimposition of surrounding structure, The 3D images adds depth, thus giving the surgeons multiplanner views of volume, this further improve diagnostic abilities and reduced the multiexposed patient to the X-rays, see figure (7). This is confirmed by many studies: the bucco-lingual dimension cant reproduced properly in 2D radiographs without considerable the superimposition of adjacent structure^(27,28). The 3D CT images that facilitate the transition of orthodontic imaging from initial diagnosis to image guidance through the treatment phase^(29,30). Comprising large sample of patients with impacted canine, whose treatment plan involved using 2D traditional radiographs found that treatment for 43.7% of patients had to be revised after cone beam CT was used⁽³¹⁾, and disagreed with some authorities Isaacson KG, et al⁽⁴⁾ who consider plain film to be adequate in many cases of impacted canine. For all our patients cases, the Dental slice software 3D allowed for an excellent surgical planning access because of an accurate image and the proportion of 3D success achieved 100%. There is a general agreement that 3DCT allows to obtain a more accurate reconstruction of the real anatomy than traditional 2D films.

This in agreed with Eric H, et al ⁽³²⁾ who mentioned that clinicians confidence of accuracy of diagnosis and treatment plan was statically higher for 3Dimensional CT images, and also agreed with Eric H, et al ⁽³³⁾ who represented that the ability of 3D dental planning CT to supply the surgeon with a high resolution image of anatomical limitations, bone density and true length and width .There were no major surgical complications.

Conclusion

Dental Slice Three-Dimensional Software Computed Tomography is a contribution on to

dentistry armamentarium of diagnostic aids in relation to impacted teeth for which accurate positional diagnosis is need if treatment is to be successful. The 3D stimulating tools that can help to bridge the gap between images types by providing the surgeons a perfect multislices: axial,coronal,sagital,2D and 3D images in one visit with once radial exposed and permits the oral surgeons to visualize the position and surgical anatomy of the tooth as it will be in the operating theatre, thus establishing sufficient patterns for adequate surgical planning, reduce the need for exploratory procedures with less morbidity to the Osseo structure and time saving.

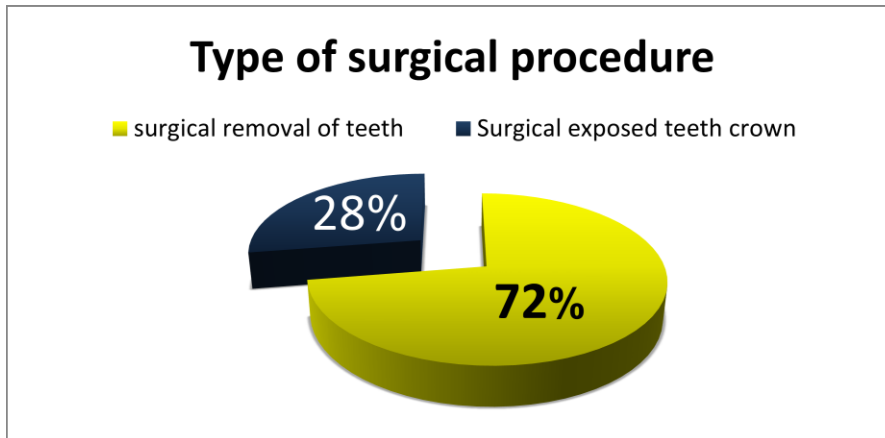


Fig.(1):- The pie chart shows the distribution of the impacted teeth according to the type of surgical procedure done.

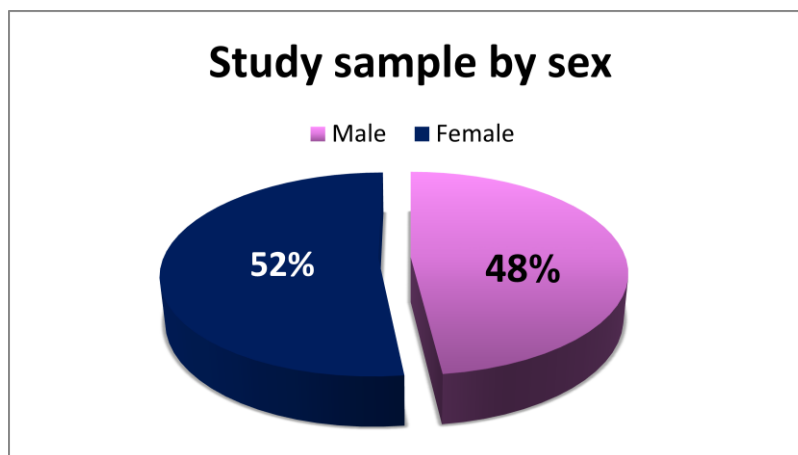


Fig.(2):- The pie chart shows the distribution of study sample by sex.

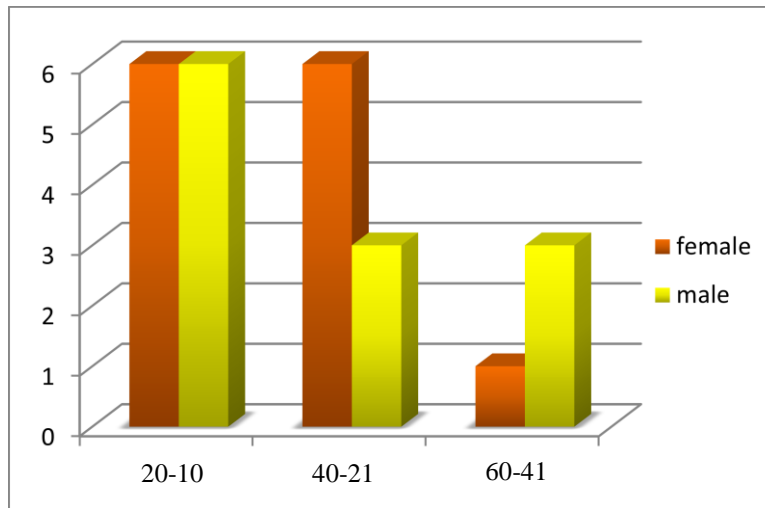


Fig.(3):- Bar chart shows age and gender distribution by mean and standard deviation.
Mean = 25.24 SD- 13.25.

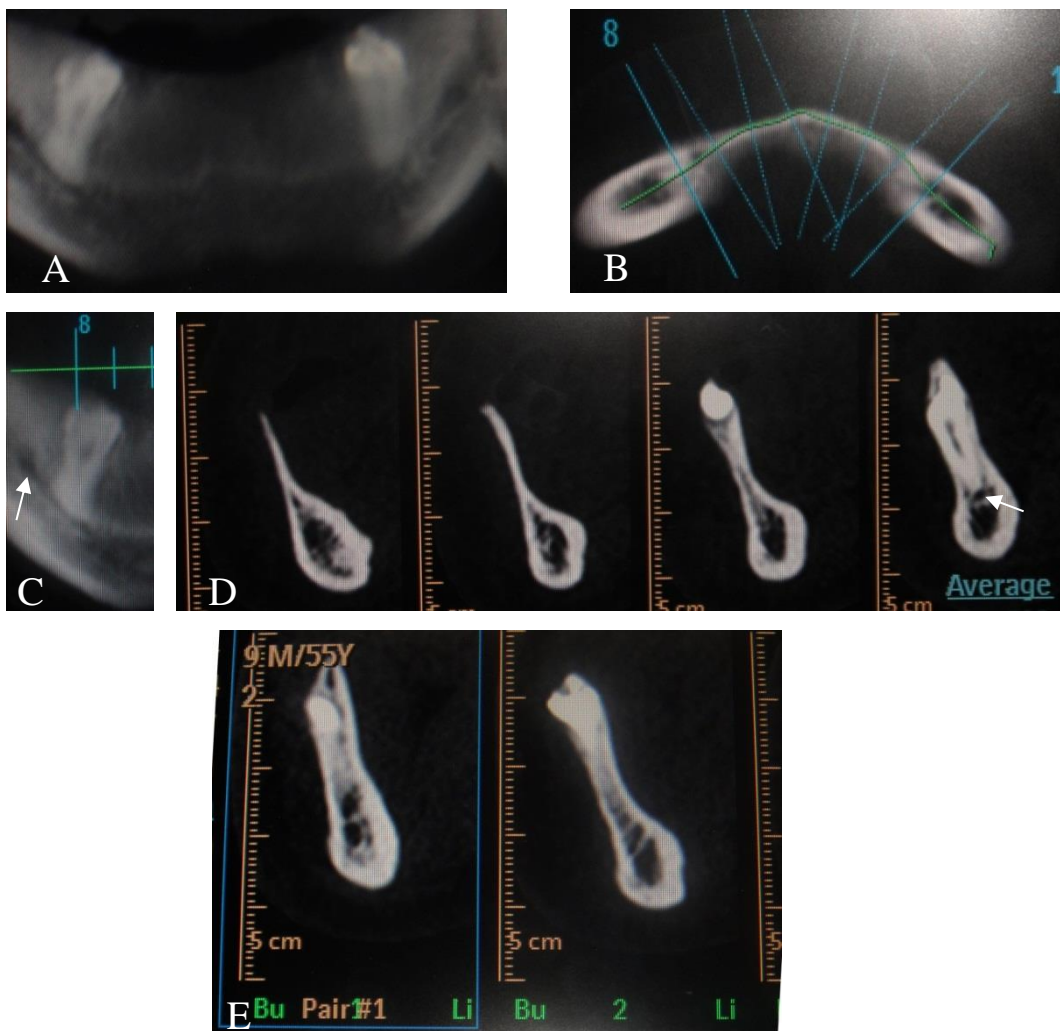


Fig.(4):- Dental Software CT views of mandible for patient with 50 years old with the complete impacted left premolar A. axial slice of mandible; B. axial slice with planning lines; C. panoramic section shows the apex of lower right impacted premolar within the mandibular canal (white arrow); D and E. multiple cross sections sagittal views of left and right of the impacted premolar teeth respectively, the mandibular canal is visible as a small cortical ring (white arrow).

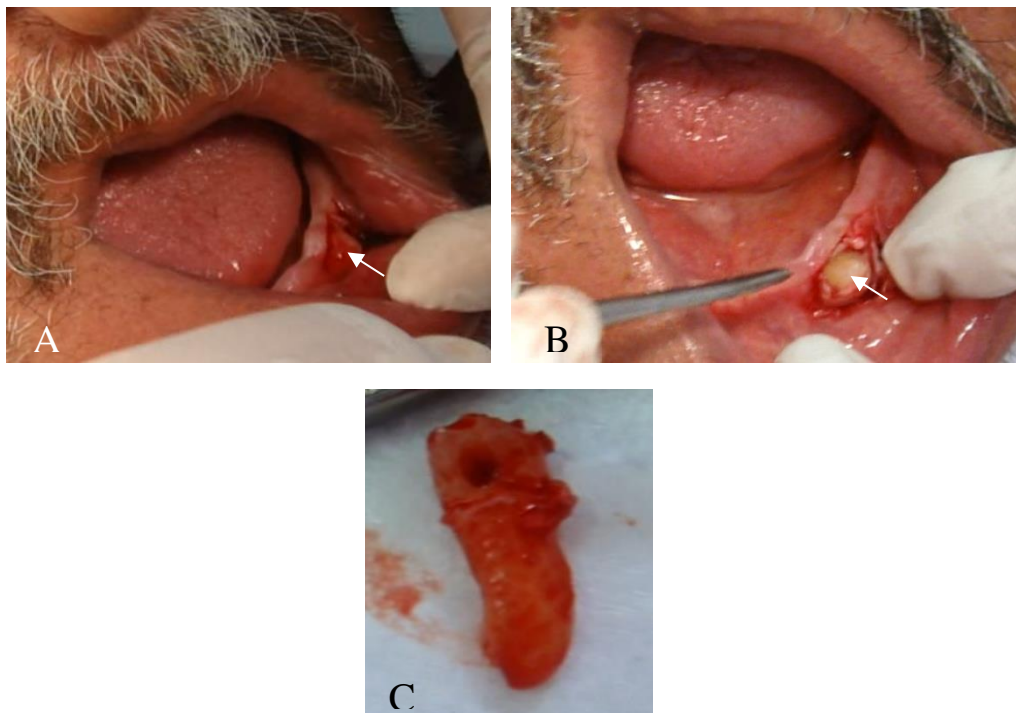


Fig.(5):- Transoperative images sides for the same case of figure 1: A, Surgical expose of Bone which completed cover the impacted lower left premolar tooth; B . Crown expose of tooth; C. lower left premolar after its surgical removal.

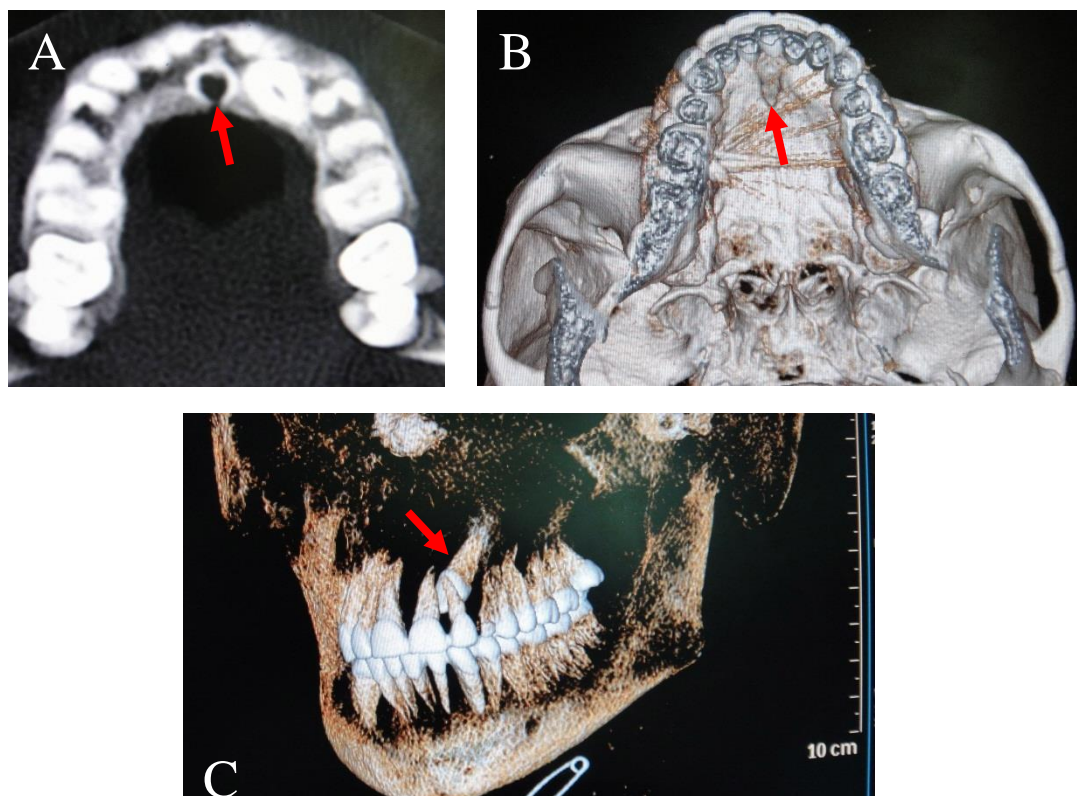


Fig.(6):- Dental 3D Software CT with multiplanner reconstruction of maxilla for female with 17 years old demonstrating the relationship between the left upper palatal impacted canine and other anterior teeth(red arrows). A. axial slice. B. axial section of maxilla. C. frontolateral view of the upper and lower jaws.

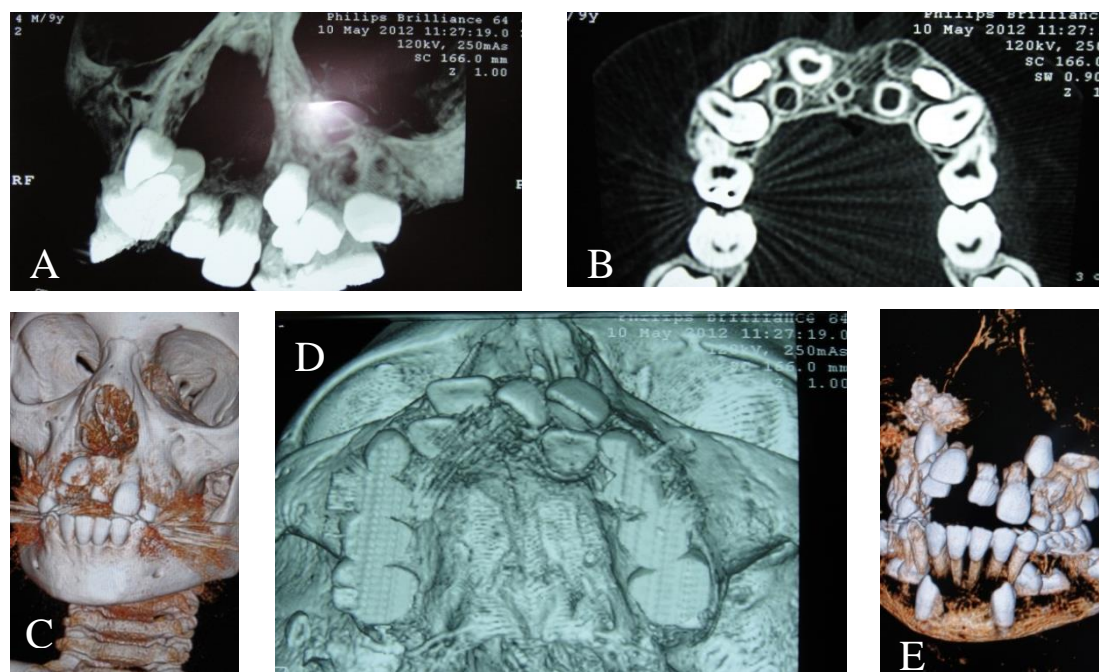


Fig. (7):- Dental 3D Software CT with multiplaner reconstruction of premaxilla demonstrating a multiple anterior impacted teeth for the patient aged 12 year A. frontal view B. axial slice C. and D. 3D CT frontal images and E. 3D CT axial view of maxilla.

Table (1):- Incidence of surgical treatment related to the impacted teeth type.

Type of impacted tooth. maxillary	No. and % of impacted teeth	
	NO	%
Incisor	1	2.5
Canine	7	17.5
Premolar	6	15
Molar	2	5
Mandibular		
Incisor	0	0
Canine	2	5
Premolar	3	7.5
Molar	19	47.5
Total sample	40	100

Table (2):- Assessment the position of 11 impacted teeth crowns by 2D radiograph, 3D CT and surgical exposed crown procedure findings.

Types of impacted teeth	No. of (ITC) by 2D rad.	Position type of (ITC) by 2D rad.	No. of (ITC) and position type by 3D CT	Position of surgical flap for exposing (ITC).
Upper central	1	**type II	*1 type I	Labially
Upper canine	4	type I	1 type I, 3 type II	1 Labially, 3 Palatally
	2	type II	1 type II	Palatally
			1 type I	Labially
Upper premolar	1	type II	1 type I	Buccally
Lower canine	2	1type I, 1type II	1 type II, 1 type I	2 Buccally
Lower premolar	1	type I	1 type I	Buccally
Total	11		11	
	Incorrect : 8(72.72%) Correct: 3(27.27%)		Correct: 11(100%)	

Impacted teeth crowns(ITC),radiograph (rad.), * Labially= type I, **Palatally= typeII, 2D rad. Incorrect: 8(72.72%) Correct: 3(27.27%), 3D CT Correct: 11(100%)

Table (3):- Assessment the position of 29 impacted teeth crowns by 2D radiograph, 3D CT and surgical procedure findings.

Type of tooth	No. of (ITC)	Position of (ITC) by 2D rad.	No. of (ITC)	Position of (ITC) by 3D CT scan		Type & position of surgical flap for removal the (IT)
Upper canine	1	type I horizontal	1	type II horizontal	1	2 sided palatal flap
upper premolar	2	type II	2	1 type I, 1 type II	1 1	2 sided buccal flap 2sided palatal flap
	2	*** type III	2	1 type I, 1 type II	1 1	2 sided buccal flap 2sided palatal flap
	1	type I	1	type II	1	2 sided palatal flap
upper molar	1	type II	1	type I	1	2 sided bucca l flap
	1	type I	1	type III	1	2 sided buccal flap
lower premolar	2	type III	2	type I		Envelope flap
lower 3rd molar	9	type I	8 1	type II type I	8 1	Envelope flap, 2 sided buccal flap
	4	type II	2 1 1	type II, type I, type III	2 2	2,Envelope flap.2,2 sided buccal flap
	6	type III	1 4 1	type I, type II, type III	3 3	Envelope flap. 2 sided buccal flap
Total	29		29		29	
Incorrect :25(85.3%) Corret :4(13.7%)				Corret : (100% 29)		

Impacted teeth (IT),***labio-platally=type III 2D rad. Incorrect :25(85.3%) Corret :4(13.7%) ,3DCT Corret :29(100%) .

Table (4):- Comparison of 2D radiograph and 3D CT and surgical findings in 40 cases.

Degree of success	No.&% of (ITC) by 2D radiograph	No.&% of (ITC) by 3D CT	No.&% of (IT) by surgical procedures
Successful	7 (17.5)	40 (100)	40 (100)
Non successful	33 (82.5)	0 (0)	0 (0)
Total	40(100%)	40(100%)	40(100%)

References

- 1-Jin-Soo Kim .Cone beam computed tomography findings of ectopic mandibular third molar in the mandibular condyle: report of a case. Imaging Science in Dentistry. 2011; 41(3): 135–137.
- 2-Adrian Becker, Stella Chaushu, Nardy Casap-Caspi,.Cone- beam Computed Tomography and Orthosurgical Management of Impacted Teeth.The Journal of the American Dental Association October 2010 ; 141 (3) sup: 145-185.
- 3-Liu D, Zhang W, Zhang Z, et al. Exact Localisation of Impacted and Supernumerary Teeth by Cone Beam Surg Oral Med Oral Pathol Oral Radiol Endod 2009; 38:24
- 4-Isaacson KG, Thom AR, Horner K, Whaites E. Orthodontic Radiographs: Guidelines. 3rd ed. London: British Orthodontic Society; 2008:14
- 5-Liu D, Zhang W, Zhang Z, et al. Localization of impacted maxillary canines and observation of adjacent incisor resorption with cone-beam computed tomography. Oral Surg Oral Med Oral Pathol Oral Radiol Endod 2008; 105:91-98.
- 6-Tantanapornkul W, Okouchi K, Fujiwara Y, et al. A comparative study of cone-beam computed tomography and conventional panoramic radiography in assessing the topographic relationship between the mandibular canal and impacted third molars. Oral Surg Oral Med Oral Pathol Oral Radiol Endod 2007; 103:253-259.

- 7-Royal SH, Hedlund GL, Wiatrak BJ . Single central maxillary incisor with nasal pyriform aperture stenosis: CT diagnosis prior to teeth eruption. *Pediatr Radiol* 1999; 29: 357-359
- 8-Solar P, Gahleitner A. Dental CT in the planning of surgical procedures. Its significance in the viewpoint of the dentist. *Radiologe* .1999;30: 1051-1063.
- 9-Abrahams JJ, Berger SB. Oral maxillary sinus fistula (oralantral fistula) :clinical features and findings on multiplanner CT .*Am J Roentgenol* 1995;165:1273-1276.
- 10-Abrahams JJ, Hayt MW. Dental CT in pathologic changes of the maxillo-mandibular region. *Radiologe* 1999;39:1035-1043.
- 11-Abrahams JJ, Berger SB . Inflammatory disease of the jaw :appearance on reformatted CT scans. *Am J Roentgenol* 1998;170:1085-1091.
- 12-Bodner L, Bar-Ziv J, Kaffe I . CT of cystic jaw lesions. *J Comput Assist Tomograph* 1994; 18:22-26.
- 13-Ken Serota .Cone Beam Computed Tomography :How safe is CBCT for your patients ?. *Dental Space Planner. Dentistry IQ RDH* 2012 2: 8336-8397.
- 14-Becker A, Chaushu G, Chaushu S. Analysis of failure in the treatment of impacted maxillary canines. *Am J Orthod Dentofacial Orthop* 2010;137(6):743–754.
- 15-Aboudara C, Nielsen I, Huang JC, Maki K, Miller AJ, Hatcher D. Comparison of airway space with conventional lateral headfilms and 3-dimensional reconstruction from cone-beam computed tomography. *Am J Orthod Dentofacial Orthop* 2009; 135.(4):468–479.
- 16-Isidoro C B, Nieves A M, Leonardo B A, Cosme G E. Validation of a computer - assisted system on classifying lower third molars . *Med Oral Patol Oral Cir Bucal*.2011; 16(1):68-73.
- 17-Becker A, Kohavi D, Zilberman Y. Periodontal status following the alignment of palatally impacted canine teeth. *Am J Orthod* 1983; 84(4):332–336.
- 18-Kohavi D, Becker A, Zilberman Y. Surgical exposure, orthodontic movement and final tooth position as factors in periodontal breakdown of treated palatally impacted canines. *Am J Orthod* 1984;85(1):72–77.
- 19-Wang CC, Kok SH, Hou LT, Yang PJ, Lee JJ, Cheng SJ, et al. Ectopic mandibular third molar in the ramus region: report of a case and literature review. *Oral Surg Oral Med Oral Pathol Oral Radiol Endod*. 2008;105:155–161. [[PubMed](#)].
- 20-Grover PS, Lorton L. The incidence of unerupted permanent teeth and related clinical cases. *Oral Surg Oral Med Oral Pathol*. 1985;59(4):420-425.
- 21-Bedoya MM, Park JH. A review of the diagnosis and management of impacted maxillary canines. *J Am Dent Assoc*. 2009; 140(12):1485-1493.
- 22-Ericson S, Kurol J. Radiographic examination of ectopically erupting maxillary canines. *Am J Orthod Dentofacial Orthop*. 1987;91 (6): 483-492.
- 23-Ericson S, Kurol J. Resorption of maxillary lateral incisors caused by ectopic eruption of the canines. A clinical and radiographic analysis of predisposing factors. *Am J Orthod Dentofacial Orthop*. 1988;94 (6): 503-513.
- 24-Dewel B. The Upper Cuspid: Its Development and Impaction. *Angle Orthod*. 1949;19(2):79-90.
- 25-Peck S, Peck L, Kataja M. The palatally displaced canine as a dental anomaly of genetic origin. *Angle Orthod*. 1994;64(4):249-256.
- 26-36. Peck S, Peck L, Kataja M. Sense and nonsense regarding palatal canines. *Angle Orthod*. 1995;65(2):99-102.
- 27-Becker A. The Orthodontic Treatment of Impacted Teeth. 2nd ed. Abingdon, England: Informa Healthcare; 2007:11–28.
- 28-Bodner L, Bar-Ziv J, Becker A. Image accuracy of plain film radiography and computerized tomography in assessing morphological abnormality of impacted teeth. *Am J Orthod Dentofacial Orthop* 2001; 120(6):623–628.
- 29-Allan G Farman, Willam C Scarfe . The Basics of Maxillofacial Cone Beam Computed Tomography. *Seminars in Orthodontics Volume 15, Issue 1* , 2009 :2-13.
- 30-Michael WV, Hildebolt CF, Conover G, et al. Three-dimensional dental imaging by spiral CT. *Oral Surg Oral Med Oral Pathol Oral Radiol Endod* 1997;84:561-570.
- 31-Bjerklin K, Ericson S. How a computerized tomography examination changed the treatment plans of 80 children with retained and ectopically positioned maxillary canines. *Angle Orthod* 2006;76(1):43–51.
- 32-Eric H, Sturat A G, Janice S L, et al., : Comparative analysis of traditional radiographs and cone-beam computed tomography volumetric images in the diagnosis and treatment planning of maxillary impacted canines. *American Journal of Orthodontics & Dentofacial Orthopedics* 2010;137(5):590-597.
- 33-Eric H, Shafaa H.A. A specific focus imaging for dental implant planning (CT-Based). *Abstract Book Of The First National Conference For Iraqi Dental Colleges* 2012:48-49.