

Two-Parts Bilateral Dse-Hinge Design Maxillary Denture Stabilizer

Nadira A. Hatim BDS, MSc.⁽¹⁾
Ahmed I. Al-Khyet BDS⁽²⁾

Key words

dse-hinge design,
maxillary denture
stabilizer.

Abstract

Nowadays, the adult patient male or female demand for esthetic as a first choice in relation to other factors. The current case report introduces a technique of treating a young patient with complicated problems of bad condition of remaining teeth with partially edentulous arch. In this study a new precession attachment (Dse-HINGE) design was used to make prosthodontic appliance more comfortable, and esthetically acceptable than traditional design removable partial denture. The results of this procedure showed a successful clinical treatments with fixed bridge and new Dse-Hinge attachment removable prosthesis. Finally, patient remarks a preferable esthetic, stabilization, retention, and more comfortable function results of fixed prosthesis with Dse-Hinge attachment in relation to previous conventional removable prosthesis.

Introduction

Many individuals seek dental treatment for esthetic reasons, that is, the desire to look more attractive by improving the smile⁽¹⁾. Remaining teeth can help aesthetics by preserving alveolar bone form. Teeth can be incorporated into a restoration using gold copings, or precision attachments, however the degree of support provided by teeth in such a restoration is debatable⁽²⁾. Precision attachments significantly enhance the retention of removable partial dentures. Their use eliminates the need for visible retentive and support components, especially in esthetic areas⁽³⁾. Hinge type of attachments resists any lateral tipping, rotational, and sliding forces. Hinge resilient attachments provide almost 30–35% load relief to the supporting implant. Each time one utilizes an attachment that

provides hinge resiliency, the vertical components of the masticatory forces are shared between the attachments, and the posterior portions of the residual ridge, the buccal shelf, and retro molar pad⁽⁴⁾. Dse-Hinge: it is an auxiliary type of attachment that is used in conjunction with conventional partial dentures⁽²⁾. The use of "fixed bridge" connected to the "Dse-Hinge" attachment made the attachment have strong retention derived from good properties for abutment teeth and utilizations of unfavorable undercut by preventing unidirectional path of insertion which limits available undercut, and the use of this type of attachment "Buccal-natural undercut" being correctly used⁽⁵⁾. Aims of study were to use new precession attachment (Dse-HINGE) design to make prosthodontic appliance more comfortable, and esthetically acceptable than traditional design removable partial denture.

(1)Prof., Department of Prosthodontics, College of Dentistry, University of Mosul.

(2)Dentist, Department of Prosthodontics, College of Dentistry, University of Mosul.

Case Report

A 40-year-old male with an unremarkable medical history was referred to the Department of Prosthodontics, College of Dentistry, University of Mosul, with a chief complaint of dissatisfaction of his situation, and the previous dental treatment he had received. At the time of the first appointment, a throughout examination for the patient was started. Intra-oral examination revealed that the remaining teeth were badly carious, although heavily restored, but the clinical, and radiographical examination showed secondary caries beneath the restorations (Figure 1, and 2). The patient had some discomfort around the anterior segment "Anterior Teeth"; multiple "Periapical abscesses" had been found on the upper right lateral incisor, and cuspid teeth; and the upper left cuspid; besides the presence of staining, and mal-positioning of the teeth from the anatomical form, and resorbed distal free end extended area. After careful analysis of the clinical problems of this case, the possible design which would provide both an acceptable aesthetic, and functional results, was the two-parts bilateral Dse-Hinge denture with fixed prosthesis.

Technical Work

Apisectomy and endodontic treatments were performed which involved the removal of the lesions from the periapical areas; and filling of the root canals with definitive restorations; and after a period of 14 days the suture has been removed. Crowns of the upper right lateral incisor, and cuspid, (right and left) teeth were built up by light cure composite filling for providing adequate crown length (Figure 3). Abutment teeth preparation was done including reduction of about (1-1.5mm.) from each tooth to provide adequate crown-size to hold both fixed bridge and (Dse-hinge)attachment. Two steps final impression was recorded by using silicone impression material(Base: dimethylsiloxan, and Accelerator: organic ester alkyl silicate). After construction of fixed bridge with Dse-HINGE attachment

Vitallium alloy, Try-in step was done to check the appliance in the patient mouth (Figures 4). After placement of prosthesis intra orally (Figure 5), each three months for one year follow up was done. Patient remarks about esthetic, function, retention, and stability, were better than the previous conventional removable prosthesis.

Discussion

The treatment option for a fixed prosthesis, and RPD with hinge attachments has been achieved as an alternative treatment to conventional denture⁽⁶⁾. The patient in this clinical report was satisfied with function, esthetics, and decreased compression of the edentulous ridge in function. These results depend on the patients remark, that an improvement in chewing efficiency, and function was observed. Chewing movements became more balanced, stabilizer, and regular than those executed with RPDs⁽⁷⁾. Apart from improving aesthetic and retention of removable partial denture, the availability of the precision attachments have made designing of removable partial denture becomes more flexible⁽⁸⁾.

Conclusions

As a conclusion, removable partial denture still has a good place as a treatment option in replacing missing teeth. With proper case selection and treatment planning, precision attachment Des-Hinge can be used to improve retention and aesthetic of Vitallium alloy removable partial denture. Maintenance, and recall patient should be for routine oral hygiene; and patient should be reviewed every three months regarding time of delivery.

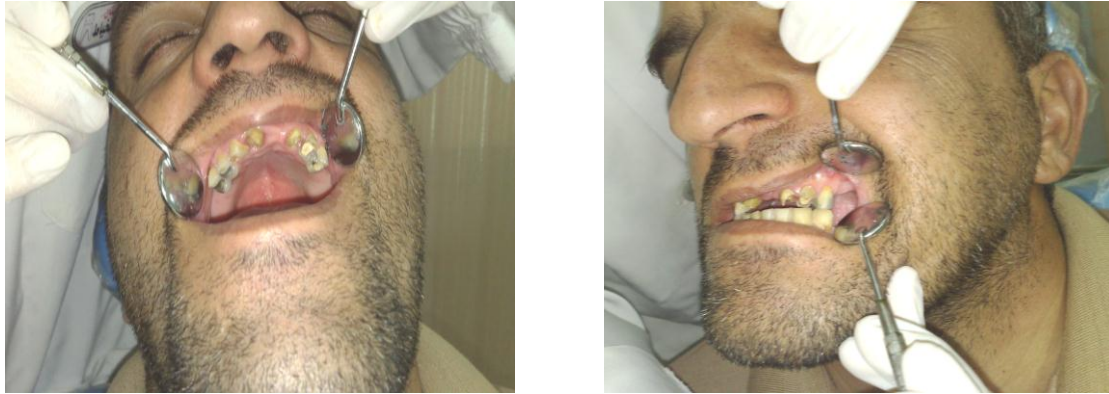

Fig.(1):- Different views of intra oral examination.

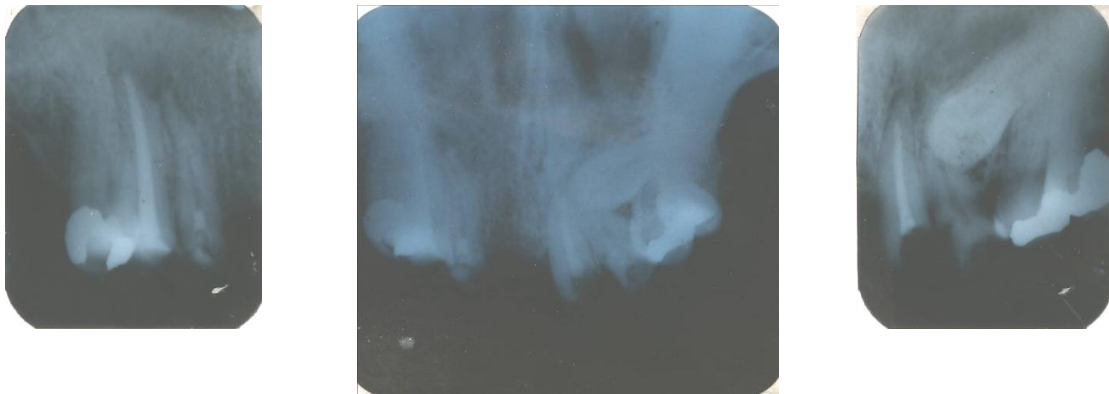


Fig.(2):- Radio-graphical examination of the remaining teeth.

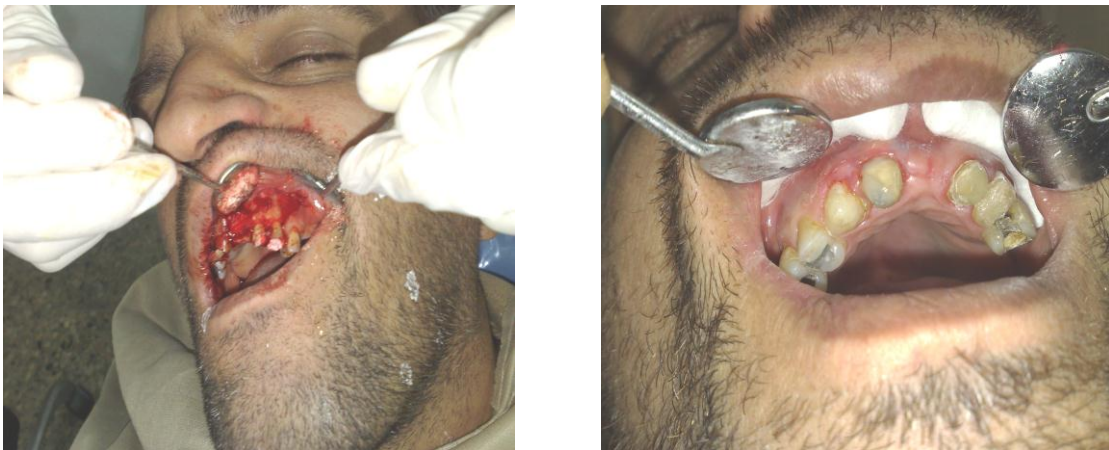

Fig.(3):- Surgical Endodontic treatment, and restoration of maxillary anterior teeth.

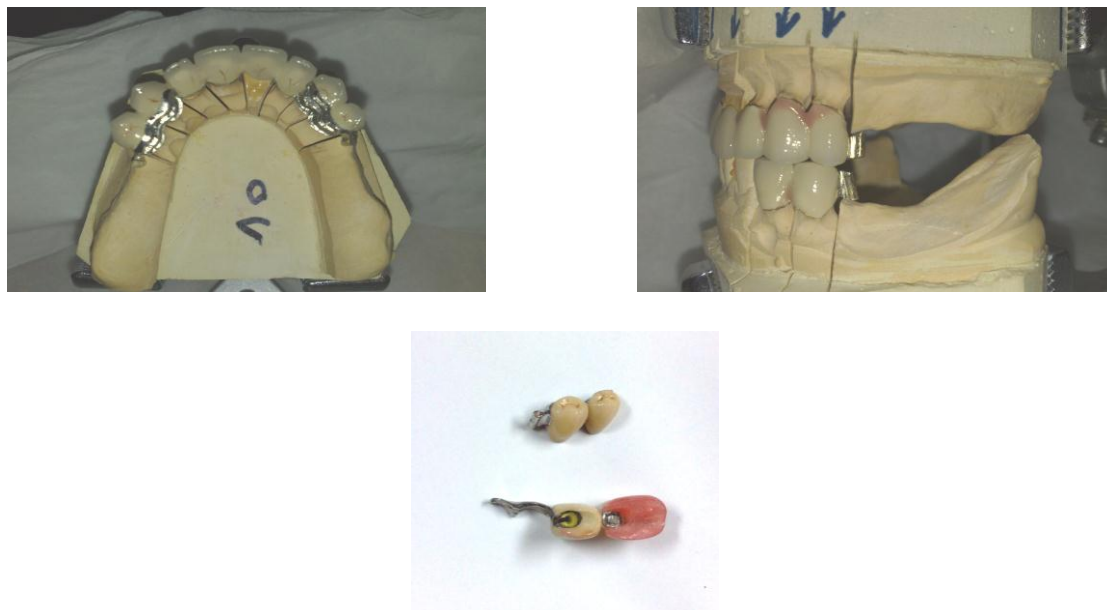


Fig.(4):- Fixed Bridge with Dse-Hinge attachment removable prosthesis.

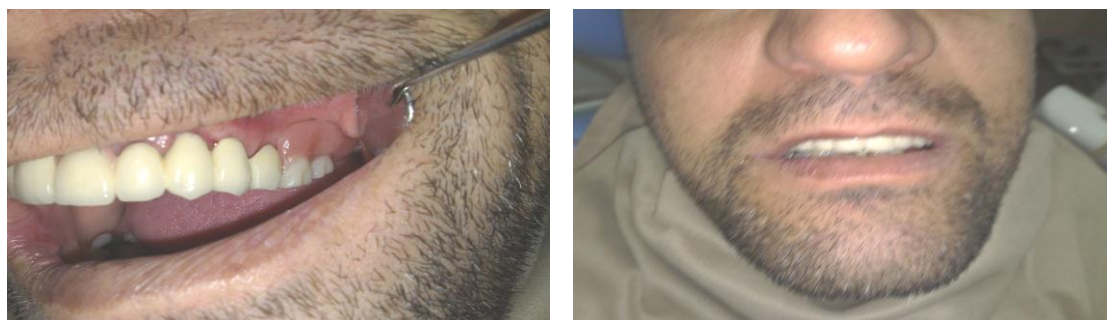

Fig.(5):- intra oral fixed prosthesis with Dse- Hinge attachment.

References

- 1- Renner RP. An Introduction to Dental Anatomy and Esthetics. Chicago: Quintessence 1985; 241-273.
- 2-Howe L, Palmer P, Barrett V. Advanced restorative Techniques. Br Dent J. 1999; 187: 11.
- 3-Lynch CD and Burke FM. An impression technique for optimal positioning of precision attachments for removable partial dentures. J Prosthet Dent. 2003;89(6):616-7.
- 4-Nickalás E. Clinical and laboratory manual of implant overdentures. Implant Dent. 2008; 17(3):234-235.
- 5-Barclay CW, RusseL MD, Murphy P. A three-part bilateral swinglock design revisited. Br Dent J. 2001; 190(10):538-540
- 6- Dong JK, Jin TH, Cho HW, Oh SC. The esthetics of the smile: a review of some recent studies. Inter J Prosthodont 1999;12:9-19.
- 7-Pellecchia M, Pellecchia R, Emtiaz S. Distal extension mandibular removable partial denture connected to an anterior fixed implant-supported prosthesis: A clinical report. J Prosthet Dent. 2000;83:607-12.
- 8-Awang RAR, Arief EM, Hassan A. Spring loaded plunger attachment for retention of removable partial denture: a case report. Archives of Orofacial Sciences. 2008; 3(1): 32-35