

Comparison Between High- Resolution Ultrasonography and Conventional Radiography in the Diagnosis of Nasal Bone Fractures

Zainab Mahmood AL-Bahrany BDS, MSc.⁽¹⁾

Lamia H. AL-Nakib BDS, MSc.⁽²⁾

Key words

Ultrasonography,
Nasal bone,
Fractures.

Abstract

Objectives to describe the diagnostic findings of ultrasonography in nasal bones fractures and to determine the validity of classical clinical practice assisted by radiography in the diagnosis of nasal bone fractures and compared it to the value of ultrasonography.

A total sample of 53 patients (11 females and 42 males) at age range (14-40) years, with a differential diagnosis of nasal fracture based on history of nasal trauma and physical signs and symptoms of nasal bone fracture. All subjects had a true lateral soft tissue profile view of the face and high resolution ultrasonography in addition 8 patients had an occipitomental view based on physician request. The radiographs and ultrasound images of each subjects were analyzed and reports were recorded as either "positive" or "negative" according to the existence of nasal bone fracture with other details about the fracture if present (number of the fracture lines detected, the type of the fracture, its location and assessment of the soft tissue swelling and hematoma). The results were analyzed by various statistical testing methods (for sensitivity, specificity, positive and negative predictive value, and accuracy). The sensitivity to established clinical diagnosis (based on crepitation and mobility) in diagnosis of nasal bone fracture was 76.6% (23.4% false – ve rate). This figure is increased to 89.4% (10.6% false – ve rate) when clinical decision is aided by radiography. Such a practice however is associated with low specificity (33.3%). Using ultrasonography will increase both sensitivity and specificity to 100%.

The conclusion of this study is the ultrasonography in diagnosis of nasal bone fracture is superior to radiography and it is recommended to shift the classical clinical approach from radiography to ultrasonography in this context.

Introduction

The nasal bones fracture is one of the most common fractures among the facial bones in patient with maxillofacial injury⁽¹⁾ owing to their prominence, central position and the minimal force required

for fracture⁽²⁾. Conventional radiographs are excellent for the depiction of skeletal trauma. However, fractures may at times be imperceptible on conventional radiographs either because it is subtle or occult, obscured by overlapping structures, or non-perpendicular to the x-ray beam; a fracture may also involve cartilage and be undetectable, especially in skeletally-

(1) Assist. Lecturer, Department of Oral and Maxillofacial Radiology, College of Dentistry, University of Baghdad.

(2) Assist. Prof. Department of Oral and Maxillofacial Radiology, College of Dentistry, University of Baghdad.

immature children. Therefore complementary imaging would be desirable to eliminate or confirm the presence of a fracture in order to avoid short-term and long-term complications. ⁽³⁾ High frequency ultrasound with a linear array transducer performed as an alternative to radiography for the initial diagnostic work up ^(4, 5, 6). Ultrasonography has been described as a useful method for the initial detection of fractures in midfacial region (nasal bone, the orbit and zygomatic arch), mandibular fractures and screening for dubious fractures ⁽⁵⁾. It is a useful problem-solving tool when symptoms are present and radiographs are unrevealing ⁽⁷⁾. Ultrasonography may be valuable due to its many advantages: relatively inexpensive, readily available, non-invasive, high accuracy, and highly effective in the detection of fractures, with accuracy up to 87% in some series ⁽⁸⁾. Nasal Radiographs have a high number of false-negative results and a large but unknown number of false-positive results. Thus, the legal value is low because of the uncertain degree of confidence in the findings ⁽⁹⁾ Ultrasonography has no known harmful effects and no contraindications. It is quick and relatively inexpensive compared with CT or MRI ⁽¹⁰⁾. It is an imaging technique that could be performed by the maxillofacial surgeon himself, because (especially in Europe) most of the departments have their own ultrasound machine. Therefore, it would be a diagnostic imaging technique that leads to a quick diagnosis within a few minutes ⁽¹¹⁾.

Materials and Method

This prospective study was carried out from July 2009 to January 2010 on patients with suspected nasal bone fracture selected from:

1. Consultant clinic of oral and axillofacial surgery in Specialized Surgical Hospital.
2. Consultant clinic of E.N.T of Baghdad Teaching Hospital.
3. The emergency Room (ER) of Baghdad Teaching Hospital

All subjects participated in this study were well informed about it, asked to co-

operate, and get their approval before including them. The sample consisted of (53) patients, (11) females and (42) males, their ages ranged from (14-40) years with a mean average age of (24.3) years were selected according to clinical signs and symptoms of nasal bone fracture (deviation and asymmetry, crepitation, mobility, epistaxis, nasal swelling, periorbital ecchymosis and a specific point of tenderness). Patients with: Previous nasal bone fractures, open wound, pregnant women and who refused to undergo ultrasonographic examination, were excluded from the study. Twelve males volunteers have neither any history of nasal trauma nor any clinical signs and symptoms of nasal bone fracture underwent the ultrasonographic nasal bone examination only which was negative (-ve) in all of them yielding a specificity of 100% for ultrasonography. After careful history taken from each patient (or his / her relatives), clinical examination was done started by external nasal examination (inspection and palpation) then followed by internal nasal examination. Then conventional radiographical examination was done using the true lateral soft tissue profile view for nasal bone (with soft tissue technique's exposure factors: (50) kVp and (5) mAs) for all patients. the patients positioned with the head turned 90° and the x-ray tube head positioned with central ray perpendicular to the sagittal plane and the image receptor. Some of patients were requested for occipitomental (Waters') view with the central ray at (37°) horizontal to assess the lateral nasal wall in addition to true lateral soft tissue profile view, the images were evaluated, then the reports were recorded as either "positive" or "negative" according to the existence of nasal bone fracture with other details about the fracture if present: the number of the fracture lines detected, the type of the fracture, its location, and assessment of the soft tissue swelling and hematoma. The ultrasonographic examination was done by using (Sono line versa pro.) Siemens device, with B mode, gray scale, real-time scanner, using (7.5 MHz) linear array transducer, every subject was examined in supine position, liberal amount of

aquasonic material as coupling agent was applied to transmit the sound impulses from the transducer directly in to the examined area. The ultrasonic images were taken at different levels, Fig.1 (A, B):

- Midline longitudinal scan on the dorsal surface of the nasal bones.
- Axial scan on the dorsal surface of the nasal bones at different level.
- Left and right longitudinal scan and transverse scan of both lateral walls.

The ultrasonographic findings were divided into two groups:

1. The positive criterion of nasal bone fracture was appear as cortical disruption or discontinuity of the normal cortical margin of the nasal bones, reverberation echo and focal increase in the degree of posterior acoustic shadowing at the fracture site (these were the direct signs of fractures), while the (heterogeneous hypoechoic) soft tissue edema and subperiosteal hematoma was also examined as a possible predictor to differentiate an acute from a chronic fracture (indirect signs of fractures).
2. The negative criterion of nasal bone fracture (which means normal bone) was a hyperechoic smooth line cortex without step or defect, no ultrasound transmission is seen beyond the cortical bone. The reports were then recorded as either "positive" or "negative" according to the existence of nasal bone fracture with other details about the fracture if present: the number of the fracture lines detected, the type of the fracture, its location, and assessment of the soft tissue swelling and hematoma. An established clinical diagnosis of nasal bone fracture or a suspected clinical diagnosis of fracture based on history of nasal trauma and one or more of the suggestive signs and symptoms of nasal fracture in addition to a positive ultrasonographic diagnosis (since the ultrasonography is of 100% specificity) is considered an established (proven) fracture case.

Results

According to the final diagnosis of nasal bone fractures, Out of (53) patients, (47)

patients 88.7% were with fractured nasal bone. The conventional radiographical examination had 74.5% sensitivity (25.5% False-e rate). This figure increased to 89.4% (10.6% False-ve rate) when the clinical diagnosis was assisted by conventional radiography in the diagnosis of nasal bone fractures, such a practice however was associated with low specificity (33.3%), i.e. it can establish the diagnosis of nasal fracture with up to 91.3% only. A negative test on the other side is of limited usefulness, since it can exclude the presence of fracture with 28.6% confidence only as shown in table (1) and (2). The ultrasonographic examination was able to establish the fractured nasal bones with a sensitivity and accuracy of 100% as shown in table (3). A positive diagnosis is 100% specific, yielding a PPV of 100%, i.e. a positive test can establish the diagnosis with 100% confidence. This aspect of the test is an assumed one (since it is included in the definition of real nasal fractures and depended on a very small sample of really negative control subjects tested). A negative test on the other hand can exclude a possible diagnosis of nasal bone fracture with 100% confidence (NPV=100%).

Discussion

The complexity of the facial bones and the density of the cranial base make the conventional radiography inadequate for fractures of the facial bones⁽¹²⁾. Low accuracy rate usually associated with nasal bone radiographs due to high percentage of false-negative and false-positive results⁽¹³⁾. This study revealed that the conventional radiographical examination reported (39) patients with fractured nasal bones. Only (35) patients were established cases by the final diagnosis. These misdiagnosed cases could be the result of the misinterpretation of normal suture lines that usually associated with occipitomenal view or a result of thinning nasal bones, presence of blood vessels, on the other hand the conventional radiographical examination reported (14) patients without nasal bones fractures.

Only (2) patients were really without fracture by the final diagnosis. This due to the inability of conventional radiography to detect thin and short radiolucent fracture lines which are often referred to as “hairline fractures” or due to overlapping. This yielded 74.5% sensitivity (25.5% False-ve rate) for conventional radiography to diagnose nasal bone fractures. This figure increased to 89.4% sensitivity (10.6% False-ve rate) when the clinical diagnosis assisted the conventional radiography in the diagnosis of nasal bone fractures because the primarily diagnosis of nasal fracture can be done by careful physical examination. This result of our study is in agreement with Oliver et al. ⁽¹⁴⁾ study which found that the final assessment of nasal pyramid by radiography reached a specificity of 38% (In their study, assessment of the nasal dorsum by radiography reached a sensitivity of 82% and a specificity of 69%. For the lateral nasal walls, a sensitivity of 52% and a specificity of 49% were achieved). Another study by Gurkov et al. ⁽¹⁵⁾ revealed that the detection of fractures on the nasal dorsum by radiography had a sensitivity of 88% and specificity of 95%. In lateral nasal wall fractures, Sensitivity was 28% and specificity was 75%. This study was performed to prove the validity of using sonography versus plain x- rays in diagnosis of nasal fractures. Based on the small study sample of (53) patients , the ultrasonographical diagnosis of nasal bones fractures had a perfect validity, and by using a larger samples this may turn it out to be slightly less than perfect. It was found that the ultrasonographical diagnosis of nasal bone fractures using 7.5 MHz linear array transducer yielded 100% accuracy and 100% sensitivity. This is agreed with Beck et al. ⁽¹⁶⁾ study that revealed all nasal bone fractures diagnosed by radiography also could be detected by ultrasonography. It is also in agreement with Kwon et al. ⁽¹⁷⁾ study that showed a positive correlation between ultrasonography and computed tomography. Hong et al. ⁽¹⁸⁾ found that the sensitivity of ultrasonography in diagnosing nasal bone fracture is more than radiography. In another study carried out by Lee et al. ⁽¹⁹⁾

on patients with nasal trauma were examined by high-resolution ultrasonography (using 7-15 MHz linear array transducer) and computed tomography to diagnose the nasal bone fracture, found that the accuracy rates for high-resolution ultrasonography, computed tomography and conventional radiography in detecting nasal bone fractures were 100%, 92.1% and 78.6% respectively. Mohammadi et al. ⁽²⁰⁾ found that the sensitivity of ultrasonography and conventional radiography in diagnosing nasal bone fractures was 90.2% and 77.6%, respectively, while the specificity was 98.5% and 82% respectively. Danter et al. ⁽²¹⁾ found that the assessment of the nasal fracture yielded a sensitivity of 83% if the clinical diagnosis was used as the reference and a sensitivity of 94% if the radiography results were considered with ultrasonography. These data are similar to the results reported in Oliver et al. ⁽¹⁴⁾ found that accuracy of ultrasonography is more than radiography in diagnosing the fracture lines reached a sensitivity of 77%. The findings of our study revealed that the ultrasonography could even show any boney disruption and minimal displaced fracture lines because the ultrasonography is a repeatable and any area of fracture suspension can be reexamined as often as is necessary until reach a clear diagnosis, also it is fast and safe. This is agreed with Hirai et al. ⁽²²⁾ to evaluate the ultrasonographical observation of facial bone fractures, they were able to identify even a 0.1 mm bone disruption using ultrasonography. Ultrasonography in the present study also showed a perfect assessment for angulated (depressed or overriding) type fractures and perfect assessment for comminuted type, since the ultrasonography is multiplanar image. The ultrasonography could assess any fracture lines whether they were on the dorsal surface of nasal bone, lateral surface or in fronto-nasal suture area. The examiner could get an anatomic correlation by probing any specific area with maximal pain and because our examination performed from different positions and level thus get good assessment about the boney site of fracture lines. The soft tissue swelling and hematoma that associated

with fractured nasal bones was detected even in mild degree this is due to fact that ultrasonography is ideally suited to the evaluation of the soft tissues. This our findings is in agreement with Hong et al. ⁽¹⁸⁾.

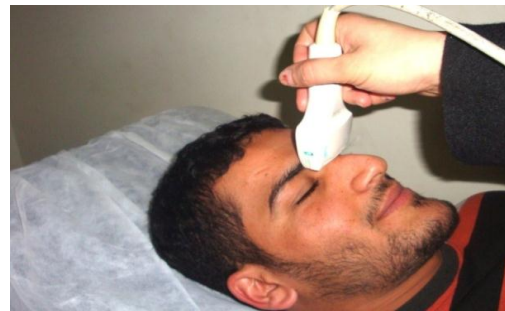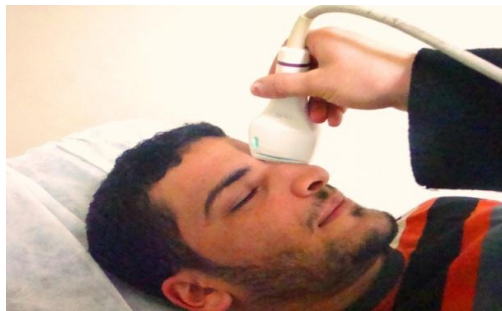Conclusions

1. Ultrasonography is a fast, cheap and accurate method for diagnosing nasal bone fractures in any locations (dorsally, laterally or in fronto-nasal suture area) and show anatomic details of the nose much better than conventional radiography.
2. Ultrasonography is an adequate diagnostic tool for assessment of any type of nasal bone fractures and ideal in assessment of the soft tissue swelling and hematoma that associated with fractured nasal bones even in mild degree.

3. The validity of clinical diagnosis to establish a nasal bone fracture is with an average value, but a slight improvement occurs when the clinical diagnosis was aided by conventional radiography. Using ultrasonography is with perfect validity and has a clear role in diagnosing nasal bone fractures when used as an alternative to conventional radiography.

Recommendation

Because of the high superiority of ultrasonography in diagnosing nasal bone fractures in addition to its availability, low cost, repeatable, fast and has no radiation hazard, so it is highly recommended to shift the classical clinical approach from conventional radiography to ultrasonography in this context.



A-Midline longitudinal scan.

B- Axial scan.

Fig.(1):- Subject adjusted in supine position to take ultrasonic images at different level.

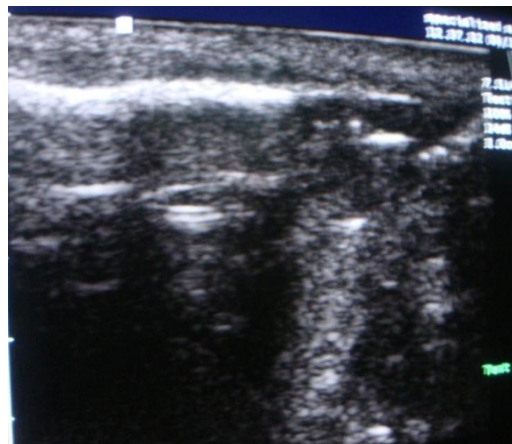


Fig. (2):- Normal ultrasonographic findings after nasal trauma.

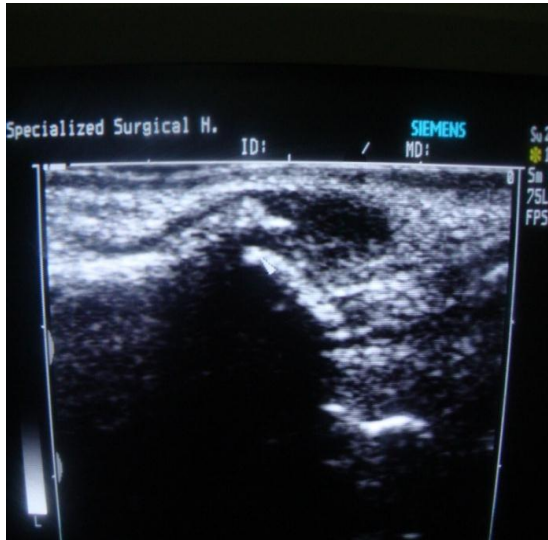


Fig. (3):- A- Longitudinal scan of nasal fractured bone.

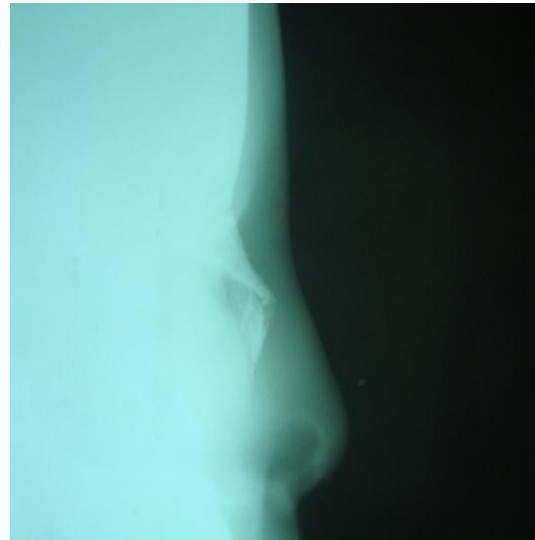


Fig. (3):- B-True lateral view of fractured nasal bone.

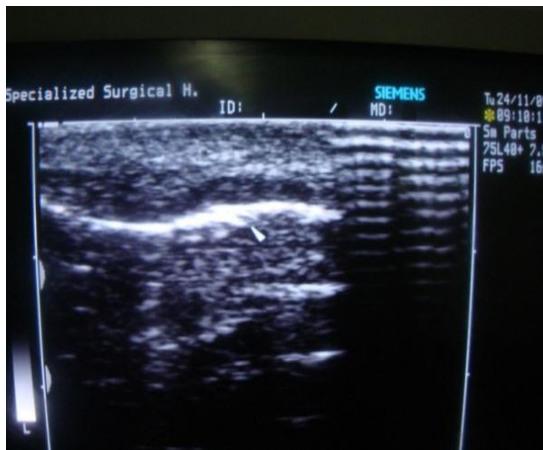

Fig. (4):- A- Longitudinal scan of nasal bone show non-displaced fracture line.

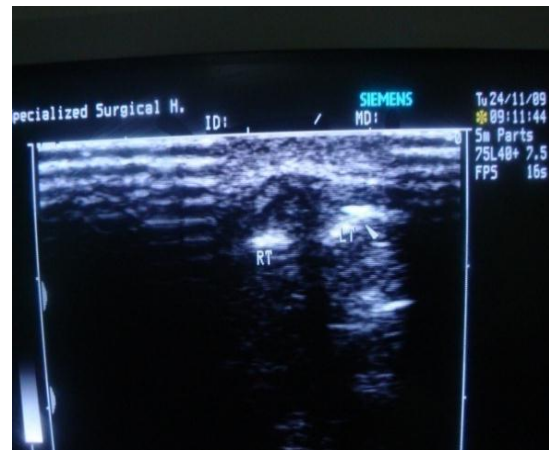

Fig. (4):- B- Axial scan of nasal bone show non-displaced fracture line.

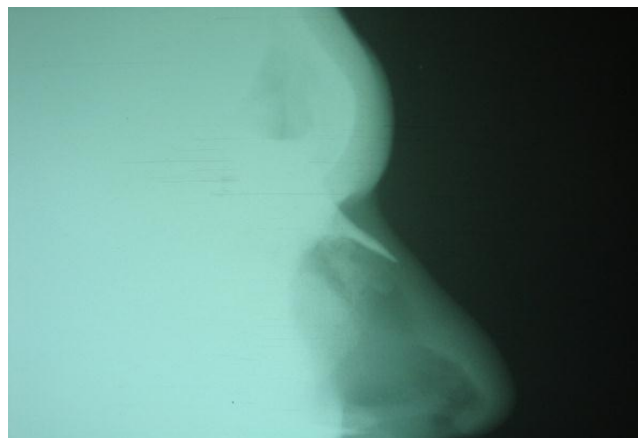

Fig. (4):- C-True lateral view of nasal bone show non-displaced fracture line.

Table (1):- Validity parameters of conventional radiography in the diagnosis of nasal bone fracture.

Presence of fracture line by X-ray	Final diagnosis of nasal bone fracture		
	Negative	Positive	Total
Absent	2	12	14
Present	4	35	39
Total	6	47	53

Sensitivity=74.5%, Specificity=33.3%, Accuracy=69.8%, PPV=89.7% NPV=14.3%, False +ve=66.7%, False-ve=25.5%.

Table (2):- Validity parameters of clinical diagnosis assisted by conventional radiography in the diagnosis of nasal bone fracture.

Clinical diagnosis assisted by X-ray findings of nasal bone fracture	Final diagnosis of nasal bone fracture		
	Negative	Positive	Total
Negative	2	5	7
Positive	4	42	46
Total	6	47	53

Sensitivity=89.4%, Specificity=33.3%, Accuracy=83%, PPV=91.3% NPV=28.6%, False +ve=66.7%, False-ve=10.6%.

Table (3):- Validity parameters of ultrasonography in the diagnosis of nasal bone fracture.

Presence of fracture line by US	Final diagnosis of nasal bone fracture		
	Negative	Positive	Total
Absent	6	0	6
Present	0	47	47
Total	6	47	53

Sensitivity=100%, Specificity=100%, Accuracy=100%, PPV=100% ,NPV=100, False +ve=0%, False-ve=0%.

Table (4):- Agreement between conventional radiography and ultrasonography in the presence a number of nasal bone fracture lines in study subjects

Presence of fracture line by X-ray	Presence of fracture line by US			Total
	Negative	(single # line)	(Double # lines)	
Negative	2	12	0	14
Positive (single # line)	4	27	7	38
Positive (Double # lines)	0	1	0	1
Total	6	40	7	53

Percent observed agreement = 54.7%, Percent Overestimated by US = 35.8%, Percent Overestimated by X-ray = 9.4%, P (McNemar-Bowker) = 0.014.

References

- 1-Hwang, K., You, S.H., Kim, S.G., Lee, S.I. (2006) Analysis of nasal bone fractures; a six-year study of 503 patients. *J Craniofac Surg.*, 17(2):261-4.
- 2-Fonseca, R. J., Robert, V. W., Norman, J. B., Barber, H. D., Michael, P. P. (2009) Oral and maxillofacial trauma. Vol.2, 3rd Ed. St. Louis: Elsevier. Saunders pp: 737-742.
- 3-Haddad, Z.S., Abi Khalil, S., Roukos, S., Menassa, M.L., Smayra, T., Aoun, N., Ghossain, M. (2008) musculoskeletal imaging. Limb fractures: ultrasound imaging features. *J Radiol*, 89:557-63.
- 4-McCann, P.J., Brockebank, L.M., ayoub, A.F. (2000) Assessment of zygomatico-orbital complex fractures using ultrasonography. *Br J Oral Maxillofac surg*, 38(5):525-529.
- 5-Friedrich, R.E., Heiland, M., Bartel-Friedrich, S. (2003) Potentials of ultrasound in the diagnosis of midfacial fractures. *Clin Oral Invest*, 7(4):226-229.
- 6-Jank, S., Emshoff, R., Etzelsdorfer, M., Strobl, H., Nicasi, A., Norer, B. (2004) Ultrasound versus computed tomography in the imaging of orbital floor fractures. *J Oral Maxillofac Surg.*, 62(2): 150-154.
- 7-Rumack, C. M., Wilson, S. R., Charboneau, J. W. (2005) Diagnostic Ultrasound. Vol. 2, 3rd Ed. St. Louis: Elsevier Mosby pp: 2035-2054.
- 8-Herneth, A.M., Siegmeth, A., Bader,T.R. et al. (2001) Scaphoid fractures: evaluation with high-spatial-resolution US initial results. *Radiology*, 220:231-5.
- 9-Illum, P. (1991) Legal aspects in nasal fractures. *Rhinology*, 29:263.
- 10-Cummings, C.W., Flint, P. W., Haughey, B. H., Robbins, K. T., Thomas, J. R., Harker, L.A., Richardson, M.A.,Schuller, D.E.(2005) Cummings Otolaryngology: Head and Neck Surgery.4th Ed. Philadelphia: Elsevier. Mosby.
- 11-Jank, S., Deibl, M., Strobl, H., Oberrauch, A., Nicasi, A., Missmann, M., Bodner, G. (2006) Intrarater reliability in the ultrasound diagnosis of medial and lateral orbital wall fractures with a curved array transducer. *J Oral Maxillofac Surg.*, 64:68-73.
- 12-Williamsó, J.LI. (1994) Rowe and Williamsó maxillofacial injuries. Vol. 1, 2nd Ed. Edinburgh: Churchill Livingstone pp: 149, 175- 176.
- 13-Logan, M., O'Driscoll, K., Masterson, J. (1994) The utility of nasal bone radiographs in nasal trauma. *Clin Radiol. Mar*, 49(3):192-4.
- 14-Oliver, T., Kromer, J.H., Rudack, C., Stoll, W., Osada, N., Schmal, F. (2005) Comparison of ultrasonography and conventional radiography in the diagnosis of nasal fractures. *Arch Otolaryngol He d Neck Surg.*, 131:434-9.
- 15-Gurkov, R., Krause, E., Clevert, D. (2008) Sonography versus plain x rays in diagnosis of nasal fractures. *Am J Rhinol*, Nov-Dec, 22(6): 613-6.
- 16-Beck, A., Maurer, J., Mann, W. (1992) Sonographic diagnosis of nasal bone fractures: Otorhinolaryngology. In: Record of the German society of Oto-Rhino-Laryngology, Head Neck Surgery. Stuttgart, Germany: Thieme Verlag p: 68.
- 17-Kwon, T.K., Cha, J.H., Kim, Y.W., et al. (1995) The Role of Ultrasound in the Diagnosis of Nasal Bone Fracture. New York, NY: Kugler Publications Amsterdam.
- 18-Hong, H.S., Cha, J.G., Paik, S.H., Park, S.J., Park, J.S., Kim, D.H. et al. (2007) High- resolution sonography for nasal fracture in children. *AJR Am J. Roentgenol*, 188: W86-92.
- 19-Lee, M.H., Cha, J. G., Hong, H. S., Lee, J. S., Park, S. J., Paik, S. H., Lee, H. K. (2009) Comparison of High-resolution ultrasonography and computed tomography in the diagnosis of nasal fractures. *J Ultrasound Med*, 28:717-723.
- 20-Mohammadi, A., Javadrashid, R., Pedram, A., Masudi, S. (2009) Comparison of ultrasonography and conventional radiography in the diagnosis of nasal bone fractures. *Iran J Radiol*, 6 (1): 7-11.
- 21-Danter, J., Klinger, M., Siegert, R., Weerda, H. (1996) Ultrasound imaging of nasal bone fractures with a 20 MHz ultrasound scanner. *HNO*, 44:324-8.
- 22-Hirai, T., Manders, E.K., Nagamoto, K., Saggars, G.C. (1996) Ultrasonic observation of facial bone fractures: report of cases. *J Oral Maxillofac Surg*, 54:776-9.