



Clinical and Radiological Outcome of Cavernous Malformation Treated by Gamma Knife Radiosurgery

Ali Hatem Jawad¹, Yasir Mohammed Hasan Hamandi²

ABSTRACT:

BACKGROUND:

Cavernous malformation is A well-circumscribed, benign vascular hamartoma consisting of irregular thick and thin-walled sinusoidal vascular channels located within the brain. lacking intervening neural parenchyma large feeding arteries, or large draining veins. Usually 1–5 cm in size, may haemorrhage, calcify or thrombose, choosing best method of surgical treatment is crucial in order to decrease the cavernoma size, rate of haemorrhage and associated neurological symptoms.

METHODS:

From Nov. 2021 to Dec. 2023 there were 40 cases of cavernous malformation treated by gamma knife radiosurgery at Dr. Saad Al-Witry Neuroscience Hospital by experienced neurosurgeon and approved for gamma knife radiosurgery all patients were followed up by clinical and radiological assessment.

RESULTS:

The mean age was (39.5 ± 5) years; (60%) of patients were males. The most prevalent sites of cavernous malformation were cortical followed by brainstem. Pre gamma knife the most common size was 2-2.9 cm³ (42.5%), meanwhile post gamma knife the most common size was 1-1.9 cms³ in (35%), in addition to (5%) of the cavernomas disappear completely. By McNemar test there was significant association between Gamma knife radiosurgery and decreasing rate of haemorrhage, as well as decreasing in prevalence rate of reported seizure, hemiparesis, hemisensory loss and cranial nerves deficits.

CONCLUSION:

Gamma knife radiosurgery.

KEYWORDS: Cavernous malformation, Gamma knife stereotactic radiosurgery, Haemorrhage.

¹M.B.Ch.B F.I.B.M.S/ (Neurosurgery), Al Immain Alkadhmin Medical City - Iraq.

²(M.B.Ch.B, F.I.B.M.S/ (Neurosurgery), Iraqi Board of Medical Specializations - Iraq.

Iraqi Postgraduate Medical Journal, 2026; Vol.25 (2): 161-167

DOI: 10.52573/ipmj.2025.156849

Received: February 16, 2025

Accepted: May 11, 2025



INTRODUCTION:

Cavernous haemangioma, cavernoma, cavernous angioma, or simply "cav-mal" in clinical terms is vascular hamartoma defined and consists of an assortment of irregularly shaped thick and thin-walled sinusoidal vascular channels located within the brain. No neural tissue is present, along with the absence of significant feeding arteries or major draining veins. The typical size ranges from 1 to 5 cm, as it has the potential to bleed, harden, or form clots. It is an uncommon occurrence within the spinal cord. The external characteristics are similar to those of a mulberry. Capillary telangiectasias may be observed adjacent to lesions, potentially indicating a precursor condition. Demonstrate positivity for the angiogenesis marker (von Willebrand's factor). Lesions can develop from the beginning and may increase in size, decrease, or stay the same as time progresses. Cerebral cavernous

malformations (CM) account for 5-13% of central nervous system vascular anomalies⁽¹⁾.

Cavernous malformation may be sporadic (single lesion) discovered during evaluations for headache or other unrelated symptoms, hereditary caused by autosomal dominant trait (multiple lesion), approximately 40% of these patients remain asymptomatic⁽²⁾. or following radiotherapy sessions, which appears to be a risk factor (following craniocervical radiotherapy for medulloblastoma)⁽³⁾. Regarding the locations of the lesion, most are supratentorial followed by brainstem and multiple respectively⁽⁴⁾.

Patients of cavernous malformation presented with seizures⁽⁵⁾, haemorrhage in 25%.⁽⁶⁾ Usually intraparenchymal, occurs in extra- or intralésional haemorrhage. Because cavernous malformations are low-flow, low-pressure lesions, haemorrhage typically displaces and compresses adjacent neural tissue rather than

destroying it. a compromised blood-brain barrier at the site of a CM that leads to a chronic erythrocyte leak into the surrounding brain and consequently to deposition of hemosiderin in perilesional tissue.⁽⁷⁾ Increases in size may result from repeated small haemorrhages within the lesion and from spontaneous thrombosis of the blood-filled caverns. the clinical presentation caused by the haemorrhage is related to location of the cavernous malformation. Each haemorrhage carries about 20% risk of morbidity, and 5% mortality.⁽⁸⁾ Neurological focal deficits are the most frequent among patients with cavernous malformations in the brainstem and basal ganglia and Hydrocephalus.⁽⁹⁾

Reviewing other literature review, risk factors of haemorrhage in cerebral cavernous malformation were younger age, female sex, multiple and increased lesion size, brainstem cavernous malformation and haemorrhage outside the boundaries of the CM increase rebleeding rate⁽¹⁰⁾. Cavernoma evaluated by imaging tools, MRI is the diagnostic test of choice, with either gradient-echo T2WI or susceptibility-weighted (SWI) images is the most sensitive (popcorn appearance). Gadolinium-contrasted MRI may be helpful for identifying possible associated DVAs or capillary telangiectasia or to exclude tumours in questionable cases. Contrast CT may be helpful when MRI cannot be done. CT scan can rule out emergent conditions such as significant hematoma, hydrocephalus, and mass effect. Angiography: may be needed to rule out other diagnoses⁽¹¹⁾.

Treatment protocols are surgical excision and stereotactic radiosurgery (Gamma knife) is a non-invasive, dedicated system for intracranial radiosurgery described as surgery without the scalpel⁽¹²⁾. radiosurgery is sufficiently safe to serve at least as an alternative for a watch-and-wait policy. Histologic studies of surgically resected irradiated cavernous malformations showed radiation-induced vasculopathy, fibrinoid necrosis, endothelial destruction, hyalinization, marked fibrosis and scar tissue formation. The main indication for gamma knife radiosurgery is reduction of the risk of future haemorrhage and consequential neurological deterioration⁽¹³⁾.

The effect of gamma knife radiosurgery on cavernous malformation was reported as a reduction of the risk of haemorrhage in the majority of gamma knife radiosurgery studies comparing pre- and post-treatment beyond a latency of 2 to 3 years. The annual rebleeding rate falls from 39.5% before treatment to 15% within the first 2 years after radiosurgery and to

2.4% thereafter⁽¹³⁾. Regarding seizure, 53% of the patients suffering from long-lasting epilepsy refractory to medical therapy became seizure-free within a mean of 4 months after gamma knife radiosurgery, especially if applied early after seizure onset⁽¹⁴⁾. In addition to the radiological morphology of cavernous malformation after gamma knife radiology, approximately half of the lesions that shrank may in part be due to the resolution of intralesional haematomas⁽¹⁵⁾.

Vascular abnormalities called cavernous malformations can cause major neurological morbidity including hemorrhage and epilepsy. Although successful, surgical resections carry risks particularly for deep or eloquently located lesions. With increasing proof of efficacy in lowering lesion size and controlling symptoms, gamma knife radiosurgery (GKRS) presents a non-invasive substitute. Data on long-term clinical and radiological outcomes, especially in the regional context of Iraq, still are not enough. By this study we aim to choose best management method to reduce clinical and radiological outcome of intracranial cavernous malformation.

PATIENTS AND METHODS:

A retrospective and prospective comparative study was conducted over a period of 2 years from November 2021 to December 2023 at Dr. Saad Al-Witry Neuroscience Hospital in Baghdad, Iraq. The study included (40) patients. All were followed up during their hospital stay and after discharge at periods ranging from 3 weeks to 24 months. Patient data, clinical presentation, radiological studies including brain CT scan Brain MRI, MRA, MRV, gradient echo sequence, SWI sequence to confirm the diagnosis of cavernous malformation. the patient prepared for gamma knife radiosurgery by sending the patient routine blood investigations, brain MRI gamma protocol and brain CT gamma protocol (T1, T2, SWI and T1 contrast) and entered for Leksell stereotactic gamma knife radiosurgery. All patients were followed up clinically by regular clinic visits to evaluate seizure frequency neurological deficits and quality of life, regular radiological follow up were done by brain MRI gamma protocol to assess cavernomas volume, the first follow up MRI obtained after 6 months then after one year then one and half year then after two years, the volume of the cavernous malformation pre and post gamma knife were assessed by radiologist.

The description and analysis of the data were carried out using the available statistical package SPSS-29 (Statistical Packages for Social Sciences, version 29). Descriptive data was presented in measures of frequency, percentage,

Clinical and Radiologic outcome After Gamma Knife

mean, and standard deviation. Analytical statistics using the McNemar test were carried out to evaluate the association between Neurological signs and symptoms (haemorrhage) (neurological symptoms) and performing gamma knife radiosurgery effect; a P-value ≤ 0.05 was considered statistically significant.

Official research approval of this study was accorded from Scientific Council of Neurosurgery of the Iraqi Board for medical specializations. Official approval (IRB approval) was granted from Al-Rusafa health directorates as well as from the above hospital. The objectives of the study were explained to the participants and informed them that they were allowed to choose to participate or not, and

verbal consent was obtained from each participant and his/her relatives. The collected data were kept confidential in locked computer and will not to be used except for the scientific purpose of this study.

RESULTS:

The study done on 40 patients with cavernomas, the most prevalent age group was (30-39) in (45%) of patients, the mean age was $(39.5 \pm 5$ SD) years; (60%) of patients were males.

According to cavernous malformations central location, (40%) were cortical, (32.5%) were brainstem location, (17.5) were basal ganglia and thalamus, (7.5%) were cerebellar in location and (2.5%) was multiple location, as shown in Figure-1.

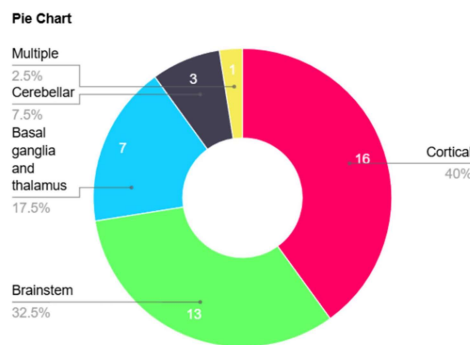


Figure 1: Cavernous malformation distribution according to the location.

According to MRI measurements before Gamma Knife Radiosurgery, 32.5% of patients had a reduction in cavernoma size following treatment. The most common size category pre-treatment was 2-2.9 cm³ in 42.5% of patients, followed by

1-1.9 cm³ in 27.5%. After treatment, the most common size was 1-1.9 cm³ (35%), followed by 2-2.9 cm³ (32.5%). Additionally, 5% of cavernomas disappeared completely (Figure 2).

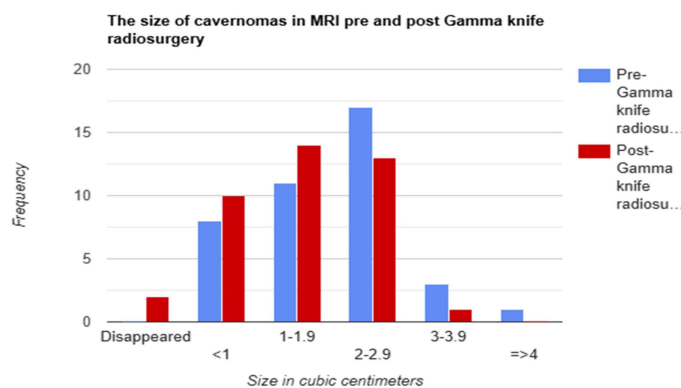


Figure 2: Size of cavernomas in MRI pre and post Gamma knife radiosurgery.

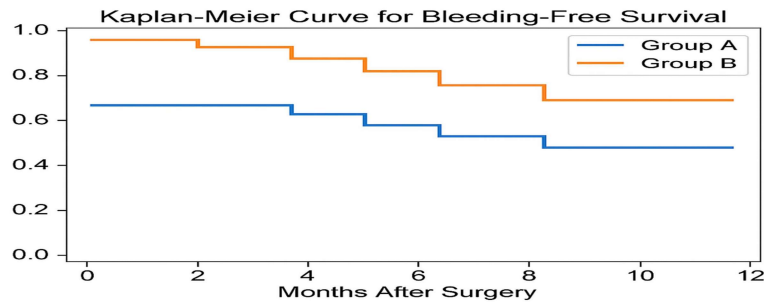
According to patients' Signs & Symptoms, there is a significant association between performing gamma knife radiosurgery and haemorrhage rate reduction as well as seizure, hemiparesis, hemisensory loss and cranial nerves deficits by McNemar testing, as illustrated in (Table-1).

Table 1: Symptoms of patients' pre and post gamma knife.

Signs & Symptoms	No. of patients Pre-gamma knife	No. of patients Post-gamma knife	McNemar test X ² value	P-value
Haemorrhage				
Yes	12	4	12	0.0005*
No	28	36		
Headache				
Yes	31	8	0.015	0.899
No	9	32		
Seizure				
Yes	21	4	3.947	0.04*
No	19	36		
Hemiparesis				
Yes	8	4	17.818	0.00002*
No	32	36		
Hemisensory loss				
Yes	10	3	15.51	0.00008*
No	30	37		
Cranial nerve deficit				
Yes	10	6	13.09	0.0002*
No	30	34		

The Kaplan-Meier survival analysis demonstrated a higher probability of bleeding-free survival in Group B (after GKRS) compared to Group A (before GKRS). The survival curves diverged significantly over the follow-up period.

According to the log-rank test ($\chi^2 = 6.33, p = 0.012$), the difference between the two groups was statistically significant, indicating that patients in Group B had a significantly better outcome in terms of postoperative bleeding.



The log-rank test ($\chi^2 = 6.33, p = 0.012$) demonstrated a statistically significant difference between the two groups.

Figure 3: Kaplan-Meier survival analysis for hemorrhage recurrence.

A comparison of neurological signs and symptoms in patients with cavernous malformations before and after undergoing Gamma Knife Radiosurgery, categorized by lesion location. The results showed a reduction in most symptoms post-GKRS. Hemorrhage and headache were most common in cortical lesions significantly decreased after GKRS. Seizure,

exclusively correlates with cortical and multiple lesions, dropped in post-treatment period. Hemiparesis and hemisensory loss were observed in both cortical and brainstem lesions and showed mild improvement post-treatment. Cranial nerve deficits, mainly associated with brainstem cavernomas and diminished after GKRS.

Table 2: Outcomes by lesion localization pre- and post-GKRS

Signs & Symptoms	No. of patients Pre-gamma knife	No. of patients Post-gamma knife
Haemorrhage		
Cortical	9	2
Brainstem	-	-
Basal ganglia and thalamus	2	1
Cerebellar	1	1
Multiple	-	-
Headache		
Cortical	29	7
Brainstem	-	-
Basal ganglia and thalamus	-	-
Cerebellar	2	1
Multiple	-	-
Seizure		
Cortical	20	4
Brainstem	-	-
Basal ganglia and thalamus	-	-
Cerebellar	-	-
Multiple	1	-
Hemiparesis		
Cortical	4	2
Brainstem	4	2
Basal ganglia and thalamus	-	-
Cerebellar	-	-
Multiple	-	-
Hemisensory loss		
Cortical	4	-
Brainstem	4	3
Basal ganglia and thalamus	2	-
Cerebellar	-	-
Multiple	-	-
Cranial nerve deficit		
Cortical	-	-
Brainstem	9	6
Basal ganglia and thalamus	-	-
Cerebellar	1	-
Multiple	-	-

DISCUSSION:

Regarding to age groups most cases were in age group 30-39 years old and the mean age was (39.5 ± 5 SD), was similar to Omer Sager study which had mean age group of 35 years old⁽¹⁶⁾. In our study male are the most common which is 60% of the patients which is similar to Jae Jon Sheen study in which the male was the most common 55%⁽¹⁷⁾.

According to the size of cavernous malformation in our study the volume of cavernous malformation decreased in 32.5% of patients post gamma knife radiosurgery, this result was similar to study conducted by Chiung-Chyi Shen, et al., they found that the size of cavernous malformation were decreased in (21.3%) of cases following gamma knife radiosurgery⁽¹⁸⁾.

In relation to haemorrhage, pre and post Gamma knife in our study (30%) of the patients had at least one attack of haemorrhage and only (10%) experience haemorrhage post gamma knife which is similar to Cheng-Chia Lee et al study in which (23.6%) of the patients had haemorrhage pregamma knife and only (7.52%) had haemorrhage post gamma knife⁽¹⁹⁾. In other study done by Sung Ho Lee et al which were similar to our study in which 22.2% of the patients experienced haemorrhage pregamma knife and 9.8 of the patients experienced haemorrhage post gamma knife⁽²⁰⁾.

In our study results of seizure control, post gamma knife radiosurgery (80.9%) of the patients had seizure control. Similar to a study by

Cheng-Chia Lee et al. which concluded that (82%) had seizure control post gamma knife⁽²¹⁾. Regarding cranial nerves deficits In our study we concluded that cranial nerve deficits were (25%) pre gamma knife and only (15%) post gamma knife while in study done by Ahmed Ragab AbdelSalam (75%) of the patients had cranial nerve deficit improved or stable post-Gamma knife, but in his study all the selected patients had brainstem cavernoma with cranial nerve deficit⁽²²⁾.

In relation to hemiparesis and hemisensory loss, there is an improvement in 50% and 30% of patients experienced those symptoms respectively. Unfortunately, we couldn't find any other studies that discussed these topics.

By survival analysis demonstrated a higher probability of bleeding-free survival in Group B (after GKRS) compared to Group A (before GKRS). The difference between the two groups was statistically significant, indicating that patients in Group B had a significantly better outcome in terms of postoperative bleeding, this was similar to result found by study conducted in Türkiye⁽²³⁾.

Gamma Knife Radiosurgery is cost-effective compared to microsurgery or conservative management, this conclusion agrees with 2 researches papers conducted in Türkiye and United States respectively^(23,24).

CONCLUSION:

Gamma knife radiosurgery is a valid alternative option to microsurgical resection with less mortality and morbidity and less hospital stay. Nearly one third of patients experienced decreasing in the size of cavernous malformation after gamma knife radiosurgery. There is a significant association between performing gamma knife radiosurgery and haemorrhage rate reduction as well as seizure, hemiparesis, hemisensory loss and cranial nerves deficits. Gamma knife radiosurgery significantly reduces the haemorrhage free survival period. Finally, the data suggest that GKRS is associated with a reduction in symptom across various lesion locations, especially in cortical lesions.

Recommendations:

To continue clinical and radiological follow up of more than 3 years. We advise to treat patients with cavernous malformation located in eloquent cortices and inaccessible deep seated cavernomas with gamma knife radiosurgery as a primary treatment option with no or very low risk of radiation induced neurotoxicity.

ACKNOWLEDGMENTS:

I would like to express my deepest thanks and respect to my supervisor prof. Yasir Mohammed

Hamandi for his Kind help supervision and guidance to accomplish this study.

I would like to express thanks and respect to seniors and my colleagues at Dr. Saad Alwitry neuroscience Hospital.

Financial support:

Nil.

Conflict of Interest:

In conducting this study, we hereby declare that there are no conflicts of interest.

Disclosure:

The material has never been published and is not currently under evaluation in any other peer review publication.

REFERENCES:

1. Gastelum E, Sear K, Hills N, et al. Rates and characteristics of radiographically detected intracerebral cavernous malformations after cranial radiation therapy in pediatric cancer patients. *J Child Neurol*. 2015; 30:842–49.
2. Moore SA, Brown RD, Christianson TJ, et al. Longterm natural history of incidentally discovered cavernous malformations in a single-center cohort. *J Neurosurg*. 2014;120:1188–92
3. Akers A, Al-Shahi SR, et al. Synopsis of Guidelines for the Clinical Management of Cerebral Cavernous Malformations: Consensus Recommendations Based on Systematic Literature Review by the Angioma Alliance Scientific Advisory Board Clinical Experts Panel. *Neurosurgery*. 2017; 80:665–80
4. Al-Shahi SR, Berg MJ, Morrison L, et al. Hemorrhage from cavernous malformations of the brain: definition and reporting standards. Angioma Alliance Scientific Advisory Board. *Stroke*. 2008; 39:3222–30.
5. Cordonnier C, Al-Shahi SR, Bhattacharya JJ, et al. Differences between intracranial vascular malformation types in the characteristics of their presenting haemorrhages: prospective, populationbased study. *J Neurol Neurosurg Psychiatry*. 2008;79:47–51.
6. Nikoubashman O, Di Rocco F, Davagnanam I, et al. Prospective Hemorrhage Rates of Cerebral Cavernous Malformations in Children and Adolescents Based on MRI Appearance. *AJNR Am J Neuroradiology*. 2015; 36:2177–83.
7. Witiw CD, Abou-Hamden A, Kulkarni AV, et al. Cerebral cavernous malformations and pregnancy: hemorrhage risk and influence on obstetrical management. *Neurosurgery*. 2012; 71:626–30; discussion 631.

8. Flemming KD, Link MJ, Christianson TJ, et al. Prospective hemorrhage risk of intracerebral cavernous malformations. **Neurology**. 2012;78:632–36.
9. Horne MA, Flemming KD, Su IC, et al. Clinical course of untreated cerebral cavernous malformations: a meta-analysis of individual patient data. **Lancet Neurol**. 2016; 15:166–73.
10. Choquet H, Nelson J, Pawlikowska L, et al. Association of cardiovascular risk factors with disease severity in cerebral cavernous malformation type 1 subjects with the common Hispanic mutation. **Cerebrovasc Dis**. 2014;37:57–63.
11. Nagy G, Kemeny AA. Stereotactic radiosurgery of intracranial cavernous malformations. **Neurosurg Clin N Am**. 2013;24:575-89.
12. Hamandi YM. The Role of Stereotactic Gamma Knife Radiosurgery in the Treatment of Brain Lesions 2020; 19(Issue 2).
13. Frischer JM, Gatterbauer B, Holzer S, et al. Microsurgery and radiosurgery for brainstem cavernomas: effective and complementary treatment options. **World Neurosurg**. 2014;81:520-28.
14. Wang P, Zhang F, Zhang H, et al. Gamma knife radiosurgery for intracranial cavernous malformations. **Clin Neurol Neurosurg**. 2010;112:474-77.
15. Liscak R, Urgosik D, Simonova G, et al. Gamma knife radiosurgery of brain cavernomas. **Acta Neurochir Suppl**. 2013;116:107-11.
16. Omer S, Murat B, Ferrat D, et al. Evaluation of linear accelerator (LINAC)-based stereotactic radiosurgery (SRS) for cerebral cavernous malformations: a 15-year single-center experience. **Ann Saudi Med**. 2014; 34(1): 54–58.
17. Jon S, Do HL, Deok HL, Yunsun S, and et al. Long-Term Outcome of Gamma Knife Radiosurgery for Brain Cavernoma: Factors Associated with Subsequent De Novo Cavernoma Formation. **World Neurosurgery** Volume 120, December 2018:e17-e23.
18. Chiung-Chyi S, Ming H, Meng-Yin Y, and et al. Outcome of intracerebral cavernoma treated by Gamma Knife radiosurgery based on a double-blind assessment of treatment indication. **Radiation Oncology** 2021;16:164.
19. Cheng-Chia L, Wei-Hsin W, Huai-Che Y, and et al. Gamma Knife radiosurgery for cerebral cavernous malformation. **Scientific Reports** 2019; 9:19743 .
20. Sung HO L, Hyuk JC, Hee SS, and et al. Gamma knife radiosurgery for brainstem cavernous malformations: should a patient wait for the rebleed?. **Acta Neurochirurgica**, 2014;156:1937-46.
21. Cheng-Chia L, Wei-Hsin W, Huai-Che Y, and et al. Gamma Knife radiosurgery for cerebral cavernous malformation. **Scientific Reports** 2019; 9:19743 .
22. AbdelSalam AR, Elshazly AA, Tobar AF and et al. GAMMA KNIFE RADIOSURGERY ROLE IN THE MANAGEMENT OF BRAIN STEM CAVERNOUS ANGIOMAS. **Ain alshams medical journal** 2020; 71(Issue 3) :501-11.
23. Civlan S, Berker BB, Kiraz İ, et al. Gamma knife radiosurgery for cavernous malformations: a comprehensive study on symptom relief, hemorrhage rates, and histopathological changes. **Neurosurg Rev**. 2025;48(1):106. doi:10.1007/s10143-025-03257-y.
24. Kano H, Kondziolka D, Flickinger JC, Lunsford LD. A cost comparative study of Gamma Knife radiosurgery versus open surgery for intracranial pathologies. **J Clin Neurosci**. 2015;22(1):94-98. doi:10.1016/j.jocn.2014.05.003.