



Al-Qadisiyah Journal of Pure Science

Al-Qadisiyah Journal of Pure Science

ISSN(Printed): 1997-2490 ISSN(Online): 2411-3514

DOI: 10.29350/jops



## Studying the Effect of the Aqueous Extract of Blackberry Fruits on Liver Tissue in Male Rabbits with Induced Hypothyroidism

Zahra Ali Habib

Btool A. Hussein

College of Education for Pure Sciences / Department of Life Sciences

### Abstract

This experiment was designed to determine the effect of the aqueous extract of blackberry fruits on the liver tissue of male rabbits with therapeutically induced hypothyroidism. Twenty adult male rabbits were randomly distributed into four equal groups. The first group was treated with water and normal food and was considered a negative control group (G1). The second group was treated with carbimazole (G2).

The third group was treated with carbimazole and aqueous extract of blackberry fruits (G3). The fourth group was treated with aqueous extract of blackberry fruits (G4).

The results showed a significant decrease at the probability level ( $p < 0.01$ ) in the second group (G2) treated with carbimazole in the concentration of HDL and a significant increase at the probability level ( $p < 0.01$ ) in the concentration of (TC, TG, LDL, VLDL) respectively with an increase in the concentration of the lipase enzyme.

The results of the histological study showed the occurrence of central vein congestion, sinusoidal dilation, inflammatory infiltration and cellular degeneration in group (G2) that received carbimazole (0.02 mg/kg body weight) compared to the control group (G1) that received water and normal food.

As for group (G3) treated with carbimazole (0.02 mg/kg body weight) and blackberry aqueous extract (200 mg/kg body weight), it showed mild central vein congestion and sinusoidal dilation compared to group (G4) treated only with blackberry aqueous extract (200 mg/kg body weight), in which the liver tissue appeared closer to its normal state with a clear central vein and mild sinusoidal dilation.

Keywords: Hypothyroidism, aqueous extract, *Rubus plicatus*, male rabbits

## Introduction

The thyroid gland is one of the large endocrine glands in the body, weighing approximately (15-25g) and has a reddish-brown color, shaped like a butterfly. It consists of two lobes located in front of the larynx, below the neck, on both sides of the trachea, and they are connected to each other by the isthmus [1].

Each lobe is composed of smaller lobules (follicles), the number of which ranges between 20-40 Follicles. Each follicle is a cystic structure lined with a layer of cuboidal epithelial cells, containing in its cavity a colloidal substance called colloid.

The main component of the colloid is a glycoprotein called thyroglobulin (TG), which acts as a precursor of thyroid hormone and stores iodine [2].

Hypothyroidism occurs due to insufficient secretion of thyroid hormones. In most cases, this can result from genetic defects in the thyroid gland, surgical removal of the thyroid gland, removal of the thyroid gland using iodine 131, autoimmune destruction of the thyroid gland, or the use of certain medical drugs such as carbimazole [3].

Thyroid hormones participate in various physiological processes in the body; one of the most important is neuromodulation. Hypothyroidism can affect the nervous system and play a role in the development of Alzheimer's disease [4].

Hypothyroidism also leads to a decrease in the vital energy of the heart muscle and stiffening of blood vessels [5].

In addition, thyroid hormones play a major role in maintaining the basal metabolic rate (BMR). Therefore, a decrease in the availability of thyroid hormones (hypothyroidism) reduces the basal metabolic rate and is associated with a state of hypometabolism, weight gain, increased levels of cholesterol, decreased lipolysis, and glucose formation.

The liver has an important role in thyroid hormone metabolism, as it makes proteins that bind to it. With thyroid hormone and albumin, it is also the main site of metabolism of thyroxine-binding globulin, and participates in its conjugation to bile secretion, oxidized deamination, and deiodination from thyroxine T4 to triiodothyronine T3 [6].

Medicinal plants are among the important and main sources for extracting medicinal treatments and medicinal drugs [7] by using extracts of different parts of them, whether roots, stems, leaves, or fruits, instead of industrial compounds that produce harm. This is what is known as phytopharmacology, herbology, or treatment with plants [8].

Black fruits, especially blackberries, are highly appreciated by researchers because of their nutritional properties, which have been reported to have many health benefits because they contain many active compounds in high proportions, as they contain forty-seven phenolic compounds, including phenolic acids, flavonoids, and anthocyanins [9].



## **The aims of study**

Is knowing the effect of the aqueous extract of *Rubus plicatus* on the liver tissue in rabbits with therapeutically induced hypothyroidism. Hypothyroidism

## **Material and Method**

In this study, 20 adult male rabbits were purchased from the local markets. Their average weight ranged between (1500-2000) grams. They were placed in cages prepared for this purpose in the animal house of the College of Pharmacy/University of Karbala. Unlimited water and food were provided and they were left for two weeks before the experiment to ensure that they were clear of diseases.

## **Induction of Hypothyroidism**

Carbimazole was used at a dose of (0.02 mg/kg of body weight) to induce hypothyroidism [10]. After two weeks of dosing, blood samples were drawn to confirm the occurrence of hypothyroidism. The results showed a decrease in TSH, which indicates the occurrence of hypothyroidism and an increase in T3 and T4.

## **Design of Experiment**

20 adult male rabbits were randomly divided into 4 groups After inducing hypothyroidism as follows:

- 1- The first group G1 Which consists of five rabbits was given water and regular food for six weeks.
- 2- The second group G2 Which consists of five rabbits was dosed with carbimazole at a dose of (0.02 mg/kg of body weight) for six weeks .
- 3- The third group G3 Which consists of five rabbits was dosed with aqueous extract of blackberries at a concentration of (200 mg/kg of body weight) 4 hours after dosing them with carbimazole at a concentration of (0.02 mg/kg of body weight) for six weeks.

4- The fourth group G4 Which consists of five rabbits was dosed with aqueous extract of blackberries at a concentration of (200 mg/kg of body weight) for six weeks [11].

Blood was drawn from the above groups directly from the heart after six weeks and after fasting the animals overnight before blood collection starts. The blood was then placed in tubes without an anticoagulant, after that the blood was separated by centrifugation at 3000 (RPM) for 15 minutes. The sera were stored in the refrigerator at 4°C to measure the following parameters:

1- Total cholesterol (TC)

2- Triglyceride (TG)

3- HDL

4- LDL

5- VLDL

6- Lipase enzyme

The kits for lipids were used based on the enzymatic method using the Mindray device manufactured by Unimedica, and the measurement steps for each enzyme were carried out based on the steps accompanying each kit.

As for the preparation of histological sections taken from the liver, it was done according to the method described by (Suvarna et al. in 2018) [12].

## **Microphotography**

Tissue sections were photographed using an Olympus light microscope equipped with a Digital Camera manufactured by Olympus in Japan.

## **Statistical Analysis**

The statistical analysis of the study was conducted using the statistical program SAS (2012) [13] to study the effect of groups on the studied criteria using one-way analysis of variance, and the differences between the averages were compared using the least significant difference (LSD) test.

## Result

It is noted from Table (1) that there is a significant increase below the probability level ( $p < 0.01$ ) in the rate of total cholesterol concentration (TC) in the second group treated with carbimazole (G2) compared to the control group (G1). It was also noted that there is a significant decrease at the probability level ( $p < 0.01$ ) in the rate of cholesterol concentration in the third group treated with carbimazole and the aqueous extract of blackberry fruits (G3) and the fourth group treated only with the aqueous extract of blackberry fruits (G4) compared to the control group (G1).

While the results of the same table also indicated a significant increase at the probability level ( $p < 0.01$ ) in the rate of triglyceride concentration (TG) in the second group treated with carbimazole (G2) compared to the control group (G1), a significant decrease was also observed at the probability level ( $p < 0.01$ ) in the rate of triglyceride concentration in the third group treated with carbimazole and the aqueous extract of blackberry fruits (G3), unlike the fourth group treated with the aqueous extract of blackberry fruits, in which no significant change was observed compared to the control group (G1).

The results of the table also indicated a significant decrease at the probability level ( $p < 0.01$ ) in the HDL concentration rate in the second group treated with carbimazole (G2) compared to the control group (G1). A significant increase was also observed at the probability level ( $p < 0.01$ ) in the triglyceride concentration rate in the third group treated with carbimazole and the aqueous extract of blackberry fruits (G3) and the fourth group treated with the aqueous extract of blackberry fruits (G4) compared to the control group (G1).

The results in the same table also showed a significant increase at the probability level ( $p < 0.01$ ) in the LDL concentration rate in the second group treated with carbimazole (G2) compared to the control group (G1). As for the third group (G3), the LDL level decreased significantly ( $p < 0.01$ ) compared to the second group (G2), but its level was significantly higher ( $p < 0.01$ ) compared to the control group (G1). As for the fourth group (G4), the LDL level approached its level in the control group (G1), but it decreased significantly ( $p < 0.01$ ) compared to the second group (G2).

As noted in the table results, the VLDL level increased significantly at the probability level ( $p < 0.01$ ) in the second group (G2) treated with carbimazole compared to the control group (G1), while the third group (G3) treated with carbimazole and aqueous extract of blackberry fruit witnessed a significant decrease ( $p < 0.01$ ) compared to the control group (G1) and the second group (G2), while the fourth group (G4) did not record a significant difference ( $p < 0.01$ ) compared to the control group (G1).

The results of Table (4-1) also showed a significant increase at the probability level ( $p < 0.01$ ) in the concentration rate of the Lipase enzyme in the second group treated with carbimazole

(G2) compared to the control group (G1). As for the third group (G3) treated with carbimazole and the aqueous extract of blackberry fruits, the level of Lipase decreased significantly ( $p<0.01$ ) compared to the second group (G2), but its level was significantly higher ( $p<0.01$ ) compared to the control group (G1), while the fourth group (G4) treated only with the aqueous extract of blackberry fruits did not record a significant difference ( $p<0.01$ ) compared to the control group (G1).

Table (1) shows the effect of the drug carbimazole and the aqueous extract of the blackberry fruit on the lipid profile in the serum of male rabbits induced by therapeutic hypothyroidism.

LIPASE (V/L)	VLDL (mmol /l)	LDL (mmol /l)	HDL (mmol /l)	TG (mmol /l)	TC (mmol /l)	<u>Variables</u> Groups
109.80±0.58 A	16.80±0.17 A	41.22±1.34 A	22.96±0.46 AC	84.00±0.84 A	83.64±0.66 A	G1
145.96±0.57 B	23.34±1.92 B	68.54±2.70 B	14.40±0.24 B	116.72±9.59 B	108.00±1.64 B	G2
125.68±2.20 C	11.71±0.88 C	46.10±1.37 C	24.92±0.47 AD	58.56±4.40 C	65.78±0.93 C	G3
111.00±0.84 A	17.82±1.01 A	40.56±1.05 CA	26.60±1.12 D	89.10±5.05 A	66.64±0.34 C	G4
5.83	2.79	4.81	2.25	13.94	12.67	LSD

n=5, Mean ± standard error

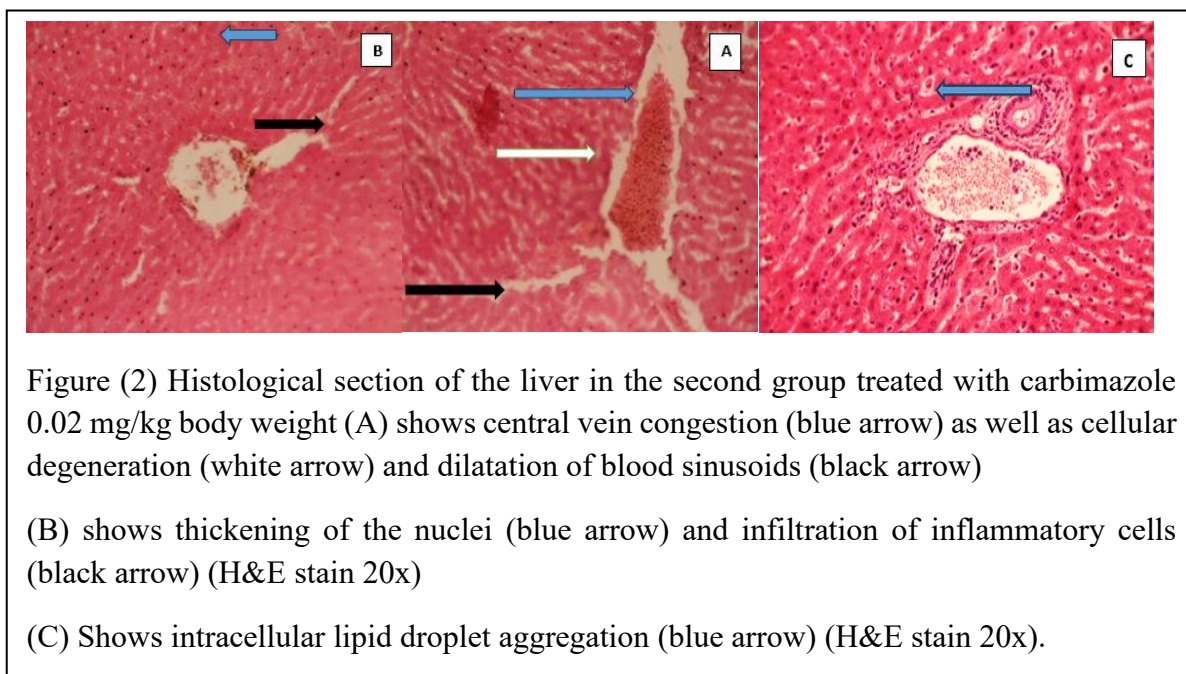
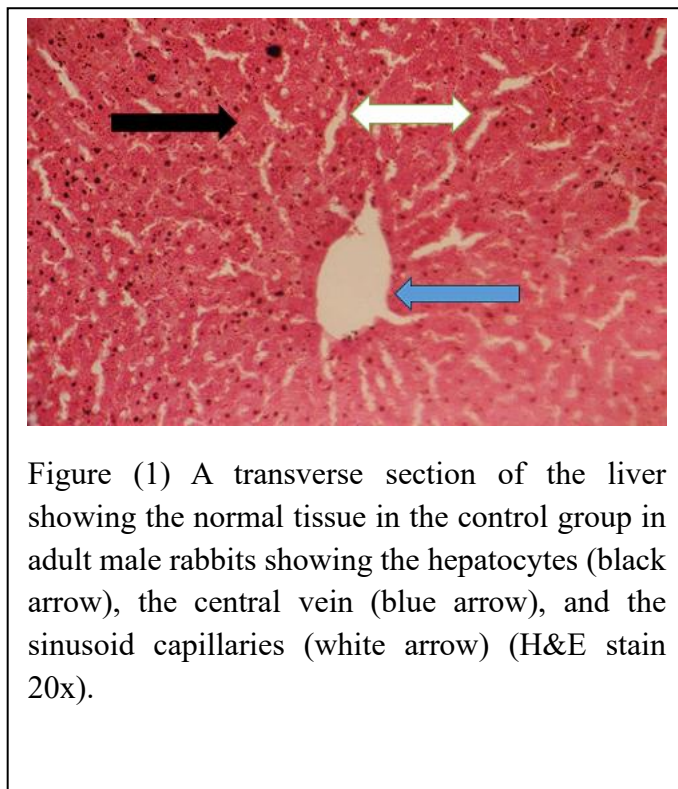
Different capital letters indicate significant differences ( $p<0.01$ ).

## Histological changes

The results of our study showed the occurrence of pathological tissue changes in the liver tissue represented by the occurrence of congestion of the central vein with cellular degeneration in addition to expansion of the blood sinusoids and thickening of the cell nuclei and the occurrence of infiltration of inflammatory cells in the group treated with carbimazole at a concentration of (0.02 mg/kg of body weight), Figure (2), compared with the healthy control group, Figure (1).

Figure (3) represents the tissue changes in the liver of the group treated with the drug at a concentration of 0.02 mg/kg and the aqueous extract at a concentration of (200 mg/kg of body weight), where slight changes appear represented by slight expansion of the blood sinusoids and clarity of the central vein. As for Figure (4), the tissue changes in the liver in the group

treated with the aqueous extract of blackberry fruits (200 mg/kg of body weight) were slight and the tissue was closer to its normal state.





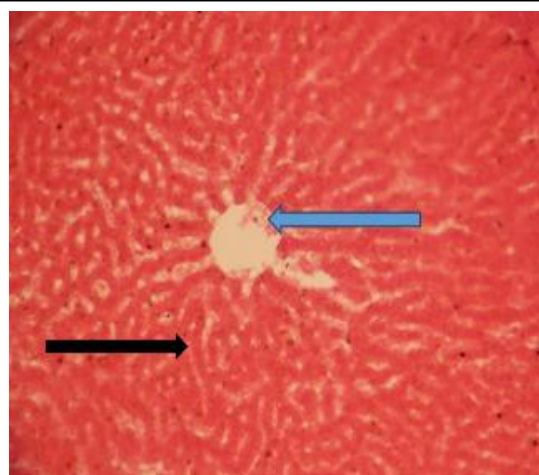


Figure (3) Histological section of the liver of the third group treated with carbimazole (0.02 mg/kg of body weight) and aqueous extract of blackberry fruits (200 mg/kg of body weight), showing mild congestion of the central vein (blue arrow) and dilatation of the sinuses (black arrow) (H&E stain 20x)

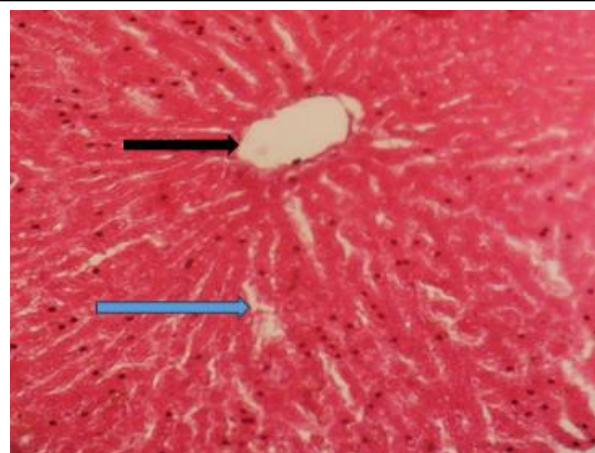


Figure (4) Histological section of the liver in the fourth group treated with the aqueous extract of blackberry fruits (200 mg/kg of body weight), showing the central vein (black arrow) and slight dilatation of the blood sinusoids (blue arrow) (H&E stain 20 x)

## Discussion

Hypothyroidism is a term that means a decrease in the concentration of the thyroid hormones T4 and T3 and an increase in the secretion of thyroid stimulating hormone (TSH). Increased secretion of TSH leads to an enlargement of the thyroid gland, causing the thyroid gland to lose its function and tissues. This is called primary hypothyroidism. Secondary hypothyroidism may result from insufficient stimulation of the thyroid gland from the hypothalamus. (Low TRH concentration) Thyroid releasing hormone or due to a defect in the secretion of TSH from the pituitary gland [14].

The results of the current study in the second group (G2) treated with carbimazole only showed a significant increase in the levels of (TC, TG, LDL, and VLDL) accompanied by a decrease in the level of HDL compared to the control group (G1).

It has been proven that thyroid hormones regulate the basal metabolic rate of all cells, including liver cells. Therefore, thyroid dysfunction may lead to liver dysfunction, as many studies have indicated that hypothyroidism leads to an increase in the levels of triglycerides (TG), cholesterol (TC), and fatty acids in liver tissue [15].

The results of our current study showed the presence of histological changes in the liver tissues represented by fatty degeneration and the occurrence of infiltration of inflammatory cells around the central vein in the liver and expansion of the blood sinusoids. This is consistent with the results of the study of Premakumari *et al.*, [16] : Demir *et al.*, [17 ]

Our results also agreed with the results of Hamza & Hadi [18] which indicated that giving carbimazole (5 mg/kg of body weight) leads to clear death of hepatic cells, hyperplasia of the bile duct, congestion in the central vein and infiltration of inflammatory cells.

Lipase is secreted in the pancreas and is used as a catalyst to help break down triglycerides in the stomach, and this breakdown is completed by intestinal lipase in the small intestine [19].

Our current study indicated an increase in the level of lipase enzyme in the blood serum in conjunction with hypothyroidism, accompanied by an increase in the level of fats. The reason for this is that the thyroid gland does not produce enough T3 and T4 hormones to stimulate the lipase enzyme to break down fats.

The pancreas, in turn, works to produce the lipase enzyme naturally and continuously, thus increasing its concentration in the blood with the process of burning fats slowly, which leads to an increase in the level of fats in the blood. [20].

Thyroid hormones work primarily to increase the activity of the enzyme (LPL) lipoprotein lipase, which leads to the breakdown of triglycerides, including VLDL. In the case of hypothyroidism, the levels of total cholesterol, LDL and triglycerides in the blood will increase.

Because thyroid hormones (TH) influence cholesterol production, clearance, and conversion, recent studies suggest that thyroid-stimulating hormone (TSH) is also involved in lipid metabolism independently of TH.

Therefore, the mechanism of dyslipidemia in hypothyroidism is related to decreased TH and increased TSH levels [21].

While these changes were not observed in the group given the aqueous extract at a concentration of (200 mg/kg of body weight), the reason for this is that the blackberry plant *Rubus plicatus*, which belongs to the Rosaceae family, is rich in biologically active phytochemical components, especially anthocyanins, which have various health effects [22]

because they have antioxidant, anti-aging, anti-inflammatory, anti-diabetic and anti-cancer properties, and can also alleviate or prevent non-alcoholic fatty liver disease and liver damage [23,24], as raspberry extracts can improve non-alcoholic fatty liver disease and relieve liver fat by increasing enzymes involved in beta-oxidation and decreasing de novo lipogenesis (DNL) [25].

The stress that the animal was exposed to as a result of continuous daily doses of carbimazole for six weeks led to the generation of free radicals, especially reactive oxygen species (ROS), which are considered tissue destroyers through the appearance of degenerative changes in cells and other tissue changes, bleeding, blood congestion, infiltration of inflammatory cells, and the appearance of fatty vacuoles, all of which are tissue changes caused by free radicals [26].

## References

- 1-Khan, Y. S., & Farhana, A. (2019). Histology, thyroid gland.
- 2-Benvenga, S., Tuccari, G., Ieni, A., & Vita, R. (2018). Thyroid gland: anatomy and physiology. *Encyclopedia of Endocrine Diseases*, 4, 382-390.
- 3- Chaker, L., Bianco, A. C., Jonklaas, J., & Peeters, R. P. Hypothyroidism Lancet, 390 (2017). *View PDF View article View in Scopus*, 1550-1562.
- 4- Khaleghzadeh-Ahangar, H., Talebi, A., & Mohseni-Moghaddam, P. (2022). Thyroid disorders and development of cognitive impairment: a review study. *Neuroendocrinology*, 112(9), 835-844.
- 5-von Hafe, M., Neves, J. S., Vale, C., Borges-Canha, M., & Leite-Moreira, A. (2019). The impact of thyroid hormone dysfunction on ischemic heart disease. *Endocrine connections*, 8(5), R76-R90.
- 6- Saha, R. D., & Bhakta, S. (2024). PREVALENCE OF HYPOTHYROIDISM IN CIRRHOTIC PATIENTS AND NORMAL INDIVIDUALS. *Int J Acad Med Pharm*, 6(3), 268-272.
- 7- Nankaya, J., Gichuki, N., Lukhoba, C., & Balslev, H. (2019). Medicinal plants of the Maasai of Kenya: a review. *Plants*, 9(1), 44.
- 8- Roy, A., Jauhari, N., & Bharadvaja, N. (2018). Medicinal plants as a potential source of chemopreventive agents. *Anticancer Plants: Natural Products and Biotechnological Implements: Volume 2*, 109-139.
- 9- Karakljajic-Stajic, Z., Tomic, J., Pesakovic, M., Paunovic, S. M., Stampar, F., Mikulic-Petkovsek, M., ... & Jakopic, J. (2023). Black queens of fruits: Chemical composition of blackberry (*Rubus subg. rubus* Watson) and black currant (*Ribes nigrum* L.) cultivars selected in Serbia. *Foods*, 12(14), 2775.
- 10-Ilyas, A., Ishaque, I., Qamar, N., & Parveen, K. (2015). Effect of experimentally induced hypothyroidism and its treatment by thyroxine on the number of follicles in an ovary of wistar rats. *J Rawalpindi Medical College (JRMCI)*, 19(1), 84-88.

- 11-Amini, N., Shiravi, A., Mirazi, N., Hojati, V., & Abbasalipourkabir, R. (2020). Study of protective effects of raspberry fruit extract (*Rubus fruticosus* L.) on the antioxidant function in male diabetic rats induced with STZ. *Journal of Animal Research (Iranian Journal of Biology)*, 33(2), 105-113.
- 12-Suvarna, K. S., Layton, C., & Bancroft, J. D. (2018). *Bancroft's theory and practice of histological techniques*. Elsevier health sciences.
- 13--Cary, N. (2012). Statistical analysis system, User's guide. Statistical. Version 9. *SAS. Inst. Inc. USA*.
- 14- Lovely, N. S. (2018). Effect of hypothyroidism on the cardiovascular system: A review. *Mainamoti Medical College Journal*, 27(13), 15-19.
- 15- k, J., Zhao, J., Liu, J., Jiang, S., Guo, S., Xu, L., ... & Dong, J. (2023). The relationships between thyroid functions of short-term rapid hypothyroidism and blood lipid levels in post-thyroidectomy patients of differentiated thyroid cancer. *Frontiers in Endocrinology*, 14, 1114344.
- 16-Premakumari, R. N., Baishya, C., Sajid, M., & Naik, M. K. (2024). Modeling the dynamics of a marine system using the fractional order approach to assess its susceptibility to global warming. *Results in Nonlinear Analysis*, 7(1), 89-109.
- 17-Demir, Ş., Ünübol, M., Aypak, S. Ü., İpek, E., Aktaş, S., Ekren, G. S., ... & Güney, E. (2016). Histopathologic evaluation of nonalcoholic fatty liver disease in hypothyroidism-induced rats. *International journal of endocrinology*, 2016(1), 5083746.
- 18- Hadi, M. S., & Hamza, E. A. (2021). Effects of thyroid dysfunction on liver tissue in male rats. *Plant Arch*, 21(1), 1699-1703.
- 19- Patil, M., Patil, R., Bhadane, B., Mohammad, S., & Maheshwari, V. (2017). Pancreatic lipase inhibitory activity of phenolic inhibitor from endophytic *Diaporthe arengae*. *Biocatalysis and agricultural biotechnology*, 10, 234-238
- 20-Premakumari, R. N., Baishya, C., Sajid, M., & Naik, M. K. (2024). Modeling the dynamics of a marine system using the fractional order approach to assess its susceptibility to global warming. *Results in Nonlinear Analysis*, 7(1), 89-109.
- 21- Matshar, E. K., Atyah, B. S., & Abed, E. H. (2024). Clinical and Subclinical Hypothyroidism And Its Effects on Dyslipidemia: As Narrative Review. *J. Appl. Health Sci. Med*, 4(8), 13-16.
- 22- Xiao, T., Guo, Z., Bi, X., & Zhao, Y. (2017). Polyphenolic profile as well as anti-oxidant and anti-diabetes effects of extracts from freeze-dried black raspberries. *Journal of Functional Foods*, 31, 179-187.

- 23-Xu, Y., Hu, D., Bao, T., Xie, J., & Chen, W. (2017). A simple and rapid method for the preparation of pure delphinidin-3-O-sambubioside from Roselle and its antioxidant and hypoglycemic activity. *Journal of functional foods*, 39, 9-17.
- 24- Li, X., Li, Y., States, V. A., Li, S., Zhang, X., & Martin, R. C. (2014). The effect of black raspberry extracts on MnSOD activity in protection against concanavalin A induced liver injury. *Nutrition and cancer*, 66(6), 930-937.
- 25-García Beltrán, A., Lozano Melero, A., Martínez Martínez, R., Porres Foulquie, J. M., López-Jurado Romero De La Cruz, M., & Kapravelou, G. (2024). A Systematic Review of the Beneficial Effects of Berry Extracts on Non-Alcoholic Fatty Liver Disease in Animal Models.
- 26-Ritter, M. J., Amano, I., & Hollenberg, A. N. (2020). Thyroid hormone signaling and the liver. *Hepatology*, 72(2), 742-752.