



Histopathological Changes of Feline Distemper in Persian Kitten: A Case Report

Yahya Abd Almunaf Ahmed¹

Omer Khazaal Alhankawe²

¹Department of Pharmacy Techniques, Mosul Medical Technical Institute, Northern Technical University, Iraq.

²Department of Internal and Preventive Medicine, College of Veterinary Medicine, University of Mosul, Iraq

Submitted: September 28, 2025

Revised: November 13, 2025

Accepted: November 13, 2025

Correspondence

Omer K. Alhankawe

Ahmed2010mks@uomosul.edu.iq

Abstract This case report focuses on a Persian kitten that was presented to the Veterinary Teaching Hospital at Mosul University, at the age of 3.5 months, weighing 0.72 kg, unvaccinated, showing fever, lethargy, and anorexia. The kitten became hypothermic as a result of diarrhea, vomiting, and dehydration. Because of severity of the disease, prognosis remained poor despite urgent intensive care. Two hours after the start of therapy, the kitten died without responding. Fecal sample was collected with a sterile swab and tested for feline distemper virus antigen using a commercial immunochromatographic test. DNA was extracted from feces for PCR diagnosis. Following kitten's death, a necropsy was performed; tissues of ileum, mesenteric lymph nodes, liver, and spleen were collected and fixed in 10% buffered formalin. These tissues were paraffin-embedded, sectioned at 5 μ m, stained with hematoxylin and eosin, and examined by light microscopy. Diagnostic tests confirmed parvovirus infection: the fecal immunochromatographic test was positive, and PCR yielded a 695 bp amplicon. Histopathology revealed characteristic amphophilic intranuclear inclusion bodies marginating chromatin, along with necrosis, inflammatory cell infiltration, and glandular atrophy in the ileum. Similar inclusion bodies, lymphoid depletion, necrosis, and increased fibrosis were present in the mesenteric lymph node and spleen. The liver exhibited inclusion bodies, coagulative hepatocyte necrosis, and inflammation. In conclusion, the histopathological changes confirmed that gastroenteritis was fatal form of feline distemper. This case highlights how the disease is fatal and ongoing threat to unvaccinated kittens.

Keywords: Parvovirus, Cats, PCR, Inclusion bodies, Mosul.

©Authors, 2025, College of Veterinary Medicine, University of Al-Qadisiyah. This is an open access article under the CC BY 4.0 license (<http://creativecommons.org/licenses/by/4.0/>).

Introduction Cats are mostly affected by feline distemper, commonly referred to as feline panleukopenia virus (FPV), which is highly contagious and frequently fatal disease caused by resilient parvovirus (1,2). It can be effectively transmitted by direct contact with diseased cats or their secretions, or by indirect contact with contaminated environments, fomites, or even flea vectors (3). Additionally, the virus attacks the cerebellum in prenatally infected kittens, causing hypoplasia and coordination problems (4,5). After an incubation period of about 2 to 7 days, infected cats suddenly develop acute, severe signs, including a high temperature, profound depression, lethargy, anorexia, persistent and sometimes violent vomiting, severe hemorrhagic diarrhea, and dehydration. Fever is often replaced by hypothermia as the illness progresses, and shock also occurs (6). Pathologically, the virus prefers rapidly dividing cells. This leads to specific histopathological changes in certain tissues. Most notably, the virus damages bone marrow,

leading to a severe reduction in the generation of white blood cells (leukopenia/panleukopenia) and a compromised immune system. The fast dividing cells that border the crypts are destroyed by the intestinal virus, which results in the collapse of the villi. As a result, the thin, smooth intestinal lining cannot function properly, causing severe inflammation, bleeding, vomiting and diarrhea. Moreover, lymphoid structures including the thymus, lymph nodes, and spleen show atrophy and shrinking. Feline distemper diagnosis is based on clinical signs and the identification of viral antigen in feces by enzyme-linked immunosorbent assay (ELISA) or polymerase chain reaction (PCR) (7). Broad spectrum antibiotics, antiemetics, and adequate intravenous fluid therapy are the basis of treatment (8). Regular vaccinations and complete disinfecting of the premises are the only ways to prevent and control the disease (9).

Materials and methods

Ethical approval

On October 2, 2024, the University of Mosul's College of Veterinary Medicine's institutional animal care and use committee approved the sample collecting protocol under approval issue number UM.VET.2024.142

Case presentation

A Persian kitten, unvaccinated, weighing 0.72 kg and 3.5 months old was brought to the Veterinary Teaching Hospital at Mosul University on March 19, 2025, initially exhibiting fever, lethargy, and anorexia. This was followed by vomiting, diarrhea, dehydration (8%), and hypothermia. Intramuscular vitamin B-complex (0.5 mL/kg), intravenous sodium chloride (0.9%) (43.2 mL/day) for dehydration, intravenous ampicillin (22 mg/kg) for infection, intravenous ondansetron (0.2 mg/kg) for vomiting, and supportive care in a warm environment were used as treatment. The prognosis remained poor because of the severity of the disease, even with this intensive therapy that was started right away. Two hours after the start of medication, the kitten died without responding (Figure 1).

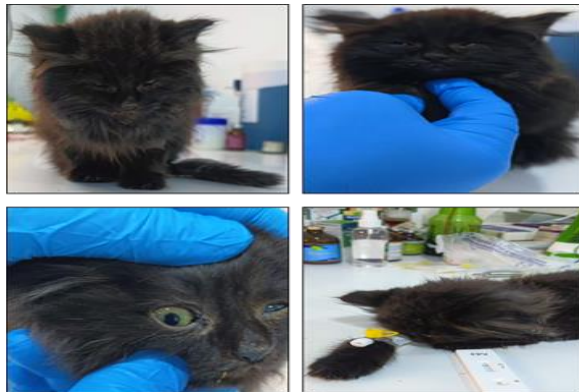

Figure 1: A Persian kitten, 3.5 months old, was brought to the Veterinary Teaching Hospital. The kitten died two hours after the medication started without responding.

Laboratory diagnosis

A sterile cotton swab stick was used to collect the fecal sample, and a commercial immunochromatographic test (BT Pet Medical (Nanjing), China) was used to diagnose feline distemper virus antigen in accordance with the manufacturer's instructions. Within 5–10 minutes, both the control and test lines appeared on the strip, indicating the test was valid. In order to confirm the FPV infection by conventional PCR and make an accurate diagnosis, DNA from the feces was extracted using a DNA stool extraction kit (AddBio Inc., South Korea). They used two specific FPV primers (Macrogen, South Korea): FMF (5-GCT TTA

GAT GAT ACT CAT GT-3) and FMR (5-GTA GCT TCA GTA ATA TAG TC-3) (10). In a total volume of 20 µl, there were six microliters of nuclease-free water, two microliters of DNA, ten microliters of master mix (AddBio Inc., South Korea), and one microliter of each Forward and Reverse primer. A thermocycler (Bio-Rad, USA) was used to perform the amplification under these conditions: one cycle of 95°C for 10 minutes, followed by 35 cycles including 45 seconds at 95°C, 45 seconds at 60°C, and 45 seconds at 72°C. Following that, a single seven-minute cycle at 72°C was chosen for the last extension. The final temperature of the steps was 4°C. Using a 1.5% agarose gel made with 1x Tris-Borate-EDTA buffer and a red safe DNA coloring solution (GeNetBio, South Korea), the amplified products were verified using electrophoresis. It was carried out using a 100 bp DNA marker (AddBio Inc., South Korea) at a voltage of 80 volts and 300 milliamperes for sixty minutes. The findings were documented using a UV transilluminator and a digital camera (Bio-Rad, USA) (11).

Necropsy and pathology

A necropsy was performed immediately after kitten death. Tissues, 1 cm³ in volume and 3-5 mm thick, of the intestine (ileum), mesenteric lymph nodes, liver, and spleen were collected and stored in 10% buffered formalin for 48 hours. The samples were cut into 5 µm sections after being embedded in paraffin. The sections were seen under a light microscope following hematoxylin and eosin staining (12).

Results

Immunochromatographic test and PCR

The immunochromatographic test revealed that the fecal sample was positive (Figure 2A); the PCR test showed a positive amplicon, with a yield of 695 bp (Figure 2B).

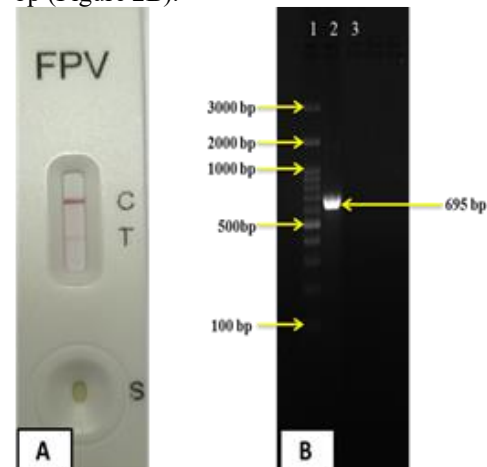


Figure 2: A: Detection of the feline distemper virus antigen using an immunochromatographic test. B: Agarose gel (1.5%) electrophoresis of PCR amplification of virus antigen. Lane 1: DNA ladder 100bp, lane 2: positive sample, lane 3: negative control.

Histopathological finding

The histopathology revealed characteristic amphophilic intranuclear inclusion bodies marginating chromatin, along with necrosis, infiltration and mono-nuclear inflammatory cells infiltration, atrophy and necrosis of enteric glands and crypts epithelial cells in the ileum (Figure 3A). Similar inclusion bodies, depletion and necrosis of lymphoid follicular lymphocytes, necrosis, and increased fibrosis were present in the mesenteric lymph node and spleen (Figure 3B & D). The liver also exhibited inclusion bodies, coagulative hepatocyte necrosis, and infiltration of inflammatory cells (Figure 3C).

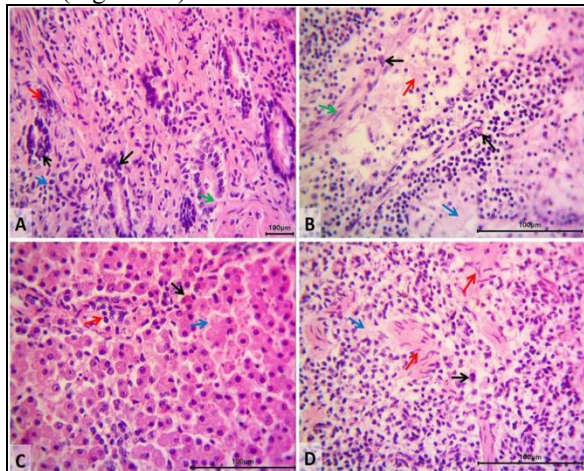


Figure 3: Photomicrographs of kitten infected with feline distemper virus. [A]: ileum revealed epithelium amphophilic intranuclear inclusion body (parvovirus) marginates the chromatin (→), polymorph and mono-nuclear inflammatory cells infiltration (→), atrophy (→) and necrosis of enteric glands and crypts cells (→). [B]: mesenteric lymph node revealed amphophilic intranuclear inclusion body (→), depletion and necrosis of lymphoid follicles lymphocytes (→), proteinitious deposition (→), and increase fibrous tissue (→). [C]: liver revealed amphophilic intranuclear inclusion body (→), coagulative necrosis of hepatocytes (→), inflammatory cells infiltration (→). [D]: spleen revealed amphophilic intranuclear inclusion body (parvovirus) (→), depletion and necrosis of the lymphocytes in the white pulp and (→) and high increased fibrous tissue of the trabeculae (→). H&E stain, 400X. Scale-bar=100 µm.

Discussion

In this case report, a diseased kitten was identified based on clinical signs, and the diagnosis was verified by immunochromatographic test and PCR for detection of viral antigen in feces. The feline distemper virus caused severe enteritis, which led to electrolyte imbalance and dehydration despite all attempts to cure the afflicted kitten. Nevertheless, the kitten died. These findings are in agreement with Bauder et al. (13), they reported that feline distemper is cause significant harm to the small intestine's mucosal lining epithelium, circulating white blood cells, and mesenteric lymphocytes, all of which are linked to deaths of infected cats. Moreover, all cats can be infected with feline distemper, but because the virus tends to multiply in rapidly growing cells, kittens are particularly susceptible. This is especially common in high-density environments, such as animal shelters, where the cats reside and are not vaccinated (14).

The histopathological results found in this case report are consistent the findings of Castro et al. (15), they documented that the significant intestine damage linked to feline distemper caused serious pathological alterations. In addition, the virus causes significant necrosis of epithelial crypts, which leads to villi shortening and degradation in support of the current observations of microscopic lesions (16). Also, the feline distemper virus invaded highly divided cells in the intestinal mucosa, rapidly destroying the cells and causing necrosis and apoptosis in the dividing cells as a result of the virus's continued replication (17). The findings revealed that the mesenteric lymph node had an increase in fibrous tissue, proteinitious deposition, necrosis and depletion of lymphoid follicles, and an amphophilic intranuclear inclusion body. The liver showed coagulative hepatocyte necrosis, an inflammatory cell infiltration, and an amphophilic intranuclear inclusion body. In addition, the spleen had an amphophilic intranuclear inclusion body, lymphocyte depletion and necrosis in the white pulp, and an increase in fibrous tissue of the trabeculae. These findings are in agreement with Truyen, (18), who found that the lymphatic tissues were additionally adversely affected by the widespread infection of the virus, particularly the spleen and other lymph node, which led to lymphoid depletion and subsequent immunosuppression. Additionally, when feline distemper virus invaded the proliferating cells in the targeted tissues of infected cats, the viral DNA and its nucleocapsid caused the cells' DNA to break, which ultimately resulted in the cells' death. This phenomenon is known as the cytopathic effect. As well, the released of virus particles upon



multiplication caused these infected cells to die, and its replication remnants were included intranuclearly as inclusion bodies (19-22).

Conclusion

The polymerase chain reaction is a reliable method for confirming infection in clinically suspected kitten. The histopathological findings directly explained the observed clinical presentation of severe gastroenteritis leading to kitten death. Furthermore, this fatal case highlights that feline distemper remains a significant and lethal threat to unvaccinated kittens.

Acknowledgment

The study was funded by the College of Veterinary Medicine at the University of Mosul in Mosul, Iraq.

Conflict of interest

Regarding the publishing of this case report, the authors have stated that they have no conflicts of interest.

Funding source

This research had no specific fund; however, it was self-funded by the authors

References

1. Barrs VR. Feline panleukopenia: a re-emergent disease. *Veterinary Clinics: Small Animal Practice*, (2019); 49(4), 651-670. [DOI: 10.1016/j.cvsm.2019.02.006](https://doi.org/10.1016/j.cvsm.2019.02.006)
2. Porporato F, Horzinek MC, Hofmann-Lehmann R, Ferri F, Gerardi G, Contiero B, Vezzosi T, Rocchi P, Auriemma E, Lutz H, and Zini E. Survival estimates and outcome predictors for shelter cats with feline panleukopenia virus infection. *J Am Vet Med Assoc*, (2018); 253(2), 188-195. [DOI: 10.2460/javma.253.2.188](https://doi.org/10.2460/javma.253.2.188)
3. Bergmann M, Schwertler S, Speck S, Truyen U, Reese S, and Hartmann K. Faecal shedding of parvovirus deoxyribonucleic acid following modified live feline panleukopenia virus vaccination in healthy cats. *Vet Rec*, (2019); 185(3), 83. [DOI: 10.1136/vr.104661](https://doi.org/10.1136/vr.104661)
4. Abdo R, and Attallah A. Evidences for Diagnosis of Feline Panleukopenia Viral Infection in Cats in Egypt: Molecular, Pathological and Histopathological Findings. *Glob Vet*, (2017); 19(4), 579-585. [DOI: 10.5829/idosi.gv.2017.579.585](https://doi.org/10.5829/idosi.gv.2017.579.585)
5. Pacini MI, Forzan M, Franzo G, Tucciarone CM, Fornai M, Bertelloni F, and Mazzei M. Feline parvovirus lethal outbreak in a group of adult cohabiting domestic cats. *J Pathog*, (2023); 12(6), 822. [DOI: 10.3390/pathogens12060822](https://doi.org/10.3390/pathogens12060822)
6. Tuzio H. Feline Panleukopenia. *Infect. Dis. Manag. Anim. Shelter*. 2nd ed. 2021, Chapter 15, 337-366. [DOI: 10.1002/9781119294382.ch15](https://doi.org/10.1002/9781119294382.ch15)

7. Ye J, Li Z, Sun FY, Guo L, Feng E, Bai X, and Cheng Y. Development of a triple Nano PCR method for feline calicivirus, feline panleukopenia syndrome virus, and feline herpesvirus type I virus. *BMC Vet Res*, (2022); 18(1), 379. [DOI: 10.1186/s12917-022-03460-9](https://doi.org/10.1186/s12917-022-03460-9)

8. Awad RA, Hassan SA, and Martens B. Treatment of Feline panleukopenia virus infection in naturally infected cats and its assessment. *J Biol Sci*, (2019); 19(2): 155-160. [DOI: 10.3923/jbs.2019.155.160](https://doi.org/10.3923/jbs.2019.155.160)

9. Wang T, Wu H, Wang Y, Guan Y, Cao Y, Wang L, and Tian K. Virus-like Particle Vaccine for Feline Panleukopenia: Immunogenicity and Protective Efficacy in Cats. *Vaccines*, (2025); 13(7), 684. [DOI: 10.3390/vaccines13070684](https://doi.org/10.3390/vaccines13070684)

10. Chowdhury QMMK, Alam S, Chowdhury MSR, Hasan M, Uddin MB, Hossain MM, Islam M R, Rahman MM, and Rahman MM. First molecular characterization and phylogenetic analysis of the VP2 gene of feline panleukopenia virus in Bangladesh. *Arch Virol*, (2021); 166(8), 2273-2278. [DOI: 10.1007/s00705-021-05113-y](https://doi.org/10.1007/s00705-021-05113-y)

11. Yang DK, Park YR, Park Y, An S, Choi SS, Park J, and Hyun BH. Isolation and molecular characterization of feline panleukopenia viruses from Korean cats. *Korean J Vet Res*, (2022) ;62(1):e10. [DOI: 10.14405/kjvr.20210050](https://doi.org/10.14405/kjvr.20210050)

12. Luna LG. Manual of histologic staining methods of the armed forces, Institute of pathology. 3rd ed. New York: Mc Graw - Hill Book company; (1968). 1-64, 236 p

13. Bauder B, Suchy A, Gabler C, and Weissenböck H. Apoptosis in feline panleukopenia and canine parvovirus enteritis. *J Vet Med B Infect Dis Vet Public Health*, (2000); 47(10), 775-784. [DOI: 10.1111/j.1439-0450.2000.00411.x](https://doi.org/10.1111/j.1439-0450.2000.00411.x)

14. Rehme T, Hartmann K, Truyen U, Zablotzki Y, and Bergmann M. Feline panleukopenia outbreaks and risk factors in cats in animal shelters. *Viruses*, (2022); 14(6), 1248. [DOI: 10.3390/v14061248](https://doi.org/10.3390/v14061248)

15. Castro NB, Rolim VM, Hesse KL, Oliveira EC, Almeida PR, Wouters AT, and Sonne L. Pathologic and immunohistochemical findings of domestic cats with feline panleukopenia. *Pesqui Vet Bras*, (2014); 34, 770-775. [DOI: 10.1590/S0100-736X2014000800011](https://doi.org/10.1590/S0100-736X2014000800011)

16. Pirarat N, Kaewamatawong T, and Techangamsuwan S. A retrospective immunohistochemistry study on feline panleukopenia virus-induced enteritis, in cats. *The Thai journal of veterinary medicine*, (2002); 32(4), 71-78. [DOI: 10.56808/2985-1130.1895](https://doi.org/10.56808/2985-1130.1895)

17. Chen AY, Luo Y, Cheng F, Sun Y, and Qiu J. Bocavirus infection induces mitochondrion-mediated



- apoptosis and cell cycle arrest at G2/M phase. *J Virol*, (2010); 84(11), 5615-5626. [DOI:10.1128/JVI.02094-09](https://doi.org/10.1128/JVI.02094-09)
18. Truyen U. Evolution of canine parvovirus—a need for new vaccines? *Vet Microbiol*, (2006); 117(1), 9-13. [DOI: org/10.1016/j.vetmic.2006.04.003](https://doi.org/10.1016/j.vetmic.2006.04.003)
19. Neuerer FF, Horlacher K, Truyen U, and Hartmann K. Comparison of different in-house test systems to detect parvovirus in faeces of cats. *J Feline Med Surg*, (2008); 10(3), 247–251. [DOI: 10.1016/j.jfms.2007.12.001](https://doi.org/10.1016/j.jfms.2007.12.001)
20. Truyen U, Addie D, Belák S, Boucraut-Baralon C, Egberink H, Frymus T, and Horzinek MC. Feline panleukopenia. ABCD guidelines on prevention and management. *J Feline Med Surg*, (2009); 11(7), 538-546. [DOI: 10.1016/j.jfms.2009.05.002](https://doi.org/10.1016/j.jfms.2009.05.002)
21. Hamad M, and Abdulgafor A. Molecular Detection of *Pseudomonas aeruginosa* in Feline Otitis Externa. *Al-Qadisiyah Journal of Veterinary Medicine Sciences*, 22(Special issue: Proceedings for the Scientific Conference of the College of Veterinary Medicine, University of Al-Qadisiyah (7th National/2nd International-2023)), 27-33. DOI: 10.29079/qjvms.2023.183454
22. Abdhullah K, and Ali M. First Serological detection of *Leishmania spp* of domestic and stray cats in Al-Qadisiyah Province, Iraq. *Al-Qadisiyah Journal of Veterinary Medicine Sciences*, 2025;24(1), 110-115. DOI: 10.29079/qjvms.2025.156213.1054