

Study of the Mange in Mountain Goats In Iraq

W.A. Ahmed*, A. K. Al-Azawi*, F. S. Kadhim* and H. S. Rasool**

*College of Veterinary Medicine/ University of Baghdad

**Ministry of Agriculture

Abstract

This study was conducted on (250) Mountain goats (*Capra aegagrus*), from month to 6 years old of both sexes, they were housed in private farm in South Baghdad during October 2006. One hundred and fifty goats (60%) were found infested with mange. The highest rate of infestation was (58%) observed in the age of less than 1-2 years old, whereas the lowest rate (42%) recorded in 3-6 years old. The clinical signs varied from irregular red spots, scattered in different parts of body to active dermatitis characterized by rough, thick and Keratinized skin, covered by scales and crusts. The main findings of disease were intense pruritis with focal alopecia, papules and vesicular which are abundant over the back region. The skin lesions observed clearly in the head, ear neck, tail and back regions. Two genera of mites *Sarcoptes* and *Psoroptes* were found in the skin scrapings with infestation rates of 38%, 26.7% respectively. Two injections of ivermectine drug were administered subcutaneously at dose of 0.2 mg/Kg body weight 1% concentration for treating affected animals. Excellent results were obtained by the rapid disappearance of mites from skin scrapings after one week of treatment, the skin lesions relived and improved in condition.

دراسة عن الجرب في الماعز الجبلي في العراق

وفاء عبد الاله أحمد*، أثمار خضير العزاوي*، فوزية شعبان كاظم* وحمودي شاكر رسول**

*كلية الطب البيطري/ جامعة بغداد

**وزارة الزراعة

الخلاصة

أجريت الدراسة على (250) رأس من الماعز الجبلي (*Capra aegagrus*) تراوحت أعمارها بين شهر ولغاية 6 سنوات ومن كلا الجنسين في حقل جنوب بغداد خلال شهر تشرين الأول لعام 2006. وجد ان 60% من الماعز مصاب بداء الجرب. لوحظت ان النسبة العالية للإصابة 58% كانت في الاعمار الصغيرة (أقل من 1-2 سنة)، بينما كانت النسبة منخفضة 42% في الأعمار بين 3-6 سنوات. تراوحت العلامات السريرية بين بقع حمراء ذات حافات غير منتظمة منتشرة في مناطق مختلفة من الجسم، إلى التهاب بالجلد تميز بخشونة وتثخن وتجعد الجلد مغطاة بالقشور والبثور. أن أهم العلامات المرضية هي الحكمة الشديدة مع تساقط الشعر وظهور الحطاطات والفقاعات بكثرة في منطقة الرأس والظهر ولوحظت الآفات الجلدية بصورة واضحة في الرأس وفي الأذنين، العنق، الذيل ومنطقة الظهر. تم تشخيص جنسين من الحلم في قشطات الجلد (*Psoroptes* و *Sarcoptes*) وبنسبة إصابة 38% و 26.7% على التوالي. عولجت الحيوانات المصابة مرتين بعقار أيفرمكتين تركيز 1% وجرعة 0.2 ملغم لكل كغم من وزن الجسم تحت الجلد، تم الحصول على نتائج جيدة من خلال الاختفاء السريع للحلم من القشطات الجلدية بعد أسبوع من العلاج مع اختفاء الآفات الجلدية وتحسن الحالة.

Introduction

Mange is one of serious contagious diseases that infests animals. In Iraq, an earlier report of mange in sheep and goats was made by(1). The disease has been founded of more frequent occurrence in a wide range of domestic animals (2,3,4,5). The mites which spend their life on the host cause various skin disorders. The great economic losses from *sarcoptic* and *psoroptic* mites include damage of the leather caused by the lesions (6). In a study conducted in north Iraq, it has found that mange constituted 100% of the skin disease in buffaloes,(97%) in camels, (31.6%)in goats and (28.5%)in sheep (7). From a review of the literature it became apparent that Mountain goats *Capra aegagrus* infestation with mange have not been investigated in Iraq, therefore the aim of the study was to describe the occurrence and the clinical features of mange beside to treatment of the affected animals.

Materials and Methods

A visit was paid to a private farm in which 250 Mountain goats from month to 6 years old of both sexes were housed in farm in South Baghdad city during October 2006. The animals examined clinically and were found to have skin lesions. Parasitic infestation was suspected, therefore the affected animals were isolated in open enclosure environment and scrapings of skin were made from each area showing lesions . All keratinous material collected with a drop of glycerin were placed into 50 ml of screw tube, a capped and labeled, subsequently at the laboratory of parasitology in the Veterinary Medicine college,of Baghdad examination of scraping samples were performed as described by(8). Once one mite has been identified in the sample was considered positive .Identification the genus of the mites were based on morphologic characteristics described by (9). The affected animals were treated by Ivermectin drug . Two injections at 14 days interval were administered subcutaneously at a dose of 0.2 mg/kg body weight (concentration 1 %). A second skin scraping was done one week post treatment and daily examination of the animals to confirm a cure.

Results

Results revealed that 60% of the animals were found infestated with mange disease. The highest rate of infestation 58% was observed at the age less than 1-2 years, which showed weakness and debilitation, while the lowest rate 42% was in 3-6 years old (Table 1). The affected animals showed different clinical signs and skin lesions, varied from red spots scattered in several areas of the body to active dermatitis, characterized by rough, thick and wrinkled skin. The extensive lesions were papules and vesicles which were abundant over the head and back regions. The lesions appeared as irregular patches varied in size from a pin point to an inch in diameter and sometimes larger, covered with thick white and yellowish scales and crusts. Few number of the affected animals showed numerous nodular lesions, all over the entire body, covered with crusts. More over all the animals had an evidence of intense prurities, they became restless bite themselves and rub the affected areas by the corners and walls, resulting in progressive alopecia. The head was the most common site of infestation, the lesions being the most marked in the nose around and ear cavities and in the form of folds in the neck. (Figure 1,2,3) Many affected animals showed lesions confined to root of the tail and back region. Examination of skin scrapings revealed presence of different stages of mites,(Adults and eggs). Two genera *sarcoptes* and *psoroptes* mites were identified,(Figure 4,5,6). Table.2 showed that 38% 26.7% infected animals were found infestated with *sarcoptes* and *psoroptes* mites respectively, while 35.3% were found infestated with both genera. All treated animals showed no mites in skin scrapings taken a week post the second dose. Animals started to show marked recovery, and rapid disappearance of intense prurites, the animals stopped biting and rub themselves. Skin lesions healed rapidly, no active lesions were present in any of the treated animals by day 21 post treatment. These animals were returned to the farm with others healthy animals.

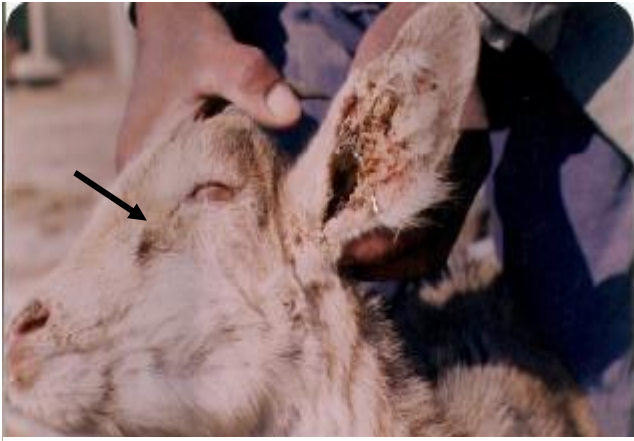

Figure (1) Goat infestated with Mange at the face and inside ear

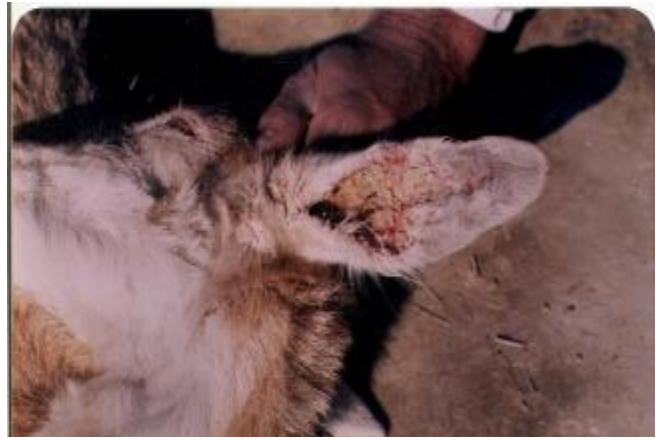

Figure (2) Goat infestated with mange at the face and ear and neck



Figure (3) Goat infestated with mange at the face and ear

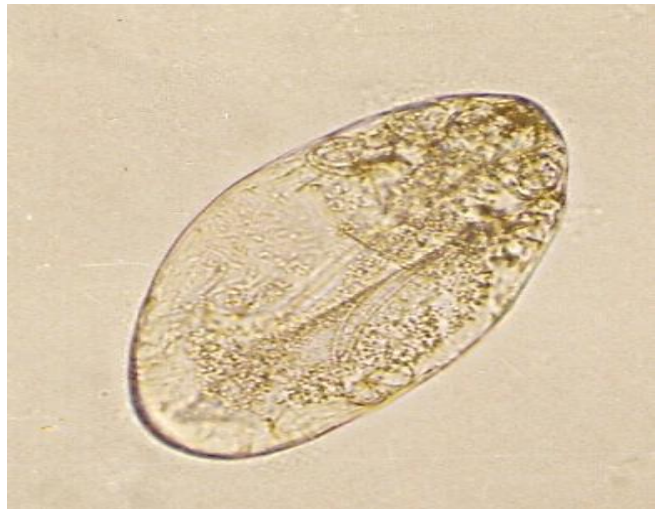

Figure (4) Sarcoptes egg X 250

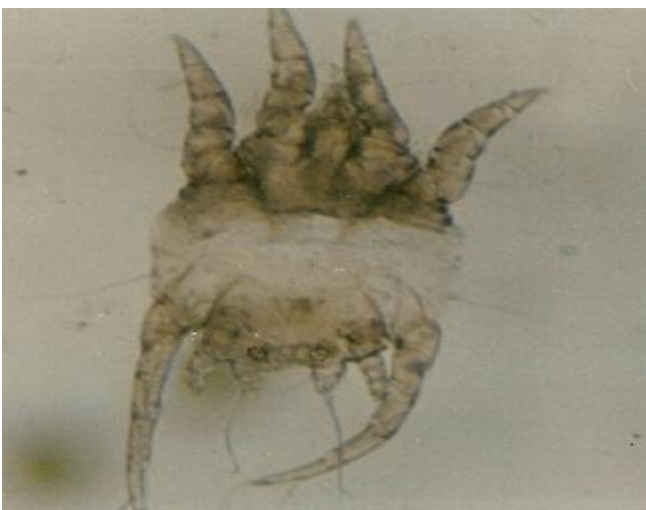

Figure (5) *Psoroptes* male

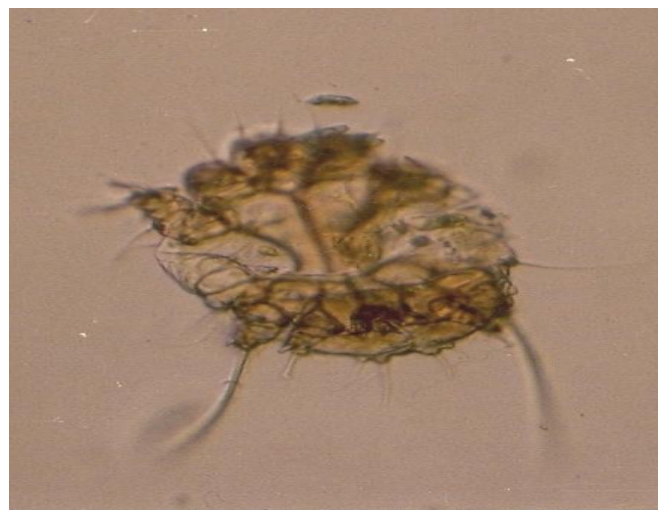


Figure (6) *Sarcoptes* femals

Table (1) The rates of infestation with mange diseases according to their ages

Total number of the goats	Number of affected animals	%	Ages of affected animals			
			1-2 years		3-6 years	
			N0	%	N0	%
250	150	60	87	58	63	42

Table (2) The rates of infestation with *Sarcoptes* and *Psoroptes* mites and rate of infestation with both mites

Number of affected animals	<i>Sarcoptes</i> mite		<i>Psoroptes</i> mite		Number of infestation with both mites	
	N0	%	N0	%	N0	%
150	57	38	40	26.7	53	35.3

Discussion

Results showed that mange affected large number of Mountain goats inflicting a high morbidity rate, due to high stocking rate, were the animals farmed in humid premises, beside short life cycle of mites (10) and decrease in the temperature degree to 13.3 °C and increase in the humidity to 53% during October in Iraq(2), providing good condition for transmission of mites. The low temperature and high humidity have a significant effect on the biological activity and survival rate of the mites, which became more active during cold season (11). By an increasing in the number of mites the mortality rate reach 100% in the affected animals(10) The highest rate of infestation was recorded in young goats less than 1-2 years old, those kept closely to the large animals which increased the chance of exposure to the disease from affected animals. These observation agree with results of (2)and in contrast with results of (6) which recorded 41.4 % rate at 2-4 years old and the lowest rate 15.9 % at less than 2 years , whereas(12) recorded 16% out of 802 feral goats at age of 2-4 years and lowest rate 8.6% at age less than 2 years without mention the reasons. The clinical findings in case of Mountain goats were characteristic by rough, Corrugated and folding of the skin accompanied with focal alopecia. The skin covered with yellowish scales and crusts which was seen in several regions of the body, these findings were similar to those found by (13,14,15,16,17). The affected animals were suffered from intense prurities, due to the bites on the affected parts (18,19). they mentioned that animals became sensitized to mites excrement this sensitivity as a result of an allergic reaction. *Sarcoptes* mites were found the most prevalent type than *Psoroptes*, in Mountain goats, and these findings were agree with (6) results which recorded a rate of 17.62 % with *Sarcoptes* mites and 9.17 % rate with *Psoroptes* whereas(12) recorded 100% of 802 feral goats infestation with *Psorotes cunicul* mites and in Egypt (13) recorded 8.17 % and 4.18% rate with *Psoroptes* and *Sarcoptes* respectively. Both genera of mites could infestate goats equally. (13) The head was the most common site of mites infestation, notably the ear, a round and inside a cavities of ear, these results were incorrident with results of most studies in goats(17,18). Two injections with Ivermectin drug subcutaneously has been provide to be effective and practical way in controlling mange in Mountain goats, the many difficulties implicit in the use of toxic chemical sprays could be avoided. Beside the *Sarcoptes* and *Psoroptes* mites have an area of retreat on concealed parts of the body, such as fold, ear cavities, crusts and scales (19,20), were not reached directly by the acaridae during spraying. The second dose was necessary to kill larvaes which have hatched from eggs at the meantime. All treated animals were virtually mites free since no mites were seen in the skin scrapings taken one week post treatment. The rapid disappearance of intense prurities and subside of the skin lesions, these findings were similar to these obtained by (14,21).

References

- 1- Leiper, N.D. (1957). Report to the Government of Iraq on animal parasites and their control. F.A.O., No. (610).
- 2- عبد، صفاء سالم. (1989). مسح للطفيليات الخارجية في الأغنام والمعز. رسالة ماجستير مقدمة إلى كلية الطب البيطري. جامعة بغداد.
- 3- Abbas, M.A. (1985). Study of the mange in Camles in Iraq. M.Sc. thesis. College of Veterinary Medicine, University of Baghdad.
- 4- Al- Khafaji, N. J.; Rhaymah, M. S. H. & Al-Farwaji, M. I. (1995). Prevalence of clinical disease in Cattle in Mousl, Nineveh province, Iraq. Iraqi J. Vet. Sci., 8(1): 145-150.
- 5- Al-Darraji, A. M.; Salameh, S. B. & Kadhim, F. Sh.(1993). The clinical and pathological finding of an out break of mange in Buffalous 1st Sci. Conf. of the Coll. of Vet. Med. Baghdad.
- 6- الزبيدي، حليم حمزة حسين. (2003). دراسة الانتشار والتأثيرات النسيجية والاقتصادية للإصابات الطفيلية الخارجية على الضأن في بغداد. رسالة ماجستير مقدمة إلى كلية الطب البيطري، جامعة بغداد.
- 7- Al- Khafaji, N. J.; Rhaymah, M. S. H. & Al-Saad, K. M. (1995). Skin disease in different animal species, Nineveh province, Iraq. Iraqi J. Vet. Sci., 8(1): 151-156.
- 8- Harry, D. P. & Jame, W. S. (1981). Diagnostic procedures for Bacterial, Mycotic and parasitic infection 5th Ed. Balows, William and Hauster, PP. 1197-1216.
- 9- Soulsby, E. J. L. (1982). Helminths, Arthropods and protozoa at Domesticat animals 7th Ed. Bailliere Tindall and Cassell., London, PP.809.
- 10- Marquardt, W. C.; Demaree, R. S. & Grive, R. B. (2000). Parasitology and Vector Biology. 2nd Ed. Acadmic Press. U.S.A. PP. 657.
- 11- Smith, E. E.; Wall, R.; Berriatna, E. & Frend, N. P. (1999). The effect of temperature and humidity on the off host survival of *Psoroptes ovis*. Vet. Parasitol., 83: 265-275.
- 12- Heath, A. C. G.; Bishap, D. M. & Tanquist, J. D. (1983). The prevalence and pathogenicity of *Chorioptes bovis* and *Psoroptes cuniculi* infestation in feral goats in New Zealand. Vet. Parasitol., 13:159-169.
- 13- Kandil, N. S. A. E. A. (2000). Some ectoparasite of goats. MVSC Thesis, Zagazig Univ. Egypt.
- 14- البدراني، باسمه عبد الفتاح محمد. (1998). دراسة سريرية وعلاجية لمرض الجرب في الضأن في منطقة الموصل. رسالة ماجستير مقدمة إلى كلية الطب البيطري، جامعة بغداد.
- 15- Prasad, J. (1984). Studies on some aspects of scabies in goats and calves Indian .J., 61: 339-343.
- 16- Williams, J. F. & Williams, C. S. F. (1978). *Psoroptic* ear mites in dairy goats J. Am. Vet. Med. Assoc., 173:1582-1583.
- 17- Cook, R. W.(1981). Ear mites. *Psoroptes cuniculi* in goats in New South Wales. Aust. Vet. J., 57: 72-74.
- 18- Davies, D. P.; Moore, M. J. & Pointen, A. M. (1993). *Sarcoptic* mites hypersensitivity and skin lesion in slaughtered Cattle. Vet. Rec., 129:520-523.
- 19- Sanders, A.; Froggatl, P.; Wall, R. & Smith, K.E. (2000). Life cycle stage of *Psoroptes mange* mites. Med. Vet. Ent., 14:131-143
- 20- Abu-Samra, M. T.; Tbrahim, K. E. E. & Aziz, M. A. (1984). Experimental infection of goats with *Sarcoptes scabiei* Var. ovis. Ann. Trop. Med. Parasit., 78: 55-61.
- 21- Cozma, V. E.; Nagrea., O.; Cherman, C. & Sandru, D. (1999). Treatment of bovine Sarcoptic mange. Comparative efficiency Ivermectin and dormectine in. Mange and Myiasis of live stock. Work shops, held, of the University of Cluj, Romonina, PP.51-53.