

Effect of Mulberry crud extract as antioxidant and antiatherogenic experimentally on rabbit

E. R. Al-Kennany*, M. A. Al- Akashe** and S. A. Al-Bajari**

*Dep. of Pathology/ College of Veterinary medicine/ University of Mosul

**Dep. Medical Analysis/ Technical Education/ Mosul

Abstract

This study was conducted to explore the ability of mulberry (*Morus albas* L.) cold and boild crud aqueous extract as antioxidant and antiatherogenic in rabbit after exposure to 0.5% H₂O₂ in drinking water for 30 days.

The results illustrated capability of 0.5% H₂O₂ to initiate oxidative stress via significant increase in malondialdihyde (MDA) level in heart and liver concomitant with significant decrees in Glutathione (GSH) in addition to decreas in high density lipoprotein-c HDL and increase in low density lipoprotein-c (LDL-c) in serum of treated rabbits. While rabbit treated with H₂O₂ associated with mulberry leaves (cold and boild aqueous crud extract) showed a significant increase in GSH concentration of liver and heart tissue as well as increase in HDL-c, decrees in LDL-c and atherogenic index. Histologically, heart, aorta showed less reduction in lipid vacuol and proliferation of vascular smooth muscle cell in media toward intima, but it is not reach to normal picture in rabbit treated with mulberry (*Morus albas* L.) while liver sections showed some vacuolar degeneration.

تأثير مستخلص ثمرة نبات التوت الأبيض كمضاد للأكسدة والتعصد تجريبيا في الأرانب

أنتصار رحيم الكناني*، معتز العكاشي** وشهاب البجاري**

فرع الأمراض وأمراض الدواجن - كلية الطب البيطري / جامعة الموصل

**قسم التحليلات الطبية - المعهد الفني / الموصل

الخلاصة

تضمنت هذه الدراسة معرفة قابلية التوت الأبيض (نوع *Marus alba* L.) بشكل (مستخلص خام مائي بارد ومغلي) كمضاد للأكسدة ومضاد للتعصد في الأرانب بعد تعريضها لبيروكسيد الهيدروجين 0.5% في ماء الشرب لمدة 30 يوما.

أظهرت النتائج قابلية بيروكسيد الهيدروجين 0.5% في إحداث الإجهاد التاكسدي من خلال الزيادة المعنوية في مستوى المالوندايديهايد في القلب والكبد يصاحبها انخفاض تركيز الكلوتاثيون وخفض مستوى الدهون العالية الكثافة ورفع مستوى الدهون الواطئة الكثافة في مصل الأرانب. بينما اظهر استخدام مستخلص التوت الأبيض المائي البارد والمغلي زيادة معنوية في تركيز الكلوتاثيون في القلب والكبد فضلا عن الزيادة في مستوى الدهون العالية الكثافة وخفض الدهون الواطئة الكثافة مع مضاد التعصد.

نسيجيا اظهر كل من القلب والابهر اختزال قليل في الفجوات الدهنية مع تكاثر خلايا العضلة الملساء الوعائية في الطبقة المتوسطة باتجاه البطانة (لكنها لم تصل إلى النسيج الطبيعي) في الأرانب المعاملة بمستخلص التوت الأبيض، أما الكبد فقد أظهرت المقاطع النسيجية وجود بعض التتسكس الفجوي.

Introduction

The imbalance between antioxidants (antioxidant defense) and increased free radicals production leading to oxidative damage is known as oxidative stress (1).

An example of this process is oxidation of membrane bound lipids and lipoprotein known as lipid peroxidation (2). The peroxidation of cellular membrane lipids can lead to cell necrosis and is considered to be implicated in a number of pathophysiological conditions (3) as a type I diabetes mellitus and atherosclerosis.

(*Morus albas* L.) (Moraceae) (MA) white mulberry has long history of medical use in Chinese medicine parts of plant are used as medicine. White mulberry is cultivated through leaves is the main food source for silk worms. Traditionally, the white mulberry plant has been used to treat weakness, fatigue, anemia, and preastare grayi in continence, tinnitus, dizziness and constipation in the alderly patient so far include analgesic, antiasthmatic, antirhaumatic, antitussive, as expectorant, hypotensive and brain tonic (4-8). The plant extraction have radical scavenging activity (9) Hyperglycemic and antioxidant pontenial, hepatoprotective hypoureceemic and cardioprotective action (10). Substances which attract the silk worms larvae to the leaves have been identified as citral linulyl acetale, linalol, terping, acitle, and acelate, hexenol, the first 3 being more effective. B-sitosterol (cazol in leaves) along with some sterols and a water soluloble substances it is the main factor which stimulate the biting action (11).

The amount of food eaten is controlled by the cencentration of B-sitosterol. Protein preparation from young mulberry leaves form an excellent supplement to protein-deficient diet. Non –protein nitrogen accounts for Ca 22% of the total nitrogen in young leaves and Ca 14% in mature leaves – Amino acids identified in the free form are phenylalanine, leucine, valane, tyrosine, proline, alanine, glutamic acid, glycine, serine, arginine, aspartic acid, cystine, threonine, sacosine, gamma– amino butyric acid, pipecolic acid and S-hydroxy pipecolic acid. the leaves are good source of ascorbic acid, with 2-3 ml/g of which over 90% is present in the reduced form. They contain also vitamin B1, folic acid, folinic acid and vitamin D. Phytate phosphores account for 18.2% of total phosphores. Volatile constituents identified in steam- distillates of the leaves are n- butylaldehyde, isobutylaldenyale, valeraldehyal hexaldehyde, alpha-beta-hexenal acetone, methyl-ethylketone, methyl-hexyl-ketone, butylanine, acetic, propionic and isobutyric acids, leaves also contain calcium malate, succinic and tartaric acids, xanthophylls and isoquercitrin (quercetin3-glucosid) and tannis, adenine, chorine, and trigonelline bases are present in young leaves. analysis of leaves give (dry weight basis). protein 14.0; EE, 6.8; NFE, 49.7; total ash 13.8; calcium (Cao, 2.74; and phosphores (P₂O₅) 0.45% (11). In this study we used H₂O₂ in 0.5% (12) to induce oxidative stress to answer the question whether *M. albas* L. leaves extract treatment reduce lipid peroxidation? also to examine the ability of *M. albas* L. as antioxidant and antiatherogenic effect.

Material and Methods

Male local breed rabbits (15) weighting between 750-850 gm were used. The animals were reared in wire cages feed diet and given tap water ad libitum, and housed in a constant (22-25°C) temperature environment with (12h.light and 12h.dark cycle). Animals were divided into five groups of three rabbits each. Group1(GI) received a regular rabbit diet and maintained as a control group; Group II rabbits subjected to experimentally induced oxidative stress by the ad libitum supply of drinking water containing 0.5% H₂O₂ (V/V) [degussa AG merl Rheinfelden, Belgium] was prepared daily over entire 30 days period of the experiment after the end of 30 days of H₂O₂

treated animals were selected randomly to serve as the *Morus albas* L. aqueous extract treated group (GIII) animal of this group received extract of *M.albas* L. for seven days. Group(GIV) received cold crude extract of *M. albas* L. for seven days. Group (GV) received only the regular rabbit diet and subject cold crude *M. albas* L. extraction of intraperitoneal injection about 300mg/kg BW. At the end experiment period, rabbits were bled and plasma samples were analyzed after collection of blood samples after an overnight fast for 12-14h and analysis performed on fresh heparin treated plasma. The lipid parameters TCh, TGs, LDL-c, and VLDL-c were determined by using a standard enzymatic assay (Bio-merck-Marey-I, Eroile formula).

Pieces of heart and liver tissues were removed for estimation of MDA by thiobarbituric acid (TBA) test as previously described by Gilbert and Rothy, (13) GSH concentration of heart and liver were measured according to Morone, et al., (14). For histopathological study, rabbit killed, heart and liver were fixed in 10% neutral buffered formalin to prepare tissue blocks that routinely embedded in paraffin, and 5-6mm sections were cut. Histological sections were stained with haematoxylin and eosin (H+E), (15).

Plant material

The leaves of *M. albas* L. were collected freshly from Mosul city, Iraq. The leaves were air-dried at room temperature and stored in bottles until used. Material was identified in the department of biology in the college of science. The dried leaves (250g) were powdered in an electric blender, put in boiling water (1 litre) for 10 min and the mixture then left to cool to room temperature. The decoction was filtered through Whatman No. 1 filter paper, and the resulting extract which reduced to 1/3 of its volume by a rotary evaporator, then the extraction divided into two parts, first one perceptual by using acetone in order to isolate protein material from non-proteinous material, while the 2nd part was dried until powder formation, so cold crude aqueous extract was prepared (16).

Results

Chemical analysis:

Table (1) showed that 0.5% of H₂O₂ in drinking water significantly increased total cholesterol (Tch) triglycerides (TGS), low density lipoprotein (LDLc), very low density lipoprotein (VLDL-c) and atherogenic index, while high density lipoprotein (HDL-c) showed a significant decrease compared with untreated control rabbits. In male rabbits subjected to H₂O₂ and cold crude aqueous extract (CCA), the level of lipid profile indicated a decrease of Tch, TGs, LDL-c, and VLDL-c. In these rabbits, the level of LDL-c increased significantly (2.77 ± 0.01). Table-1 with cold and boiled crude extract shows the picture of lipid profiles illustrating an increase of HDL-c and with concomitant decreases in Tch, LDL-c as compared with control and H₂O₂ values.

Table (1) level of lipid profile in serum of male rabbit treated with 0.5% H₂O₂ and *M.albas* L. boiled and cold crude aqueous extract

Group	Tch mol/ml	TGS mol/ml	HDL-c mg/ml	LDL-c mol/ml	VLDL-c mol/ml	Atherogenic index
control	d2.17±0.05	d1.77±0.03	a63.0±0.01	b1.48±0.02		
H ₂ O ₂	a4.95±0.05	a1.94±0.06	c0.57±0.02	a2.77±0.01		
H ₂ O ₂ +cold crude aqueous extract	c2.03±0.04	b1.55±0.01	b0.58±0.02	d1.09±0.03		
H ₂ O ₂ +boiled crude aqueous extract	b2.44±0.01	c1.60±0.01	d0.53±0.07	c1.11±0.04		

* Values are expressed as means ± S.D. of 3 rabbits per group.

**Mean with same superscript in the column are significantly different from others (p<0.05).

Tissue MDA concentration:

Tissue (heart + liver) TBA reactive substances were significantly increase in rabbits after 15 days of H₂O₂ treatment as compared with control group (Table 2) The greatest decrease in MDA content was seen in heart and liver with cold crud aqueous extraction and H₂O₂ boil crud aqueous extraction also showed reduction in lipid peroxidation product as compared with H₂O₂.

Tissue GSH concentration:

Table-2 illustrated tissues (heart + liver) GSH content after 30 days of H₂O₂ treatment. There were a significant reduction in animal treated with cold and boild equeous extract of *M.albas* L. treatment as compared with H₂O₂ treatment also. Treatment with extraction revealed significant increase in GSH concentration in heart and liver tissues as compared with control untreated animals (Table 2).Table-3 showed significant increase in glucose level of serum in group treated with 0.5% H₂O₂ (8.16±0.01) as compared with control. While in group treated with cold and boild crud equeous extract of mulberry leaves revealed decrease significantly as compared with H₂O₂ groups.

Table (2) Level of MDA and GSH in heart and liver tissues of rabbit treated with 0.5% H₂O₂ and cold, boild crud equeous extract of *M.albas* L. as compared with control group

Group	MDA /mol		GSH	
	Heart	Liver	Heart	Liver
control	b301±19	b560±11	c1.32±17	c4.54±28
H ₂ O ₂	a709±16	a678±19	d1.013±22	d4.05±19
H ₂ O ₂ +cold crud equeous extract	d187±13	d296±15	a1.729±19	a4.98±22
H ₂ O ₂ +boild crud equeous extract	c254±10	c350±16	b1.463±40	b4.60±39

*Values are expressed as means ± S.D. of 3rabbits per group.

**Mean with same superscript in the column are significantly different from others (p<0.05).

Table(3) level of glucose in serum of male rabbit treated with 0.5% H₂O₂, H₂O₂ and cold,boild crud equeous extract of mulberry leaves

Group	Glucose
control	6.33±0.05
H ₂ O ₂	8.16±0.01
H ₂ O ₂ +cold crud equeous extract	5.71±0.03
H ₂ O ₂ +boild crud equeous extract	5.99±0.11

*Values are expressed as means ± S.D. of 3rabbits per group at (p<0.05).

Macroscopic lesions:

There are no macroscopic lesion observed in rabbit treated with 30 days 0.5% H₂O₂ and H₂O₂ with cold, boild crud extraction of *M.albas* L.

Macroscopic lesions:

No pathological lesion were observed in the heart rabbits of control groups. Heart of groups H_2O_2 treatment revealed fatty changes, congestion of coronary arteries, infiltration of mononuclear inflammatory cells (lymphocytes) and edema between muscle fibers (Fig1).

While in groups treated with H_2O_2 and cold, boiled crud extract of *M.albas* L. showed sever congestion and infiltration of inflammatory cells (lymphocytes) (Fig2).

Aorta: Aortic lesions were seen in rabbits treated with H_2O_2 for 30 days characterized by presence of lipid vacuol in intimal extent to medial layers, collagen, elastin destruction spindle – shaped cells and degeneration of vascular smooth muscle cells (Fig 3,4).

In groups treated with H_2O_2 with cold and boiled crud aqueous extract, aortic section showed proliferation in vsmc and reduction in lipid vacuole in itimal in addition to, proliferation of fibroblast and collagen fibers (Fig 5).

Liver, liver of rabbit treated with H_2O_2 illustrate dilatation in sinusoid, congestion of central vein and blood, vacuolar degeneration on cytoplasm of hepatocytes, privascular and periductular of mononuclear inflammatory cells in addition to fatty change (Fig6). While in groups treated with H_2O_2 and cold and boiled crud aqueous extract revealed dilatation of sinusoid and vascular degeneration (Fig 7).

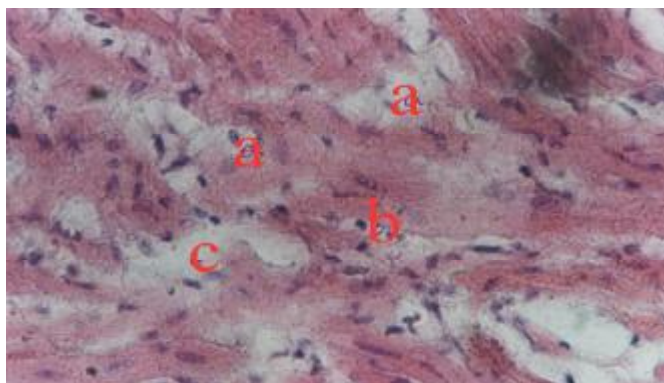


Fig.(1) Photomicrograph of hearts rabbit treated with 0.5% H_2O_2 showed sever fatty change (a), infiltration of mononuclear inflammatory cell (b) and edema(c) H and E 900X

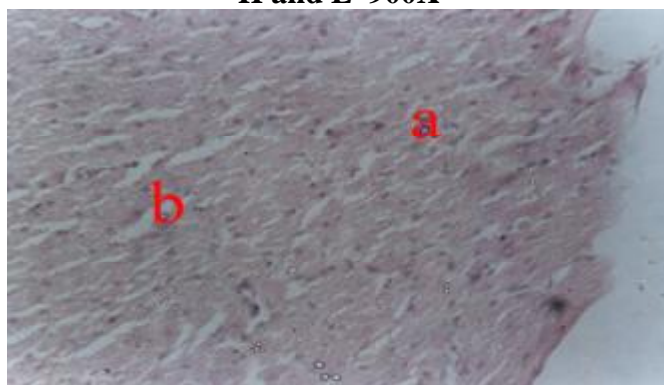


Fig.(2) Photomicrograph of hearts rabbit treated with 0.5% H_2O_2 and mulberry cold crud extract, showed infiltration of mononuclear inflammatory cell (a) and edema(b) H and E 200X

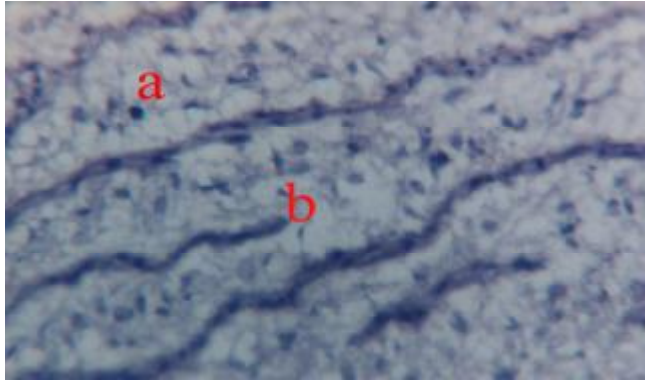


Fig.(3) Photomicrograph of aorta treated with 0.5% H₂O₂, showed presence of lipid vacuole in intima and media (a) fragmentation of elastic membrane (b) H and E 900 X

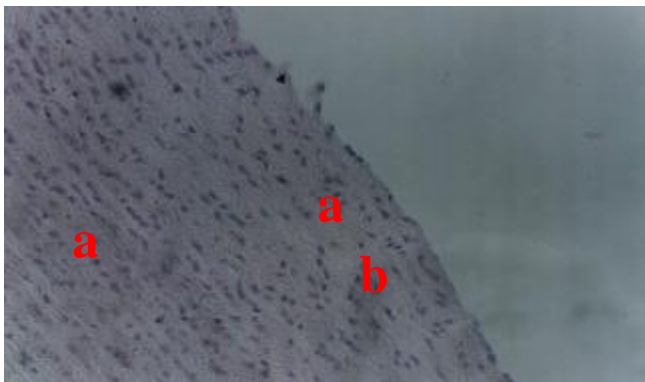


Fig.(4) Photomicrograph of aorta rabbit treated with 0.5% H₂O₂ and boild crud extract of mulberry leaves, showed proliferation of vsmcs (a), reduction in lipid vacuole in intima (b) H and E 450 X




Fig.(5) Photomicrograph of rabbit aorta treated with 0.5% H₂O₂ and cold crud extract of mulberry leaves, showed proliferation in collagen fiber (a) and degeneration of vsmcs (b), H and E 450 X

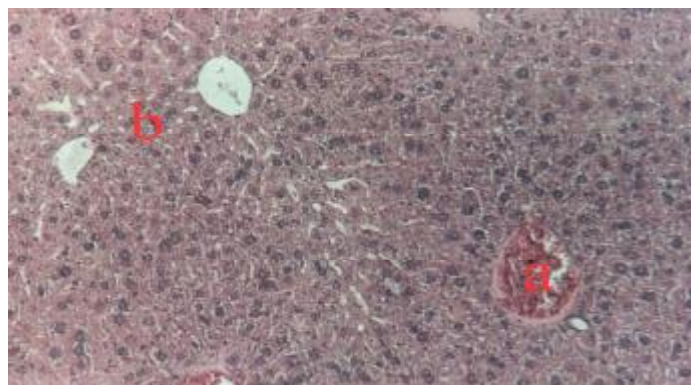


Fig.(6) Photomicrograph of liver rabbit treated with 0.5% H₂O₂, showed congestion of blood vessels (a) fatty change (b) H and E 450 X

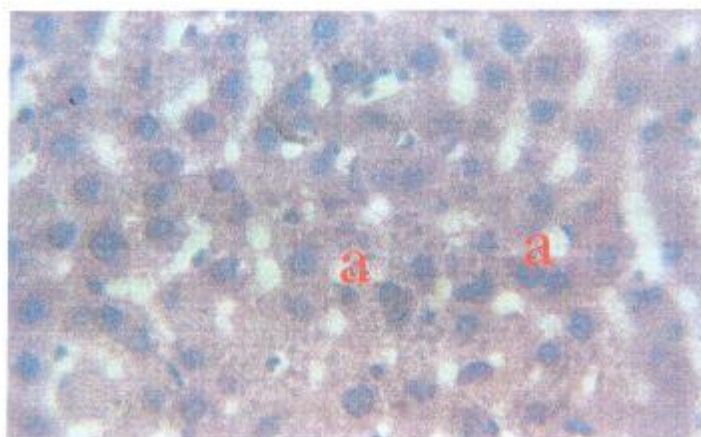


Fig.(7) Photomicrograph of liver rabbit treated with 0.5% H₂O₂ and cold crud extract of mulberry, showed vacuolar degeneration (a) H and E 900 X

Discussion

This study illustrated a marked elevation in level of lipid profile (Tch, TGs, LDL-c, VLDL-c). Lipid concentration in plasmas of rabbit treated with 0.5% H₂O₂ for 30 days, suggesting that these changes reflect susceptibility of animal to experimental induce hyperlipidemia and atherosclerosis by oxidative stress that closely resemble those found in human, chicken, rat and rabbit (12, 17). This study used to test the effect of cold and boiled crude aqueous extract of white mulberry leaves as antioxidant, and antiatherogenic, the importance of mulberry leaf extract as antioxidant (protective effect) take place via its content like flavonoid, which protect LDL-c from oxidation of the initial stages of lipid peroxidation by acting as free radical scavenger (18,19). Quercetin and flavonoid were shown to bind to the surface of LDL particles via the formation of an ether bond (20). Mulberry extraction, both cold and boiled crude extract a significantly amelioration effects on lipid peroxidation and antioxidant status can decrease in level of Tch, TGs, LDL-c, VLDL-c and atherogenic index (Table 1) in addition to, decrease concentration of MDA heart and liver tissues associated with increase level of HDL-c in serum and GSH of heart and liver tissues. Our study suggest that flavonoid and ascorbic acid, important constituent leaf of mulberry and play important role in prevention endothelial cell-mediated LDL-c lipid peroxidation (21). However mulberry leaves extract reduced the tendency of LDL-c oxidize and enhance antioxidant enzyme activity of cells (22). This study revealed that no protection effect of this dose of mulberry leaf aqueous extract was observed at the histopathological levels. Thus, the protective effect of mulberry aqueous extract leaves against H₂O₂

induced oxidative stress and atherosclerosis may be due to changes in the antioxidant enzyme chain breaking antioxidant activity and have antiproliferative properties and its ability to inhibit redox-sensitive signal transduction pathway related to cell growth on vsmcs (23). In this study, the mulberry treatment inhibited the increase in lipid peroxidation of rabbit as compared with the H₂O₂ treated group. Plasma glucose levels were also reduced in the mulberry aqueous extract rabbits. It was suggested that this effect is related to polyhydroxylated alkaloids, including 1-deoxynojirimycin, α -glucosidase, fucogmine, which potentials glucose induced insulin release and to the increase in tissue uptake of glucose by the leaves (24,25, 26).

In conclusion, our study found that treated with mulberry leaves aqueous extract (cold and boiled) was inhibited the effect of H₂O₂ induced changes except the histopathological one, therefore, the use of mulberry as antiatherogenic effect of rabbit illustrated less histopathological effect on aortic lesion via less reduction in lipid vacuoles and induced proliferation of vsmc in media toward intima.

References

1. Ames, B. N.; Shigenaga, M. K.; Carew, T. E.; Khoo, J. C. & Witztum, J. L. (1989). Beyond cholesterol .Modification of low density lipoprotein that increase its atherogenicity. *N Engl. J. Med.*,320:915-23.
2. Gutteridge, J. M. C. (1995). Lipid peroxidation and antioxidants as biomarkers of tissue damage. *Clin. Chem.*, 41:1819-1828.
3. Kappus, H. (1978). Oxidative stress in chemical toxicity. *Achieves of Toxicology*. 60:144-149.
4. Mhaskar, K. S.; Latter, E. B. & Caius, J. S. (2000). Kirtikar and Basus Indian publications. P. 3185.
5. Nakarni, A. K. (1982). *Indian material medica* Vol. Mumbai: popula.
6. Fukai, T.; Hano, Y.; Hirakurak, N. T. & Uzawa, J. (1985). Fukushin Diels-alder type adducts, mulberry furans F and G, Tokyo. 33:3195-204 (pubmed).
7. Jinwy, N. A. R. B.; Leetty, B. K. H. & Kang, S. S. (2002). *Antioxidant prod. Sci.*, 8:129-32.
8. *Ethnomedicines*, L. (2006). Used in Trinidad and Tobago. *For urit Ethnobiol Ethnomedicine.*, 13:45-51.
9. Fukai, T.; Satoh, K.; Nomura, T. & Sakgami, H. (2003). Antinephritis and radical scavenging activities of prenyl flavonoids. *Fitoterapia*,74:720-724.
10. O'Brien, B. A.; Harmon, B.V.; Cameron, D. P.; Allan, D. J. (1997). Apoptosis is the mode of beta-cell death responsible for the development of IDDM in the nonobese diabetic (NOD) mouse –*Diabetes*,46:750-757.
11. Nomura, T.; Fukai, T. & Katayanagi, M. (1980). Study on the constituents of the cultivated mulberry trees. 6. oxidative cyclization of morusin. *J. Hete. Chem.*,17,641-646.
12. Al-Kennany, E. R. (1998). A study on the capability of oxidative stress by hydrogen peroxide to induce atheromatous lesions experimentally in chickens. Ph. D. Vet. medicine, University of Mosul.
13. Gilbert S. D. D. & Roth, E. F. Jr. (1989). A method to correct for error caused by generation of interfering compounds during. *Anal. Biochem.*, 139:282-286.
14. Morone, M. S.; Depierre, J. W. & Mennenivk, B. (1979). Level of glutathione reductase and glutathione S. transferase activities in rats lung and liver. *Bioch. Biophys. Acta.*, 582:67-78.
15. Drury, R. A. D. & Wallington, E. A. (1980). *Carlton histological Technique* the Oxford; Oxford university Press.

16. Al-Chalabi, N. S. (2002). Biochemical study of the proteinaceous compounds isolated from aqueous extract of *Trigonella foenum-graecum* L. seeds. *Raf. J. Sci.*, 13(3): 46 – 55.
17. Al-Kennany, E. R. & Al-Kafaf, A. S. (2006). Role of oxidative stresses induced by Hydrogen peroxide on initiation and development of atherosclerosis in mature femal rat. *Iraq. J. Vet. Sci.*, 2:139-151.
18. Afanasev, I. B.; Dorozhko, A. I.; Brodskii, A. V. & Potapo vitch, A. I. (1989). Chelating and free radicals scევანging meenamzms of inhibitory action of rutin and quercetin in lipid peroxidation. *Biochem. Phrmacol.*, 38:1736-1769.
19. Torel, J.; Cillard. J. & Cillard, P. (1986). Antioxidant activity of flavonoids and reactivity with peroxy radicals. *Phytochemistry*, 25 :383-385.
20. Hayak, T.; Fuhrman, B.; Vaya, J.; Rosenblat, M.; Belinky, P.; Coleman, R.; Elis, A. & Aviram, M. (1997). Reduced progression of atherosclerosis in apolipoprotein E-deficient mice following consumption of red wine. Orits polyphenols quercetin or catechin , is associated with reduced susceptibility of LDL to oxidation and aggregation. *Arterioscler. Throm. Vasc. Biol.*, 17:2744-2752.
21. Esterbauer, H.; Gebicki, J.; Puhl, H. & Jurgens, G. (1992). The role of lipid peroxidation and antioxidant in oxidative modification of LDL- free radical. *Biol. Med.*,13:341-390.
22. Soriano, M.; Rice-Evans, C. & Tyrrell, R. M. (1998). *FEBS Letters*, 439:253-257.
23. Van Het Holf, K. H.; Kivits, G. A. A.; Westerstrate, J. A. & Tijburg, L. B. M. (1998). *Eur. J. Clin. Nutr.*, 52:365-9.
24. Chen, C. C.; Hsc, J. D.; Wang, S. F.; Chiang, H. C.; Yang, M. Y.; Ho, Y. C. & Wang, C. J. (2003). Hibiscus sobdariffa extract inhibits the development of atherosclerosis in cholesterol-feed rabbits. *J. Agric. Food. Chem.*, 51:54-72.
25. Taniguchi, S.; Asano, N.; Tomino, F. & Miwa, I. (1998). Potentiot of glucose-induced insulin secretion by Fagomine.apseudo-sugar isolated from mulberry leaves. *Horm. Metab. Res.*, 30: 679-683.
26. Asano, N.; Kizu, H.; Oseki, K.; Tomioka, E.; Matsui, K.; Okamoto, M. & Baba, M. (1995). N-Alkylated nitrogen –in-the-ring sugars. Conformational basis of inhibition of glycosidases and HIV-1replication. *J. Med. Chem.*, 38: 2349-2356