

Study of the Immunopathological Changes Induced by *Pseudomonas aeruginosa* in Mice Treated with Alcoholic *Apium greveolense* extract and Immunized with Whole Sonicated *Salmonella typhimurium* Antigens

M. J. Alwan^{*}, M. A. Al- Khafaji^{*}, S. S. Al- Najjar^{*} and S. H. Al- Kutbi^{}**

^{*}College of Veterinary Medicine\ University of Baghdad

^{}College of Pharmacy\ University of Baghdad**

Abstract

In order to know the efficacy of whole sonicated antigen with or without celery extract on the challenge with viable virulent *Pseudomonas aeruginosa*, thirty-five healthy white mice, both sex, aged between 6-8 weeks were randomly divided into five groups and treated as following: The 1st group (n= 10) immunized with WSSAgs (0.5ml/lmg protein) S/C as primary dose followed by second dose after two weeks. 2-The 2nd group(n=10) administrated daily dose of 0.5ml of alcoholic celery extract (Concentration of protein 600 mg/kg BW) orally for 30 days and at the same time treated as 1st group. 3- The 3rd group (n=5) administrated orally with alcoholic celery extract only with same dose and time of the 2nd group. The 4th and 5th group (5 animals each) treated as control positive and negative respectively.

Cell mediated and humoral responses were checked at day 27 and day 30 post-immunization, at day 30 post immunization, the 1st, 2nd, 3rd and 4th group were challenged with 0.5 ml of bacterial suspension content 1X10⁸ CFU of viable virulent *Pseudomonas aeruginosa* S/C and the 5th group inoculated S/C with 0.5 ml of sterile normal saline and served as control negative group.

All animals were sacrificed at day 20 post-challenge ,post-mortem examined and bacterial and pathological examination of their internal organs were done.

The results explained that WSSAgs induced cellular and humoral immune response in immunized animal and these values was high in animal pretreated with alcoholic celery extract and immunized with WSSAgs. All non immunized and pretreated alone infected animals died during 24-48hrs post-inoculation with severe bacterial isolation from internal organs as compared with immunized and pretreated immunized infected animals which showed good healthy during the course of experiment and no bacterial isolation from internal organs.

Multiple granulomatous lesion were seen in the internal organs of immunized infected animals while the pretreated immunized infected animals showed lymphocytic aggregation around blood vessels and in the parenchyma of most examined organs ,in contrast, the non-immunized and pretreated infected animals showed acute suppurative reaction with thrombus formation in most examined organs.

دراسة التغيرات المرضية والمناعية التي تحدثها جراثيم الزوائف الزنجارية في الفئران المعاملة
بالمستخلص الكحولي للكرفس والممنعة بالمستضد الكلي لجرثومة *Salmonella*
typhimurium

محمد جويد علوان^{*}، منى عبد الصاحب جليل^{*}، سرهد سعد عبود النجار وسهير حسن علي^{**}
^{*}كلية الطب البيطري/ جامعة بغداد
^{**}كلية الصيدلة/جامعة بغداد

الخلاصة

من اجل معرفة فعالية المستضد الكلي المتكسر لجرثومة السالمونيلا تايفيموريم لوحده أو مع المستخلص الكحولي لنبات الكرفس على جرعة التحدي بالزوائف الزنجارية الضارية في الفئران، استخدم (35) من الفئران السويسرية البيضاء تراوحت أعمارها بين 6-7 أسبوع من كلا الجنسين قسمت عشوائيا إلى خمسة مجاميع وعوملت كما يلي:

1. المجموعة الأولى وتضم (10) حيوانات منعت بالمستضد الكلي المتكسر لجرثومة السالمونيلا بواسطة الحقن تحت الجلد وجرعة (0.5 مل) يحتوي على (1 ملغم بروتين) وبعد أسبوعين أعيدت نفس الجرعة كتقوية.
2. المجموعة الثانية وتضم (10) حيوانات جرعت يوميا (0.5 مل) من المستخلص الكحولي لنبات الكرفس بجرعة (600 ملغم/ كغم من وزن الجسم) وفي نفس الوقت منعت بالمستضد الكلي المتكسر لجرثومة السالمونيلا كما في المجموعة الأولى.
3. المجموعة الثالثة وتضم (5) حيوانات جرعت بالمستخلص النباتي فقط كما في المجموعة الثانية.
4. المجموعتين الرابعة والخامسة وتضم (5) حيوانات لكل منهما عدتا كمجموعتي سيطرة موجبة وسالبة على التوالي.

بعد 30 يوما من أول تمنيع تم فحص الاستجابة المناعية الخلوية بواسطة إجراء اختبار فحص الحساسية المتأخر والخطية بواسطة إجراء اختبار التلازن الدموي الغير مباشر وأصبحت المجاميع الأولى والثانية والثالثة والرابعة بجرعة (0.5 مل) من العالق الجرثومي الحاوي على 10^9 من الزوائف الزنجارية الضارية بواسطة الحقن تحت الجلد، أما المجموعة الخامسة فقد حقنت (0 و 5 مل) من المحلول الملحي الفسلجي واعتبرت سيطرة سالبة وبعد 20 يوم من جرعة التحدي قتلت جميع الحيوانات وأجريت لها الصفة التشريحية وأخذت نماذج عينات للعزل الجرثومي وأخرى للفحص المرضي.

بينت النتائج بأن جميع الحيوانات غير الممنعة والمعاملة بالمستخلص النباتي فقط هلكت خلال 24-48 ساعة بعد الإصابة مع عزل جرثومي كثيف من أعضائها الداخلية بينما كانت الحيوانات الممنعة والحيوانات المعاملة بالمستخلص النباتي بصحة جيدة خلال فترة الدراسة ولم تعزل الزوائف الزنجارية من أعضائها الداخلية كذلك بينت النتائج وجود أورام حبيبية في الأعضاء الداخلية للحيوانات الممنعة بعد الإصابة مع وجود تكيف خلوي لمفي حول الأوعية الدموية وفي النسيج الخلالي للحيوانات المعاملة بالمستخلص النباتي والممنعة بعد جرعة التحدي، بينما أظهرت حيوانات السيطرة الموجبة والحيوانات المعاملة فقط بالمستخلص النباتي استجابة التهابية قبيحية حادة وتكون الخثرة الدموية في الأعضاء الداخلية التي فحصت.

Introduction

Pseudomonas aeruginosa is an important opportunistic pathogen that associated with infections in cystic fibrosis patients, burn patients and another important infection group consists of immunocompromised individuals, such as those undergoing chemotherapy or AIDS patients (1, 2). It is a saprophytic organism widespread in nature, particularly in moist environment (water, soil, plants and sewage) (3) and it is responsible for a wide range of hospital-acquired infections, such as pneumonia, urinary tract infections, bacteremia (4) Moreover, a series of outbreaks due to this important and frequent nosocomial pathogen has been reported in hospital intensive care, burn wound and cancer units (5, 6).

Ps.aeruginosa has several virulence factors including: pili, flagella, lipopolysacchride, alginate and biofilm production, the secretion of several toxins, type III secretion and quorum sensing, along with these virulence factors. *P.aeruginosa* is highly resistant to several antimicrobials and main active agents such as B-lactams and aminoglycosides (7). Thus, vaccination to prevent infection is much more desirable. Several types of vaccines were investigated ranging from whole cell immunization to subunit and DNA immunization (8, 9), even with all of this effort, no vaccine has been fully developed for widespread use.

P.aeruginosa produces 2 form of LPS, A band and B band, B band polysaccharides are much longer than A band polysaccharides and they are the basis for serotyping (10). Currently 20 different serogroups are recognized (11) and the highly immunogenic O-polysaccharide region shows considerable diversity between strains leading to problems in achieving cross-protection between serogroups. Even strains within the same serogroup can have different chemical structures where the protective epitope may be part of the sub-type variant structure and not the serotype common structure (12). However, due to the presence of various LPS serotypes of *P.aeruginosa*, it is difficult to produce protective vaccine against a broad spectrum of *P.aeruginosa* isolates (13).

Previous work in laboratories characterized a vaccine that confers serotype-specific protection against *P.aeruginosa* (14). Intranasal vaccination with vaccine consists of *Salmonella* serovar *typhimurium* strain SL3261, an attenuated *aroA* mutant expressing the entire O antigen locus from *P.aeruginosa* 011 strain conferred complete protection in mice with challenge doses of five times the 50% lethal dose (LD50) of both cytotoxic and non-cytotoxic *P.aeruginosa* serogroup O11 strains (15).

Celery extract is a good immunostimulatory agents (16), it does offer a source of potassium, folic acid, carbohydrates, protein, dietary fiber, vitamin A, vitamin B complex, vitamin C, vitamin E, iron, magnesium, phosphorus and calcium (17) Little information are available on immune response stimulated by whole sonicated *Salmonella typhimurium* antigens (WSSAG) and celery extract against *Pseudomonas aeruginosa*, this study aimed to investigate the effect of WSSAGs and celery extract on the infection with *P.aeruginosa* in mice.

Materials and Methods

- **Bacterial isolates:** Virulent *Pseudomonas aeruginosa* and *Salmonella typhimurium* isolates were obtained from Zoonotic units of Vet. Med Coll. The biochemical tests were done to these isolates to confirm diagnosis according to Quinn, et al. (18).
- **Culture media:** Tryptic Soya agar, tryptic Soya broth and blood agar, these media were prepared according to production manuals
- **Whole bacterial sonicated antigen:** WSSAg prepared according to Mitove, et al. (19). Salmonellin prepared according to Saleh, (20).

- **Determination of the challenge dose:** The preparation of the bacterial suspension and the counting were made using McFarland's tubes according to procedure described by Baron, et al. (21).
- ***Apium greveolense* crude extract preparation:** The crude extract of celery was prepared according to Harborne, (22).
- **Experimental design:** Thirty five healthy white mice. Both sex aged between 6-8 weeks were randomly Divided into five groups and treated as following:
 1. 1st group (n=10) immunized with WSSAgs (0.5ml/lmg protein) S/C as primary dose followed by booster dose after (2) weeks.
 2. The 2nd group (n==10) administrated 0.5 ml of alcoholic celery extract (Concentration of protein 600 mg/kg BW) orally for (30) days and with same time were Treated as the 1st group. Skin test were done at day27 post-immunization, against salmoellin and at day 30 bloods was collected from five animals from each group after sacrificed then measure the Abs titers.
 3. 3rd group (n=5) was administrated orally alcoholic celery extract as the same dose and concentration as the"2nd group for (30) days. At 30 days post-immunization the 1st, 2nd, 3rd and 4th groups were Injected S/C with 0.5 ml of bacterial suspension containing IX10 CFU/ml of viable virulent *Pseudomonas aeruginosa*. The 5th group (n=5) injected S/C with 0.5ml of sterile PBS and considered as a control Negative group.

The animals of the experiment were sacrificed at the day 20 post-inoculation, and post-mortem examination was carried out to all sacrificed and dead animals samples of internal organs were taken for bacterial isolation and other for histopathological examination.thes samples were fixed in 10% neutral buffer formalin for 72 hrs. Tissue sections were prepared according to Luna, (23). Passive haemagglutination test was done according to Herbert (24).

Results

- **Delayed type hypersensitivity:** Twenty four hrs post test, the mean of skin thickness against salmonellin in animals treated with celery extract and immunized with WSSAgs (1.0+0.06) was higher than that of their value (0.83+-0.11) in animals Immunized with WSSAgs alone. At 48 hrs post test, the mean of skin Thickness was declined in 1st group (0.4+-0.06) and in 2nd group (0.5+-0.06) (Table.1).

Table (1) Showed the mean and standard error of different skin thickness at 27 days post-immunization

| No. | Group I | | Group II | |
|----------------|-----------|-----------|----------|----------|
| | 24 hrs | 48 hrs | 24 hrs | 48 hrs |
| 1 | 0.5 | 0.2 | 0.5 | 0.3 |
| 2 | 1 | 0.7 | 1.5 | 0.9 |
| 3 | 0.9 | 0.6 | 0.9 | 0.5 |
| 4 | 1 | 0.4 | 0.6 | 0.3 |
| 5 | 0.8 | 0.4 | 1 | 0.7 |
| Mean±SE | 0.83±0.11 | 0.41±0.06 | 1.0±0.06 | 0.5±0.06 |

- **Humoral immunity(the passive haemagglutination test):** The AB titer showed high value in animals treated with celery extract and immunized with WSSAgs(288+80.S) as compared with animals immunized with WSSAgs alone(128+45.2),(Table.2).

Table (2) Showed the mean and standard error of antibody titer at 30 days post-immunization

| No. | First group | Second group |
|----------|-------------|--------------|
| 1 | 128 | 156 |
| 2 | 64 | 128 |
| 3 | 256 | 512 |
| 4 | 64 | 256 |
| 5 | 64 | 128 |
| Mean ±SE | 288±80.5 | 128±45.2 |

- **Clinical finding and bacterial isolation:** The results revealed that all non-immunized and celery administration animals were died during 24-48 hrs post-inoculated with viable virulent *P.aeruginosa* with severe bacterial isolation from internal organs .Gross examination of the target organs of these animals showed severe congestion and edema. Immunized with or without celery extract administration infected animals showed good healthy during the course of the experiment. Post-mortem examination revealed no gross pathological lesion in their internal organs as well as no bacterial isolation.
- **Histopathological examination:** Immunized animals (first group):
 - Lung; Microscopic examination of the lung showed severe lymphocytic aggregation around the bronchiols and interstitial tissues (Fig. 3) as well as blood vessels.
 - Liver: lymphocytic cells aggregation around the central veins was seen together with kupffer cells proliferation (Fig. 4).
 - Spleen: Microscopic section revealed marked periarterial lymphocytic sheet proliferation with hyperplasia of the endothelial cells lining of central arteries and proliferation of mononuclear cells around the sinus form a cord like appearance (Fig. 5).
 - Kidney: there were mononuclear cells aggregation around blood vessels and sub epithelial layer of collecting tubules (Fig. 6).
 - The heart showed mild lymphocytic cells infiltration around blood vessels between muscle fiber.
 Immunized and pretreated animals (second group):
 - Lung: granulomatous lesions consisting mainly from aggregation of macrophages and lymphocytic cells scattered through lung parenchyma were reported in addition to mononuclear cells infiltration in the interalveolar septa(Fig. 1).
 - Liver: the most prominent lesion is mulifocal granulomatous lesion which consists of aggregation of macrophages lymphocyte and plasma cells around central veins and in portal areas as well as proliferation of kupffer cells(Fig.2).
 - Spleen: there was marked hyperplasia of white pulp which characterized by large multiple splenic corpuscles as well as mononuclear cells proliferation in red pulp.
 No significant lesions were reported in kidney and heart. Dead animals (in 3rd and 4th groups).

- Lung: Histopathological examination revealed severe congestion of blood vessels with inflammatory cells in their lumen and inflammatory cells infiltration mainly neutrophils and mononuclear cells in the interstitial tissue and lumen of the alveoli as well as thrombus in the blood vessels in addition to the destruction of the alveolar walls (Fig.7).
- Liver: the liver showed acute cellular degeneration which characterized by vacuolation of the cytoplasm of hepatic cells in addition to hepatocellular coagulative necrosis and aggregation of neutrophils and macrophages in the liver parenchyma (Fig. 8).
- Kidney: the pathological picture of the kidney characterized by thrombosis, severe neutrophils infiltration in the interstitial tissue and necrosis of the renal tubules (Fig. 9).
- Heart: there were inflammatory cells infiltration mainly neutrophils and mononuclear cells between the cardiac muscle and the lumen of congested blood.
- Spleen: The major changes were depletion of white pulp, fibrin deposition, neutrophils and macrophages infiltration in red pulp (Fig. 10)

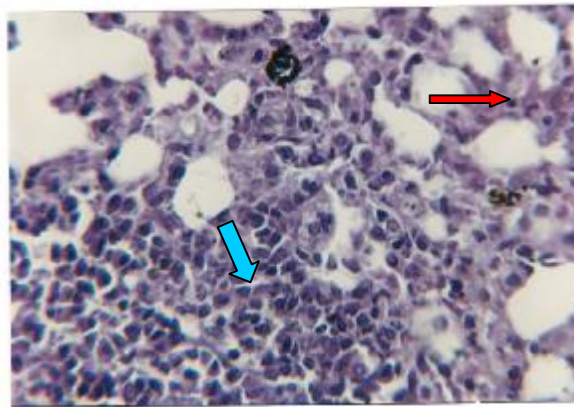


Fig. (1) Histopathological section in lung of immunized animal with WSSAg , 20 days post-challenge, showed macrophages aggregation scattered through lung parenchyma (↔) & mononuclear cell infiltration in interalveolar septa (→) .(H&E, X66).

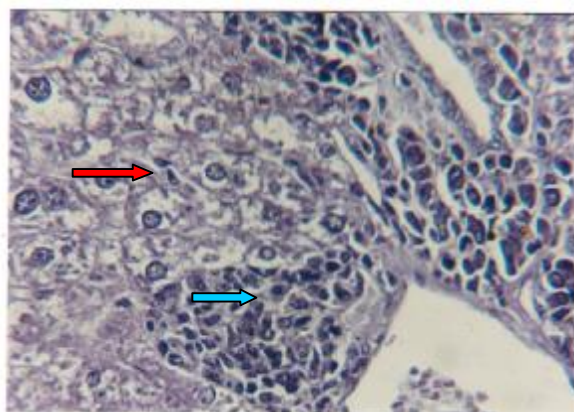


Fig (2) Histopathological section in liver of immunized animal with WSSAg, 20 days post-challenge, showed multifocal granulomatous lesion around central vein (↔) & portal area & proliferation of kupffer cell (→) . (H&E, X 123).

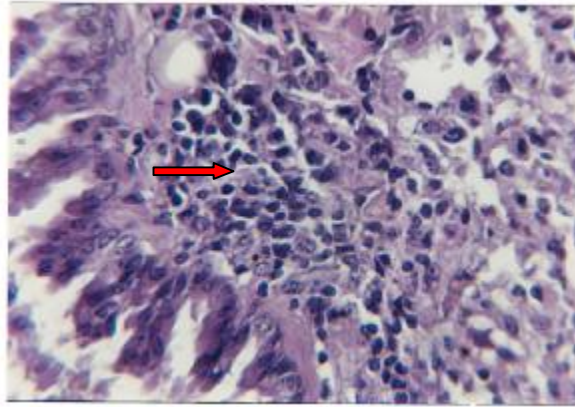


Fig. (3) Microscopic section in lung of pre-treated animal with celery and immunized with WSSAg, 20 days post-challenge ,showed lymphocytic aggregation in interstitial tissues & around bronchiols (→). (H&E, X 123).

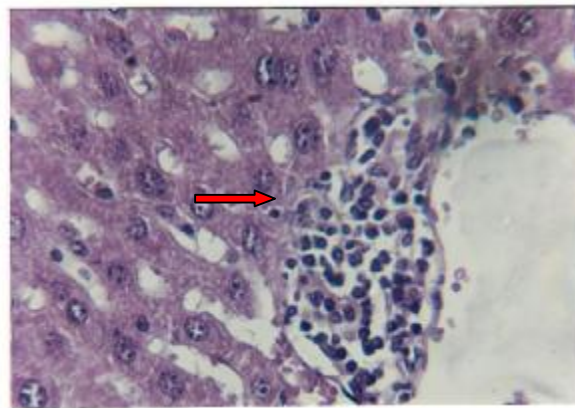


Fig. (4) Microscopic section in liver of pre-treated animal with celery and immunized with WSSAg, 20 days post-challenge ,showed lymphocytic cell aggregation around the central vein (→). (H&E, X 66).

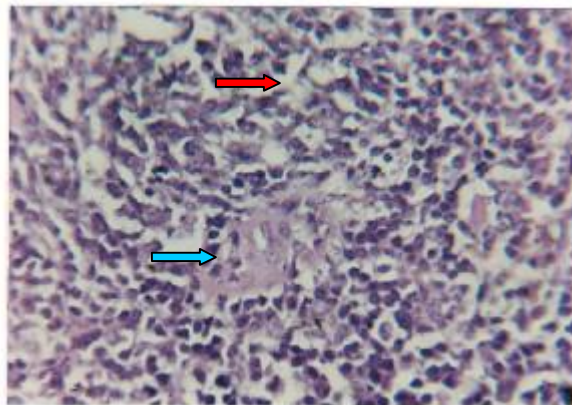


Fig. (5) Microscopic section in spleen of pre-treated animal with celery and immunized with WSSAg, 20 days post-challenge, showed lymphocytic sheet proliferation (→)with hyperplasia of endothelial cells lining of central arteries (→). (H&E, X66).

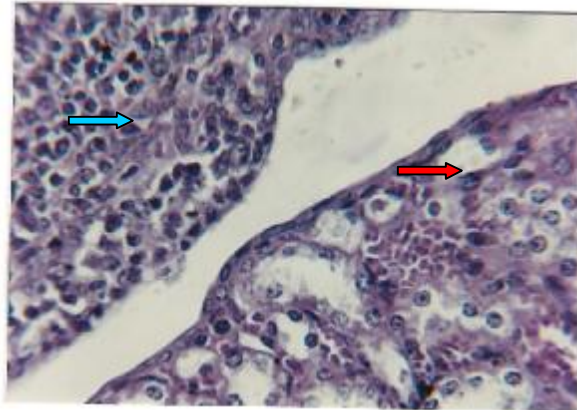


Fig. (6) Histopathological section in kidney of pre-treated animal with celery and immunized with WSSAg, 20 days post-challenge, showed mononuclear cell aggregation around blood vessel (→) & in sub epithelial layer of collection tubules (→) (H&E, X 66).

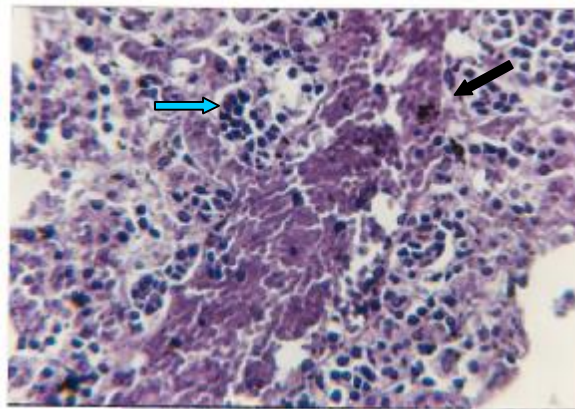


Fig. (7) Histopathological section in lung of one animal pre-treated with celery, 24 hrs post-challenge, showed severe congestion of blood vessel with inflammatory cell infiltration in the lumen (→) & infiltration of neutrophil & mononuclear cell in interstitial tissue (→) (H&E, X66).

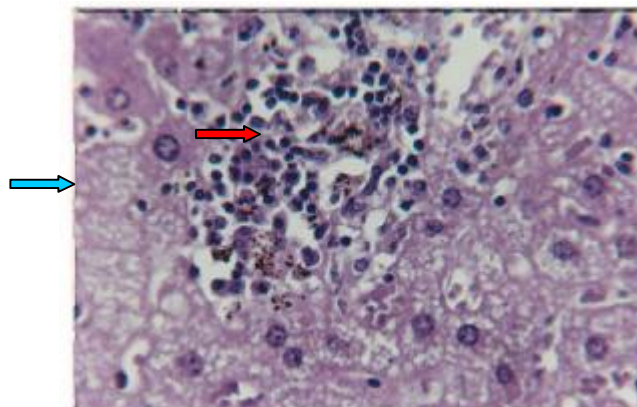


Fig. (8) Histopathological section in liver of one animal pre-treated with celery, 48 hrs post-challenge, showed neutrophil & macrophage aggregation in liver parenchyma (→) with hepatocyte coagulative necrosis (→) (H&E, X123).

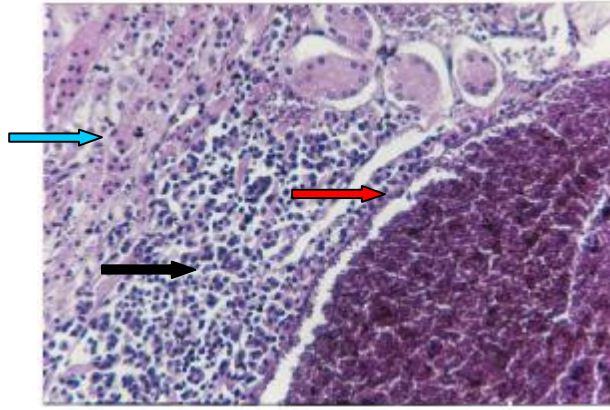


Fig. (9) Microscopic section in kidney of one animal pre-treated with celery, 24 hrs post-challenge, showed thrombosis in blood vessel I (→) & neutrophil infiltration in interstitial tissue (→) & necrosis of renal tubules (→). (H&E, X66).

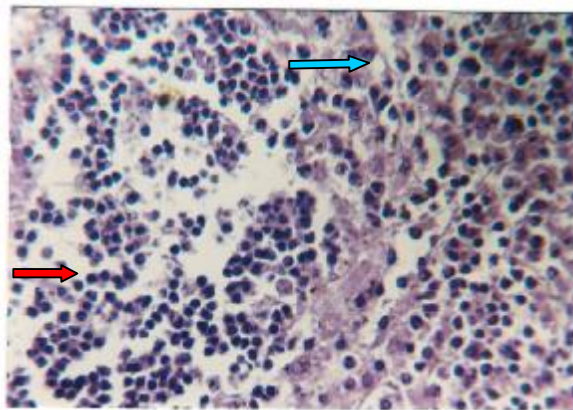


Fig. (10) Microscopic section in spleen of one animal pre-treated with celery, 48 hrs post-challenge, showed depletion in white pulp (→) with fibrin deposition (→) (H&E, X123).

Discussion

The results of immunological examination showed that the whole sonicated *salmonella typhimurium* antigens elicited cell mediated and humoral immune response which were a highly value in animals treated with alcoholic celery extract and immunized with WSSAgS. This findings were in agreement with that reported by Al-Khafaji(25).

Ramzi et al., (26) explained that the delayed type hypersensitivity, which is the principle pattern of cell mediated immunity, initiated by CD4+ T cells and direct cell cytotoxicity by CD8+ T cells. The WSSAgS which used in the present study contain all type of Salmonella antigens and these antigens induced DTH in immunized mouse, this observation supported the results of Mcorley et al.,(27) Who reported Tcell responses against several salmonella antigens including protein antigens, porins, flagellar epitope, pili and lipopolysaccharide.

According to our results, we suggested that WSSAgS were attached by residual macrophages and dendritic cells and this interaction lead to activate these cells to produce cluster of cytokines such as IL-1, IL-12. and TNF alpha as well as processing and presentation of WSSAgS and expressed small peptide of this antigen

to naive CD4+ T cells which proliferation and differentiation into T helper cells, this idea were agreement with observation provided by Murphy et al .,(28); Jains(29).

Our finding demonstrated that WSSAgs elicited DTH and humoral immune response and the celery extract augment these immune response, this results were similar to those reported by Al-khafaji (24) who showed that immunized mice with WSSAgs, developed DTH and antibody titer with high value in mice pretreated with celery extract and immunized with WSSAgs.

The death of all non-immunized and celery administration infected animals with severe bacterial isolation from internal organs compared with immunized and pretreated immunized infected animals which showed good healthy and no bacterial isolation from internal organs, indicated that the WSSAgs induced a good immune response against challenge with *Pseudomonas aeruginosa*. *Pseudomonas aeruginosa* has extra and intracellular stages in their course of infection (30), therefore, both cell mediated and humoral immune response play critical role in protection against this microorganism. The host defense mechanism against intracellular pathogens infection is due the phagocytosis of TNF-producing macrophages which are activated by IFN-gamma producing by NK cells and T helper cells (31). Activated macrophages become more bactericidal particularly through the production of nitric oxide, intermediate oxygen's reactive and have an increased ability to present bacterial antigen to CD4—T cells resulting in their differentiation into effectors cells and the sterile eradication of the M.O (32). According to this evidence, WSSAgs may be activated CD4+ and CD8+ T cells which may be might important role in non-specific resistance against *Pseudomonas aeruginosa*.

The lipopolysaccharide of *Pseudomonas aeruginosa* is very similar to LPS of enterobacteriaceae and O-polysaccharide is highly antigenic and highly heterogeneous and it is generally immunodominant (33) Jennifer et al.,(34) reported that oral or I/P administrated a live, attenuated *Salmonella* vaccine strain expressing the *P.aeruginosa* serogroup O110 antigen via the plasmid PLPS2 induced a robust *P aeruginosa* O-antigen specific immune response after vaccination .Toth et al.,(35) reported that vaccination with a *Salmonella enterica* serover Dublin strain expressing *P. aeruginosa* OPrI was able to protect about 10-20% of Cy-treated vaccinated mice from oral challenge with *P.aeruginosa*.

Results of pathological examination confirmed the results of bacterial and immunological examination, the presence of granulomatous lesion in the internal organs of immunized infected animals at day 20 post-challenge, despite the some M.O disseminated from the site of infection to internal organs and immune cytokines stimulated macrophages to sequester M.O forming granulomatous reaction which reduce intracellular bacterial multiplication and destroyed it. This evidence was agreed with (36) Who explained that the level of hepatic bacterial burden correlated with the level of granuloma formation? Granuloma may persist until the invasion intracellular pathogens are destroyed, and then the lesions will slowly resolve (37).

Lymphoid tissues hyperplasia with no granulomatous reaction in the internal organs of pretreated immunized animals indicated that celery extract augment the immune response in the immunized animals. carotene in celery acts as immunostimulatory and increase the rate of CD4+/CD8+ T cells in treated mice (38). Also the secondary metabolic products of celery extract such as sequiterpense, hemiterpense and coumarins stimulated the immune cells to produce IL-12 which play critical role in activation of NK cells, neutrophils, macrophages, T and B cells (39).

The death of non-immunized animal during the, first 24-48 hrs post -infection with severe acute suppurative lesion in the internal organs may be indicated that the

M.O rapidly disseminated from the site of inoculation to the internal organs and induce septic shock and multifailure organs. The invasion of *Pseudomonas aeruginosa* host cells particularly phagocytic cells, stimulated these cells to produce pro-inflammatory cytokines such as IL-1, IL-8, IL-6, TNFalpha and matrix metalloproteinase (40) and these cytokines enhanced the infiltration of neutrophils in the inflamed area and activated neutrophils elastase which lead to acute necrotized suppurative lesion in the infected organs (41).

References

1. Tortora, G. T.; Funke, B. R. & Case, C. L. (1999). Microbiology, an introduction 6th ed. Benjamin/ Cummings, P. 409-410.
2. Botzenhardt, K. & Doring, G. (1993). Ecology and Epidemiology of *Pseudomonas aeruginosa*. as an opportunistic pathogen. P. 1-6.
3. Frazier, W. C. & Wasthoff, D. C. (1989). Food microbiology. 3rd ed. P.49. Tata McGraw-Hill Publishing Company.
4. Madigan, M. T.; Martinko, J. M. & Parker, J. (2003). Brock biology of microorganisms, Loed. Prentice Hall, Upper Saddle River, NJ.
5. Mahenthalingam, E.; Campbell, M. E.; Foster, J.; Lam, J. S. & Speert, D. P. (2000). Random amplified polymorphic DNA typing OD *Pseudomonas aeruginosa* isolates recovered from patients with cystic fibrosis. J. Clin. Microbiol., 34: 1 129-1135.
6. Kendra, P.; Rumbaugh, J. A.; Griswold, B. & Iglewski, H. (1999). Contribution of Quorum sensing to the virulence of *Pseudomonas aeruginosa* to the in burn wound. Infect Immun., 43:5854-5867.
7. Gori, A.; Espinassa, F.; Deplano, A.; Nonhaff, C.; Nicolas, M. H. & Struelens, M. J. (1996). Comparison of pulsed-field electrophoresis and randomly amplified Klebsiellapneumoniae. Clin. Microbiol., 34: 2448-2453.
8. Pier, G. B. (1993). Acquired resistance to *Pseudomonas aeruginosa* IN: M. Campa, M. Bebdmelli and H. Friedman, Ed *Pseudomonas aeruginosa* as an opportunistic pathogen. Plenum Press, New York, P. 279-319.
9. Occherta, A. H.; Burrows, L. L. & Lam, J. S. (2000). Genetic of O-antigen biosynthesis in *Pseudomonas aeruginosa*. Microbiol. Mol. Biol. Rev., 63:523-533.
10. Goldberg, J. B. & Pier, G. B. (1996). *Pseudomonas aeruginosa* lipopolysaccharides and pathogenesis. Trends. Microbiol., 4:490-494.
11. Arora, S. S.; Wolfgang, M. C.; Lory, S. & Ramphal, R. (2005). Sequence polymorphism in the glycosylation island and flagellin of *Pseudomonas aeruginosa*. J. Bacteriol., 186:2115-222.
12. Bhattacharjee, A. K.; Opal, S. M.; Palard, J. E.; Drabick, J. J.; Taylor, R.; Cotton, A. & Cross, A. A. (1994). Affinity-purified of E.coli lipopolysaccharide specific IgG protects neuropenic rats against gram -negative bacterial sepsis. J. Infect. Dis., 170:622-629.
13. Holder, L. A. (2004). *Pseudomonas* vaccination and immunogeraphy: An Overview. J. Burn Care Rehabi., 22:311-320.
14. Pier, G. B. (1991). Promise and pitfalls of *Pseudomonas aeruginosa* lipopolysaccharide as a vaccine antigen. Carbohydr Res., 388: 2549-2556.
15. Antonin, D.; Jayasimha, R.; Katie, H.; Zaidi, J. G.; Gerald, B. P. & Joanna, B. G. (2007). Intranasal immunization with heterologously expressed polysaccharide protects against multiple *Pseudomonas aeruginosa* infection. Biol. Sci. Microbiol., 104: 4624-4629.

16. Tsi, D. & Tan, B. K. (1997). Lipid-lowering activity of aqueous celery extract and its fractions in hypercholesterolaemic rats and mice. *Med. Sci. Res.*, 25:673-675.
17. McCormik, D. B. (2004). Two interconnected B-vitamins-Riboflavin and Pyridoxine. *Physiol. Rev.*, 69: 1170-1198.
18. Quinn, P. J.; Carter, M. E.; Markey, B. & Carter, G. R. (2004). *Clinical Vet. Microbiol.* 6th ed. Mosby animp. WOLF, London, P. 261-267.
19. Mitove, I.; Denchen, V. & Linde, K. H. (1992). Humoral and cell mediated immunity in mice after immunization with *Salmonella typhimurium* antigen. *Immunol.*, 10:61-66.
20. Saleh, H. M. (1999). Immunological evaluation of the locally produced Brocillin in sheep infected with Brucilla and immunized with Rev-1 vaccines. Thesis. Vet. Med. Coll. Baghdad University.
21. Baron, E. J.; Gilman, J. B.; McSherry, B. J.; Baily, & Scotts. (1999). *Diagnostic Microbiol.* 9thed, Mosby. St. Louis. P. 761-766.
22. Harborne, J. B. (1984). *Phytochemical methods* 2nd ed. Chapman and Hall. London. P. 193.
23. Luna, L. G. (1968). *Manual of histology staining methods of the armed forces institute of pathology.* 3rded. Mcgrow-Hill, Book Company. New York.
24. Herbert, W. J. (1999). Passive heamagglutination with special reference with the tanned cell technique. Ch.20. In: Weir, D M. *Hand book of experimental immunology* 3rded 11. Cellular immunology. Blackwell Scientific Publication. 20:1-20.
25. Al-khafaji, M. A. (2008). The study of synergistic effect of whole *Salmonella* sonicated antigen and alcoholic celery extract on the immunopathological changes in mice infected with *Salmonella typhimurium*. MSc Thesis, Vet. Med. Coll. Baghdad University.
26. Ramzi, C.; Vinay, K. & Stanely, I. (1994). *Robbins pathological basis of disease*, 5thed, Philadelphia, London, Toronto, Montreal. P. 183-185.
27. McSorly, S. J.; Brad, T. C. & Maarc, K. (2002). Characterization of CD4+T cell responses during natural infection with *Salmonella typhimurium*. *Immunol. J.*, 164:986-993.
28. Murphy, E. A.; Bladwin, C. H.; Zoa, B. & Palant, M. T. (2001). Generation of cytotoxic T lymphocyte response using *Salmonella* antigen delivery system. *Mol. Microb.*, 4:21111-2114.
29. Jains, E. W. (1992). Determination of antibody against lipopolysaccharide and protein antigens of *Salmonella*. *J. Allergy. MMUN.*, 8:95-101.
30. Gregory, P. P.; Bringing, M. M.; Hatano, K.; Coleman, F. T.; Pier, G. B. & Goldberg, J. B. (2002). Constructional characterization of a live attenuated aro A delenom mutant of *Pseudomonas aeruginosa* as a caudicate intranasal vaccine. *Infect. Immun.*, 70:1507-1517.
31. Hsieh, C. S.; Macatonia, S. E; Tripp, S.; Ogarra, A. & Murphy, K. M. (1993). Development of Th1 CD4+Tcells through IL-12 produced by Listeria - induced macrophages. *Sci.*, 260:547-549.
32. Kaufmann, S. H. (1998). *Immunity to intracellular bacteria.* WE. Paul. ed. *Fundemental immunology* 1335. Lippincott -raven. Philadelphia.
33. Rocchetta, H. L.; Burrows, L. L. & Lam, J. S. (2000). Genetic of O-antigen biosynthesis in *Pseudomonas aeruginosa*. *Microhiol. Mol. Biol. Rev.*, 63:532-533.

34. Jennifer, M. S. & Joanna, B. G. (2008). Vaccination against *Pseudomonas aeruginosa* pneumonia in Immunocompromised mice. Clin. Vaccme. Immun., 15: 367-375.
35. Toth, A. F.; Schodel, M.; Massarrat, K.; Schmitt, H. & Sawa, T. (1994). Protection of immunosuppressed mice against translocation of *Pseudomonas aeruginosa* from gut by oral immunization with recombinant P.aeruginosa outer membrane protein I expressing Salmonella Dublin. Vaccvine., 12:1215-1221.
36. Monack, D. M. & Falkow, S. (2004). Development of *acquired immunity to Pseudomonas aeruginosa*. J. Med. Microbiol., 52: 453-459.
37. Adam, D. O. (1976). The glaucomatous inflammation response. Am J. Pathol., 84:164-191.
38. Robertson, M. J.; Speedie, M. K. & Wolf, T. J. (2002). Responses of human natural killer cells to cellular stimulatory factors: cytolytic activity and proliferation of NK cells. J. Exp. Med., 1175:1779-1782.
39. Stewart, B. W. (2004). Mechanism of apoptosis: Integration of genetic, biochemical and cellular indicators. J. Natl. Cancer Inst., 86:1286-1296.
40. Kolls, J. K. & Linden, A. (2004). Interleukin-17 family members and inflammation. Immunity., 21:467-476.
41. Lyczak, C. L.; Cannon, J. B. & Pier, G. B. (2000). Establishment of *Pseudomonas aeruginosa* infection. Lesions from a versatile opportunist. Microbiol. Infect., 2:101 -107.