Study of unusual clinical cases in Iraqi Farm Animals

M. J. Eesa
College of Veterinary Medicine\ Baghdad University

Abstract

During a period extended in between 1998 into 2009 years sixth unusual clinical cases, were register. These cases were brought to private clinic and clinic of Veterinary Medicine College, which includes the followings: large subcutaneous cyst located at the neck of a buffalo aged eight year were presented. The cyst developed as a small swelling and gradual increase in size in a period of 5-6 months. The cyst was treated surgically by complete evacuation, and packed with drain. The second cases**,** four year female buffalo, having a tissue mass above the carpal joint. This mass was a gradual increase in size, after parturition. The content was aspirated; the physical examination revealed that, this content is milk and the case as an ectopic mammary tissue. While the third cases, nine year old cross breed cow with history of having pregnant of seven month, showing decrease appetite, abnormal harsh cough and enlargement of larynx. After complete examination and investigation, there was sharp metallic needle inside the larynx..Laryngotomy was performed to remove of the foreign body. After fourteen days of operation, the animal returns to normal condition.. The four case, eight-year old cow with a history of having seven month pregnant was delivered dead large fetus with two heads and two necks. The post mortems revealed that the two necks connected at the first thoracic vertebrae and there was anasarca and ascitis. The last two cases represented by ameloblastoma with a history of mass close to the mandible of old local breed sheep was diagnostic. Ameloblastoma is present as a swelling and appear radiographically as radiolucences lesion and histopathologically composed of unilocular or multilocular cyst and cords of epithelium. It treated by complete lesion excision. And**,** the last one a case of osteoblastoma arising in the frontal bone of local breed sheep 5 year in aged was diagnostic. It present as swelling and appear radiographically as radio-opaque lesion, the histopathological is of a highly vascularized stroma with immature bone. This lesion is treated by complete excision.

دراسة لحالات سريرية نادرة في الحقول الحيوانية في العراق

محمد جواد عيسى
كلية الطب البيطري/ جامعة بغداد

الخلاصة

تم تسجيل ست حالات نادرة في العيادة الخاصة وكلية الطب البيطري خلال الفترة بين 1998–2009. الحالة الأولى وجود كيس كبير تحت الجلد في منطقة الرقبة لجاموسة عمرها 8سنوات حيث بدأ صغير ا ثم بلغ حجما كبيرا خلال 5–6 أشهر وتم علاجه بتفريغ السوائل ووضع فتيلة. أما الحالة الثانية فوجد ورم صغير فوق مفصل الركبة وازداد في الحجم بعد الولادة و إثناء سحب جزء من محتوياته وفحصه تبين انه حليب وشخصت الحالة بأنها نسيج من الضرع . أما الحالة الثالثة فكانت لبقرة عمرها 9 سنوات وحامل 7 أشهر لوحظ عليها فقدان بالشهية وتعاني من سعال خشن مع تضخم الحنجرة وبعد الفحص تبين وجود جسم معدني داخل الحنجرة وتم استخراجه بعملية فتح الحنجرة وقد عاد ت البقرة إلى الحالة الطبيعية بعد 14 يوما من العمليةوا إما الحالة الرابعة لبقرة عمرها

حوالي 8 سنوات وقد ولد ت عجلا بعد 7 أشهر تقريبا من الحمل برأسين ورقبتين وعند عمل الصفة التشريحية وجد تمفصل الرقبتين مع الفقرة الصدرية الأولى مع وجود استسقاء وحبن. أما الحالتين الأخيرتين تمثلت إحداهمابو جود ورم أرومة مينائية في الفك الأسفل لنعجة وأظهر ت الصورة الشعاعية وجود منطقة متعظمة بيضاء ومنطقة فاتحة وأظهر ت الصفة النسجية المرضية فجوات أحادية و متعددة مع بروز على شكل عمود من الظهارية وعولجت باستئصال الورم. وأما الحالة الأخيرة فوجد ورم أرومة عظمية فوق عظم الجبهة في نعجة عمرها 5سنوات واظهر الفحص الشعاعي وجود آفة متعظمة فاتحة اللون، أظهر ت الصفة النسجية المرضية وجود عظم غير ناضج وعولجت باستئصالالور م.

In buffaloes:
Large cyst of subcutaneous Tissue.
Introduction

Cysts are any closed cavity or sac, normal or abnormal lined by epithelium and especially one that contain a liquid or semiliquidd material. The ganglion cysts were diagnosed in a 4 month old male Afghan Hound. The subcutaneous ovoid cysts is located around the caudal right elbow joint and left ischiatic tuberosity and had abundant mucinous fluid and internal folding. The lesions recurred twice around the elbow joint after surgical removed(1). The other workers(2) describe that, the mean long diameter of the epidermal inclusion cyst in 13 patients were 3 cm. The common sites of this cysts were the planter surface of the metatarsal phalangeal joint and buttocks. Other workers (3), findings that intralesional formalin administration for treatment of subepiglottic cysts, in four year old horse may be a minimally invasive, economically suitable alternative to surgical treatments.

Materials and Methods

Buffalo aged eight years developed small swelling in a middle of right side of the neck and it was gradual increase in size during a period of 5-6 months**.** The swelling fluctuating was occupied the area between the ear and prescapular region (Fig.1 a and b) .Upon palpation of the tissue mass it became evident that they were in a subcutaneous tissue and the presence of clear fluid was confirmed by exploratory pincture, indicated that there is a cyst. The animals was sedated by xylazine hydrochloride at a dose 0.05 mg/kg.B.W intravenously, then under aseptic surgical technique, content was aspirated from the soft distal point of the swelling by using needle (G 18). Incision about 1 cm was made in the same site of aspiration to provide a complete evacuation of the content. The amount of aspirated fluid for about 4-4.5 liters The cavity was injected with 1% copper sulphate and repeated after 3 days. Then after that it's treated as an abscess. The opening was wide and washing by iodine and then packed by drain (gauze soaked with tincture iodine), and exchange every 48 hours until obliteration of cavity. Treatment was continued (1.5 month) to complete obliteration of cavity and retain to apparently normal after a period of about 3 months (Fig. 1, c).



Fig. (1) Large cyst on the right side of the neck in buffalo before treatment. a, (front view)(arrow ⟹), b (Lateral view))(arrow ⟹), and c, 3 months after treatment. (arrow ⟹)

Discussion

The subcutaneous swelling diagnostic in this study was a cyst according to palpation and appearance of fluid. It is treated by evacuation and injection with1% copper sulphate but this substance may be insufficient to destroy the epithelial cells which excreted fluid ,as well as large cavity of cyst .The cavity was contaminated by micro-organism so that, discharge turbid fluid exteriorized similar to abscess. Prolong using of drain, act as antimicrobial and stimulation of granulation tissue to obliteration of cavity. This procedure was required long time (1.5 months); this may be due to the large cavity, which needed long time to obliterate by granulation tissue. While (3),reported that the subepiglottic cyst(2cm in diameter) in a horse was treated with intralesional formalin administration following two injection, two weeks apart, the cyst was completely resolved with no evidence scarring or epiglottis deformity. The review of available literature, become evident that the large subcutaneous cyst is rare reported.

Ectopic mammary Tissue

Introduction

The mammary glands are derived from the sweat glands and that they are derived embryological by the invagination of ectodermic buds in to underlying mesoderm (4), (5), and (6). Ectopic mammary tissue has been reported in the wall of the teat canal in cows (4).Also ectopic mammary tissue of vulva was recorded in ten goats belonging to the Nubian and Syrian breeds (7).

Materials and Methods

Four years old female buffalo was referred to our private clinic with a history of having tissue mass above the carpal joint of right fore limb. The animal was of a normal condition. After parturition, there was a gradual increase in the size of the mass. Physical examination indicated subcutaneous tissue may be of the tissue mass. Aspiration of the mass under aseptic technique using a sterile syringe appeared that fluid white in color closely resembling milk in smell and consistency. This fluid was boiled and taste**.** Physical examination of the white fluid as well as tasting, indicated that, this fluid is milk. The mass diagnosed as a ectopic mammary tissue above the anterior aspect of carpal joint of the right fore limb in buffalo.

Discussion

The tissue mass reported in this study was ectopic mammary tissue as indicated by clinical and physical examination of white fluid obtained through aspiration from subcutaneous mass. This observation was supported by the owner, claimed that the mass was gradual increase in the size following parturition. This observation coincided with other worker in goats (7) whom they said that diagnosis ectopic mammary tissue in vulva of goats. Ectopic mammary tissue over the cranial aspect of carpal joint in buffalo was perhaps unavailable in literature.

In cow:
Sharp metallic foreign body on the larynx

Introduction

An unusual presentation of a firework penetration injury resulting in a sharp coiled metal foreign body traveling through a small entry wound in the neck and subsequently lodging itself in the tracheobronchial tree (8). Also (9) show the first bones has been reported to cause upper respiratory airway tract abscesses. However the migration through the entire pharyngeal wall ending in a superficial cervical abscess (10). Their removal is essential to prevent super infection, abscesses and perforation (11).

Materials and Methods

Nine year old cross breed cow, with a history of having pregnant of seven months. The clinical signs was a decrease in appetite, abnormal harsh cough, and received injection of systemic antibiotic for four days which repeated twice again without results. Physical examination revealed enlargement of larynx with swelling of surrounding tissue. The examination of the site by metal detector investigate presence of metallic foreign body, beside that radiography of the larynx to confirm the diagnosis (Fig. 2). The animal sedated by xylazine hydrochloride at a dose 0.05 mg/ kg B.W intramuscular. Local anesthesia at the site of operation is used. Laryngeotomy was performed to remove the foreign body. Under aseptic technique ventral mid-line cervical incision is done directly over the larynx in order to open thyrocricoid ligament. After reflexion of muscles laterally, small incision was induce in ligament then enter the finger inside lumen of larynx to detect the foreign body and removed by curved artery forceps which introduced and grasping metallic foreign body. The incision around opening in ligament was sutured as a routine manner, while the incision of ligament leaves without suture for spontaneous healing. Pencilliin-stresptounycin at a dose of 10,000 I.U,20mg/kg B.W intramuscular respectively was done for four days post operation. A skin suture was removed after 10 days post operation. Fourteen days later, the animal was in a good condition and the site of operation was free from complications beside that the incision of ligament was healed.

Fig. (2) Sharp metallic foreign body inside the larynx (arrow ⟹)

Discussion

Usually metallic foreign bodies were interred during swallow of food mainly into reticulum, but in a rare cases the sharp foreign bodies penetrated the mucosa of mouth, pharynx or esophagus which lodged within its or passes to the surrounding tissue with the subsequent cellulites or abscess formation. The presented case, this sharp foreign body within the bolus penetrated the ventral mucosal layer of esophagus at the level of dorsal aspect of larynx, and lodged in middle lumen of larynx. This was indicated by the direction of foreign body

radiographically. This observation coincided with (8), who said that sharp foreign body penetrated neck and logon in tracheobronchial tree. The enlargement of larynx and surrounding tissue may be due to contamination of foreign body, lead to inflammation of lumen of larynx and surrounding tissue. The subsequent of this inflammation caused abnormal harsh sound with the systemic reaction and decrease appetite. So that large doses of systemic antibiotic for along period without response. While after removal of source of infection and used systemic antibiotic gives good results.Altimately after fourteen days of operation the animals appeared in a good condition. This can be considered as a rare case.

A congenital abnormality of the calf

Introduction

The authors (12) describe that a 10 days old male Holstein dairy calf with orthopedic abnormalities was unable to stand but was alert with a suckle reflex. At necropsy, the calf showed multiple defects, including partial agenesis of the left rib plate, deformed left scapula, shortened left humerus, agenesis of the left kidney, artesia ani and scoliosis .While (13) showed that polydactyl in shami breed goat. At birth a male goat had an increase in the number of both hind leg digits. It has been concluded that polydactyl in goats is heritable. Other workers (14), mention that the outbreak of congenital chondrodysplasia in calves in south east Australia with no specific etiology could be determined. There is some evident that the cause of the deformities could be a manganese deficiency during fetal development. Also (15) showing lateral anophthalmia and deformation of the jaw such as brachygnathia superior and bilateral cleft.

Material and Methods

Eight-year old brown and white cow was referred to private clinic with a history of having, pregnant of seven month and signs of parturition was observed such as vaginal discharge, straining and restlessness. Examination and doing assessment for delivery because the fetus large in size, but exteriorized without cesarean section. Brown dead calf was aborted with two fully formed heads and two necks connected to the body just at the thoracic inlet, with first thoracic vertebrae, very large abdomen with anasarca and ascitis also seen (Fig.3).

Fig. (3) Two heads, two necks of seven months old calf

Discussion

Animals born with two head, a condition known as polycephy were register, while in this study a calf abortion with two heads and two necks was registed.The necks were connected at the thoracic inlet with first thoracic vertebrae. In this study the etiology was not determined due to the owner who is not mentioned sufficient information about the cow. In addition to that, unable to detection the antibody of several viral diseases, which may interfere with a congenital abnormality of pregnant infected cows. In literature, they reported that several factors may play an important role in this field. The Alkabane virus is the etiological agent of epizootic abortion and congenital arthogryposis. Besides hydranecephaly syndrome in cattle was noticed (16). Also (17) whom said that Akabane disease, an infections disorder causing congenital abnormalitie in calves. Beside that (18), describe that stillborn male calf from an embryo transfer recipient was carried out. Two normal heads were present on two necks which were fused at the shoulder is register in this study which believable that followed with the hypothesis due to atypical hatching, that is emergence of the blastocyst from the zona pellucida, may cause anomalous twinning.

In sheep:
Ameloblastoma of the Mandible

Introduction

Ameloblastoma mean amel (enamel) and blastos (germ) is a rare benign tumor of odontogenic epithelium much more commonly appearing in the mandible than the maxilla . Authors (19), mention that the ameloblastoma is the slow growing benign tumor of the jaw and patients usually present late after the tumor achieved considerable size to cause facial disfigurement. Other workers (20), reported that, male llama was presented because of rapidly enlarging mass on the right of the face. The mass did not interfere with mastication and did not appear the painful. Radiographs revealed a marked expansion of the right caudal face region with bone lysis involving the maxilla, nasal, lacrimal, zygomatic and palatine bone. Histopathplogically, the mass consisted of anastomosing cords and sheets of neoplastic odotogenic epithelium. The histological diagnosis was keratinizing ameloblastoma. On other hands ameloblastoma has also been identified in horse and cattle (21), (22), and in sheep (23).

Materials and Methods

Old local breed sheep with a history of having mass close to the mandible, this swelling was gradually increase in size at a period of about 4 month. The swelling was the result of an expansion of the cortical bone of the jaw and can be identified by palpation as hard and bony. It was associated with the difficult mastication and feeding. The radiography has been taken to evaluate the lesion and condition of adjacent structure. The animal was sedative by xylazine hydrochloride (0.05 mg/kg.B.W) intramuscularly and local anesthesia at the site of operation was applied. The site of operation was prepared for aseptic surgery. The tissue mass was bluntly dissection from the surrounding tissue. The incision was closed by routine manner. post operation care used penicillin- streptomycin 10000 l.U,20mg/kg B,W intramuscular respectively for four days. Biopsy was imbedded in 10% neutral buffered formalin for 72 hours, histopathlogical section was prepared routinely and stains by hematoxylin and eosin. The histopathological revealed that, there is a nest or cord of stratified squamous or columnar epithelium are embedded in a loose fibrous stroma. The tumor cells which are resemble ameloblastoma oriented perpendicular to basement membrane form bands that separate the tumor from stroma (Fig. 4,a). Hemorrhage and inflammatory cells infiltration, were seen in tumor stroma (Fig. 4,b). In other section there is a cystic variants, lining by stratified squamous or columnar epithelial cells which may be flat and regular or thrown, up into papillar projection(Fig.4,c).. Radiograph appeared as radiolucent lesion that may have either unilocular or multilocular appearance.Expansile bony mass was present at the right aspect of the mandible (Fig. 5).

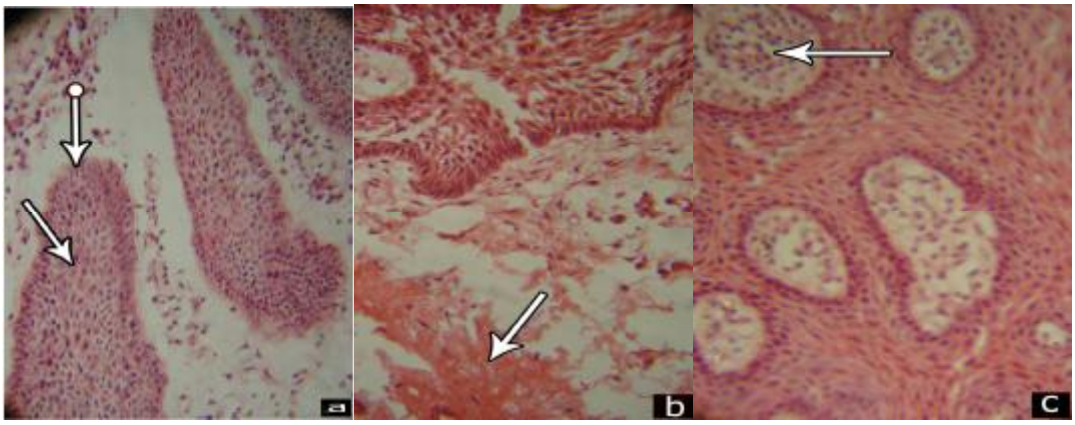

Fig. (4) Cord of stratified squamus or columnar epithelium (a) (arrow ⟹), tumor cells perpendicular to basement membrane (a) (arrow ⟹), hemorrhagic area (b)(arrow ⟹), cyst (c). (arrow) ⟹

Fig. (5) Ventro-dorsal (a), and lateral views (b) radiograph, show expansive bony mass of the right aspect of the mandible, and radiolucent lesion) (arrow ⟹)

Discussion

Amelablastoma is a benign tumor of bone especially mandible, but the tissue growth may be aggressive in the involved area. It can be progress to great size and cause displacement of teeth, loose teeth, facial asymmetry, malocclusion and pathologic fracture (19). In our case, the history, clinical signs, physical examination, radiography along with the tissue biopsy was diagnosed as ameloblastoma of mandible. Complete surgical excision was done in order to prevent invaded of other adjacent structure in addition to prevent recurrence. This agreement with other workers (19) and (24) whom said that , treatment of choice is surgical excision with wide free margin. Other treatments such as radiation or chemotherapy were not successful for treatment of ametoblastoma (25).

Osteoblastoma of the frontal bone

Introduction

Osteoblastomas account for approximately 3, 5% of all benign primary bone tumor (26). Osteoblastomas located on the surface of cortical bone, or periosteal ostoblastomas are extremely rare. An unusual case of periosteal osteoblastoma located in the frontal cranial bone (27). Although osteoblastomas may affect virtually any bone but the most common site is the vertebrae (28) .It usually located in the modularly cavity of the flat and long bones and periosteal location are rare (29). The radiation therapy or chemotherapy is controversial in the treatment of osteoblastoma. The treatment goal is complete surgical excision of the lesion (30) .

Materials and Methods

Local breed sheep 5 years in aged was preferred to our clinic with history of having growth near the base of horn. The owner observed that the growth was gradual increase in size for about 2 month ago. This growth reached diameter of about 10 cm. Clinical signs and by palpation of the growth tissue appearance of hard tissue was diagnostic. Radiograph has been taken to detect the lesion. It present as swelling and appear radiographically as radio-opaque, radiolucencies to poorly defined mixed lesion (Fig. 6). The site of operation was prepared aseptically. Under deep sedation of xylazine hydrochloride at a dose 0, 05 mg/B.W intramuscular and local anesthesia around the mass and blunt dissection was used to complete excision of growth; incision was closed as routine technique. Post operation penicillin streptomycin at a dose of 10,000 I.U, 20mg/kg B.W intramuscular respectively was used for four days. Ten days later, the sutures of skin were removed. The tissue biopsy was fixed in 10% neutral buffered formalin for 72 hours. Histopathologic section was prepared routinely and stains with hematoxylin and eosin. The histopathological revealed that, there is randomly inter-connecting trabeculae of woven bone that are preminently rimmed by osteoblast. The stroma surrounded the tumor bone is loose connective tissue that contain many dilated and congested capillaries(Fig.7,a). Osteoclast are present in fiber vascular connective tissue(Fig.7,b) Immature fibrous connective tissue with irregular direction and pleomorphic cells are also reported (Fig.7,c). Cartilage tissue was also seen.

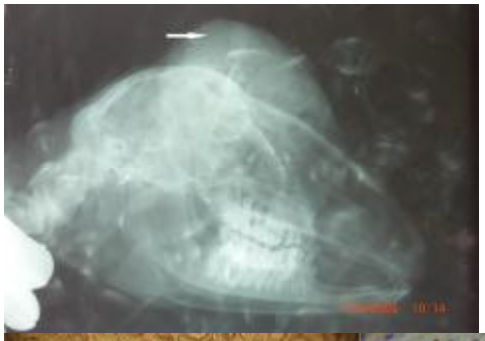

Fig. (6) Lateral view of sheep skull, show radio-opaque, closed to the frontal bone. (arrow ⇨)

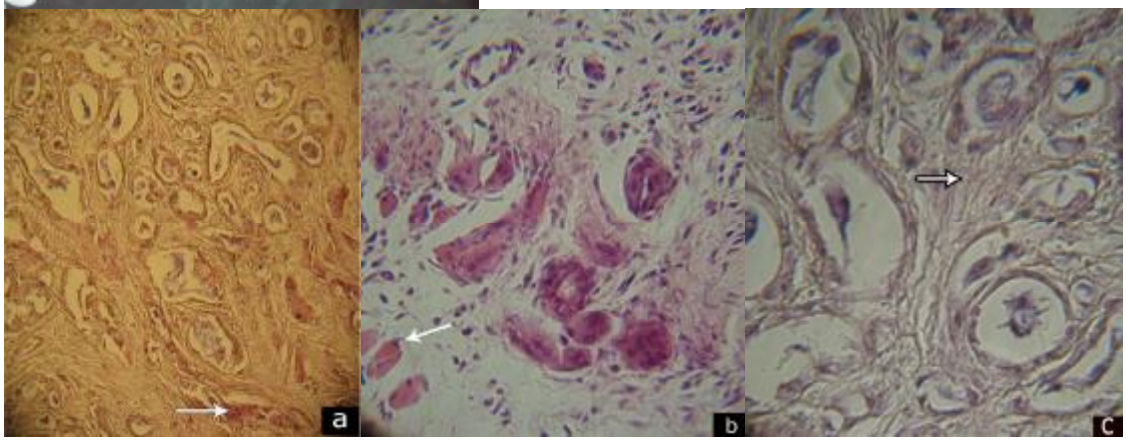

Fig. (7) Congested blood vessel (a), osteoclast (b), immature fibrous connective tissue with irregular direction and pleomorphic cells (c)

Discussion

Most of authors referred that osteoblastoma are most commonly found in the vertebral column, followed by the long bones, in particular the femur and tibia, and they are much less common in other bones (26), (31). While in this study the osteoblastoma found in the skull, which indicated by notices mention above. Complete surgical excision of all growth was exhibited good result. This observation coincides with other workers (27) whom said that the response of benign osteoblastoma to conservative surgical treatment is generally good.

References

1. Cho, K. O.; Park, N. Y.; Kang, M. I.; Umemura, K. & Itakura, C. (2000). Ganglion cysts in a Juvenile dog. Vet. Pathol., 37:340-343.
2. Jin, W.; Ryu, K. N.; Kim, G. Y.; Kim, H. C.; Lee, J. H. & Park, J. S. (2008). Sonographic findings of ruptured epidermal inclusion cysts in superficial soft tissue. J. Ultrasound Med., 27:171-176.
3. Dougherty, S. S. & Palmer, J. L. (2008). Use of intralesional formalin administration for treatment of a subepiglottic cyst in a horse. J. Am. Vet. Med. Assoc., 233(3):463-465.
4. Jubb, K. V. F.; Kenndy, P. C. & Palmer, N. (1985). Pathology of Domestic Animals Academic Press, Inc. New York, 3rd ed. P.378.
5. Banks, W. J. (1986). Applied Veterinary Histology . Williams and Wilkins, Baltimore , 2nd ed. P. 361-365.
6. Dyce, K. M.; Sack, W. O. & Weasing, C. J. G. (1987). Textbook of Veterinary Anatomy .W.B. Saunders company, Philadelphia. P. 367-369, 688-696.
7. Gameel, A. A.; Ramadan, R. O. & Dafalla, E. A. (1992). Ectopic mammary tissue in the vulva of goats. Zentraibl Veterinarmed A., 39 (6): 470-475.
8. Sarwar khan, M.; Kirkland, P. M. & kumar, R. (2002). Migrating foreign body in the tracheobronchial tree: an unusual case of firework penetrating neck injury. J. of laryngol and Otology., 116:2:148-149.
9. Nusbaum, A. O.; Som, R. M.; Rothschild, M. A. & Shugar, J. M. (1999). Recurrence of a deep neck infection: a clinical indication of an underlying congenital lesion. Arch Otolaryng of Head Neck Surg., 125:1379-1382.
10. Gertner, R.; Bar'el, E.; Fradis, M. & Podoshin, L. (1991). Unusual complication of an ingested foreign body. J laryngol Otol., 105:146-147.
11. Brinster, C. J.; Singhal, S.; Lee, L.; Marshall, M. B.; Kaiser, L. R. & Kucharczuk, J. C. (2004). Evolving options in the management of esophageal perforation. Ann Thorac Surg., 77:1475-1483.
12. Noh, D. H.; Jeong, W. I.; Jung, C. Y.; Chung, J. Y.; Jee, Y. H.; Do, S. H.; An, M. Y.; Kwon, O. D.; Williams, B. H. & Jeong, K. S. (2003). Multiple congenital malformation in a Holstein calf. Armed forces Institute of Pathology, Washington, DC, USA. J. Comp Pathol.,129 (4):313-315.
13. Al-Ani, F. K.; Hailat, N. Q. & Fathalla, M. A. (1997). Polydactyly in shami breed goals in Jordan. Small Rum. Res. 26 (1-2):177-179.
14. Cave, J. G.; Mclaren, P. J.; Whittaker, S. J.; Rast, L.; Stephens, A. & Parker, E. M. (2008). An extended outbreak of congenital chondrodysplasia in calves in south east Australia. Aust. Vet. J., 86 (4):130-135.
15. Bahr, C.; Kuiper, H. & Distl, O. (2003). Bilateral anophthalmia associated with further anomalies of the head in German Hostirn Calves. Dtsch Tierarztl Wochenschr., 110 (11): 454-456.
16. Kurogi, H.; Inaba,Y.; Takahashi, E.; Sato, K. & Sotoda, K. (1977). Congenital abnormalities in new born calves after inoculation of pregnant cows with Akabane Virus. Infect Immun.,17(2): 338-343.
17. Konno, S.; Moriwaki, M. & Nakagawa, M. (1982). Akabane disease in cattle :Congenital abnormalities caused by viral infection. Spontaneous disease. Vet. Pathol.,19 (3):246-266.
18. McGirr,W. J.; Partlow, G. D. & Fisher, K. R. S. (2005). Two-headed, two-necked conjoined twin calf with partial duplication of thoracoabdominal structures: Role of blastocyst hatching. The Anat. Rec., 217 (2):196-202.
19. Kahairi, A.; Ahmad, R. L.; Wan lslah, L. & Norra, H. (2008). Management of large mandibular ameloblastoma- a case report and literature reviews. Arch of Orofac Sci., 3(2): 52-55.

20. Bird, K. E.; Parker, J. E.; Andreasen, C. B.; Watrous, B. J. & Heidel, W. J. (2004). Keratinizing ameloblastoma in a 9-month- old llama (lama glama). J. Vet. Diagn. Invest., 16:89-92.
21. Barker, I. K. &Van Dreumel, A. A. (1985). The alimentary system. In: pathology of domestic animals , ed. Jubb KVF, kennedy,P.C.,Palmer. N, 3rd ed, Vol.2, P.1-237.Academic Press, New York, NY.
22. Head, K. W. (1990). Tumors of the alimentary tract. In:Tumour in domestic animals, ed. moulton JE,3rd ed. University of California Press, Berkeley, CA. P. 347-435.
23. Glastonbury, J. R. W. & Venning. C. M. (1998). Ameloblastoma in amerino sheep. Aust. Vet. J. 76:127-128.
24. Li, K. K.; Fabian, R. L. & Goodman, M. L. (1997). Malignant fibrous histocytoma after radiation for ameloblastoma of the maxilla. J. Oral Maxillofac Surg., 55:85-88.
25. Reichart, P. A.; Philipsen, H. P. & Sonner, S. (1995). Ameloblastoma: biological profile of 3677 cases. Eur. J. Cancer B Oral Oncol., 31B(2):86-99.
26. Unni, K. K. (1996). Benign osteoblastoma (giant osteid osteoma). In: unni, K.K, ed, Dahlins Bone tumors: General aspects and data on 11,087 cases. 5th ed. Philadelphia, Pa: Lippincott. Raven. P.133-142.
27. Lin, Y. C.; Commins, D. L.; Fedenko, A. N. & Pinsky, G. S. (2005). A rare case of periosteal osteoblastoma located in the frontal cranial bone. Arch. of Pathol. and Laboratory Med., 129(6):787-789.
28. Helliwell, T. R. (1999). Bone forming neoplasms arising within bone. In: Helliwell, T. R, ed. Pathology of Bone and Joint Neoplasms. Philadelphia, pa: Saunders. P.169-172.
29. Nakatani,T.; Yamamoto, T.; Akisue, T.; Marui, T.; Hitoro, T.; Kawamoto, T.; Nagira, K.; Fujita, I.; Matsumoto, K.; Yoshiya, S. & Kurosaka, M. (2004). Periosteal osteoblastoma of the distal femur. Skeletal Radiol., 33(2):107-111.
30. Aebi, M.; Robert, G. & Marek, S. (2007). Vertebral tumors. Hagerstwon, MD., Lippincott Williams and Wilkins. P. 172.
31. Kyung-Sub, M.; Shin, J.; Jae-Hyuk, L.; Tae-Young, J.; Soo-Han, K. & Sam-Suk, K. (2006). Benign osteoblastoma of the occipital bone: Case report and literature review. Neuropathol., 26(2): 141-146. April.