

## A Comparative Study Between Laparoscopic Complete and Subtotal Cholecystectomy in Goats

M. A. Alkhalani\*, M. J. Eesa\*\*, S. I. Saleh\*\* and A. A. Ajeel\*\*

\*Ministry of Agriculture

\*\* College of Veterinary Medicine\ University of Baghdad

### Summary

A comparison between laparoscopic complete and subtotal cholecystectomy was studied to find the deference in treating severe cholecystitis and to study the fate of the remaining part of the gallbladder in subtotal cholecystectomy. All experimental animals had induced cholecystitis by clipping the cystic duct for five days that was appeared enough for inducing cholecystitis in goats. 24 adult female goats were used in this study, which were divided randomly into two equal groups; complete laparoscopic cholecystectomy (group A) and subtotal laparoscopic cholecystectomy with cystic duct clipped only by titanium clips and leaved the cystic artery without clipping (group B) and Operations were performed under general anesthesia by using thiopental sodium at a dose of 15 mg\ Kg. B.W. intravenously to maintain the inhalation anesthesia by endotracheal tube with a mixture of halothane (1.5-2.5%) and oxygen (2-3%). The intraabdominal pressure with CO<sub>2</sub> was used successfully at a low pressure 8-10 mmHg, which was enough for good vision and good manipulation of laparoscopic instruments. The physiological activities and clinical symptoms which include heart rate, respiratory rate, temperature and return to the food and water were recorded at the same time of blood samples that took for liver function tests which were including; alkaline phosphates (ALP), alanine aminotransferase (ALT), aspartate aminotransferase (AST), total serum bilirubin and C- reactive protein were measured in different intervals; before operation (zero day) and at 1hr, 1<sup>st</sup>, 3<sup>rd</sup>, 5<sup>th</sup> and 7<sup>th</sup> postoperative day. The liver function tests showed a significant elevation (P<0.05) in alkaline phosphates (ALP) and in the total bilirubin values in group B (P> 0.05) comparison with group A and no significant difference in alanine aminotransferase (ALT), aspartate aminotransferase (AST) and C- reactive protein between experimental groups as well as time intervals. The biopsies were taken at the 3<sup>rd</sup>, 7<sup>th</sup> and 15<sup>th</sup> postoperative day for histopathological of the remaining part of gallbladder in group B which showed that cholecystectomies could be performed successfully with the subtotal technique, although the superior healing through little degeneration in the remaining part of the gallbladder and best in the healing stages.

دراسة مقارنة للإزالة الكاملة والجزئية للصفراء بالجراحة المنظارية في الماعز

ماجد عبد الرحمن الكيلاني\*، محمد جواد عيسى\*\*، سروة إبراهيم صالح\*\* وأياد إبراهيم\*\*

\*وزارة الزراعة

\*\*كلية الطب البيطري/ جامعة بغداد

### الخلاصة

تم إجراء دراسة مقارنة للإزالة الكاملة للصفراء منظارياً، والإزالة الجزئية المنظارية لها للوصول إلى الاختلافات في عمليات الإزالة المنظارية للصفراء لعلاج حالات الالتهاب الشديدة التي تصاب بها. كل حيوانات التجربة خضعت لعملية إحداث التهاب كيس الصفراء من خلال غلق قناة كيس الصفراء باستخدام مشابك التيتانيوم

منظاريًا وإجراء العملية باليوم الخامس بعد الغلق. استخدم في الدراسة أربعة وعشرون حيوانًا من المعز الإناث البالغة، والتي قسمت عشوائيًا لمجموعتين متساويتين، أُجريت للمجموعة الأولى عملية الإزالة الكاملة للصفراء منظاريًا، أما المجموعة الثانية فأُجريت لها عملية إزالة جزئية منظاريًا مع الإبقاء على شريان الصفراء وربط القناة فقط بمشابك التيتانيوم. أُجريت جميع العمليات الجراحية تحت التخدير العام باستخدام ثايوبنتال الصوديوم وبجرعة 15 ملغم لكل كيلوغرام من وزن الجسم للمساعدة في إدخال أنبوب الرغامي ذو الكفة لإدامة التخدير الاستنشاق العام باستعمال مزيج من الهالوثين بنسبة 1.5-2.5% والأوكسجين بنسبة 2-3%، وكان التخدير جيدًا لإتمام العمليات الجراحية في كافة حيوانات التجربة مع نسبة غير معنوية من الاختلاطات. استخدم غاز ثاني أكسيد الكربون بنجاح لنفخ البطن في المعز وتحت ضغط منخفض (8-10 ملم زئبق) حيث كان كافيًا لإعطاء رؤية جيدة لمنطقة العملية وللإزالة الجراحية الجيدة للأدوات الجراحية المنظارية أيضًا في عمليات الإزالة المنظارية للصفراء في الحيوانات. جرت متابعة الفعاليات الفسلجية والأعراض السريرية والتي تضمنت: سرعة القلب، والتنفس، ودرجة الحرارة، والعودة إلى الطعام والماء، في فترات متزامنة مع توقيات أخذ عينات الدم لقياس انزيمات الكبد والتي شملت الـ ALT, AST, ALP, C-reactive protein، ونسبة البليروبين الكلي ابتداءً من يوم العملية، والساعة الأولى بعد العملية، واليوم الأول والثالث والخامس والسابع بعد العملية الجراحية. أُخذت عينات من الجزء المتبقي من الصفراء في مجموعة الإزالة المنظارية الجزئية B في الأيام: الثالث والسابع والخامس عشر بعد العملية الجراحية لإجراء الدراسة النسجية المرضية. الفعاليات الفسلجية والملاحظات السريرية بينت نجاح عمليات إزالة الصفراء منظاريًا في المعز من خلال عدم ظهور اختلاطات مهمة في هذه الفعاليات قبل وبعد العمليات الجراحية لحيوانات التجربة. كما أن الإزالة المنظارية الجزئية لكيس الصفراء قد تمت بنجاح أيضًا مع عدم ظهور اختلاطات معنوية. وأظهرت نتائج فحوصات انزيمات الكبد زيادة في مستوى الـ ALP، والبليروبين الكلي في مجموعة B والتي أُجريت لحيواناتها إزالة منظارية جزئية للصفراء مع بقاء التجهيز الدموي بدون ربط مقارنة مع مجموعة A. ولم يظهر اختلاف معنوي في مستويات الـ ALT, AST, C-reactive protein بين المجموعتين، وفي التوقيات المتعددة أعلاه لكلا المجموعتين. أما نتائج الدراسة النسجية المرضية للجزء المتبقي من الصفراء في مجموعتي الإزالة المنظارية الجزئية B، فقد أظهرت إمكانية إجراء الجراحة المنظارية الجزئية بنجاح من خلال قلة النخر، والسرعة الجيدة في التئام الجزء المتبقي مما يبين أهمية استمرار التجهيز الدموي في مراحل الالتئام، حيث قل التتسك الكلي وقلل من إمكانية تحوله إلى مركز للالتئام والاختلاطات الغير مرغوب بها.

## Introduction

When conventional laparoscopic cholecystectomy is not possible, laparoscopic subtotal cholecystectomy is available and acceptable alternative to conversion to open cholecystectomy. It avoids the risk of major bile duct injury, and compared with studies of patients undergoing conversion to open cholecystectomy, demonstrates a reduce mortality as well as reduce incidence of wound infections and incision hernia. Laparoscopic subtotal cholecystectomy, performed when the cystic duct cannot be identified safely, consists of resecting the anterior wall of the gallbladder and removing all stones (1). Laparoscopic subtotal cholecystectomy introduction can prevent misidentification of the bile duct, whereby injury to the bile duct or other organs is avoided. For these reasons, they attribute the decreased incidences of bile duct injury and conversions to open surgery at their institution, to the introduction of laparoscopic subtotal cholecystectomy (2). Although the laparoscopic subtotal cholecystectomy is commonly performed today, and often substitute for the conversion of conventional

laparoscopic cholecystectomy to open cholecystectomy, but the fate of the remaining posterior part of the gallbladder which is attached to the liver is still unknown by researchers; whether is it showed fibrosis or necrosis and becomes focus of infection, and no information about its impact on patient's health was found. We were Compared two surgical techniques in laparoscopic cholecystectomy which were completed in the first and subtotal cholecystectomy in the second to find the deference in the two technique with best postoperative results and to follow the fate of remaining part of cholecystectomized gallbladder macroscopically, clinically and histopathologically at different periods postoperatively.

### Materials and Methods

Twenty- four healthy adult Indagenus female goats, aged between 2.5 to 4 years, and weight (37 to 45 kg.) were used. The animals were divided randomly into two equal groups; A and B, each group subdivided into three subgroups according to the period of 3, 7 and 15 days postoperatively to take biopsies for histopathological examination. The animals were fasted for 36 hours of food and 12 hours water preoperatively. The treated animals were put under observation postoperatively. In all 24 goats, Cholecystitis was induced experimentally by laparoscopic clipping of cystic duct by titanium clips after identification. At the 5<sup>th</sup> day post inducing cholecystitis the animals performed laparoscopic subtotal cholecystectomy. Laparoscopic inspection and histopathological examination used as parameters. Thiopental sodium at a dose of 25 mg/kg B.W. intravenously was used to facilitate introducing endotracheal tube for inhalation anesthesia, which is the method of choice for maintaining anesthesia for prolonged procedure (3). Pneumoperitoneum with CO<sub>2</sub> (8-10 mmHg) was performed in all experimental animals. The subtotal cholecystectomy was begun by clipping the cystic duct and cystic artery in group A, and cystic duct in group B. Then the gall bladder was punctured at the fundus with monopolar electrocautery hook and the suction-irrigation apparatus was used to evacuate the contents. The gallbladder was pulled cranially and laterally, Calot's triangle and its structure (cystic duct, cystic artery and inferior border of the liver) were put under tension. Subtotal cholecystectomy was performed by leaving the posterior wall of the gall bladder which attached to the liver intact. The incision was performed adjacent to the liver and carried out around to the posterior wall of the gallbladder both incisions were meeting medially (Fig.1). Any bleeding at the margin borders was coagulated with electrocautery. The mucosa of remnant part of gallbladder was cauterized with spatula to destruct the mucosa and to prevent any secretions (Fig. 2).

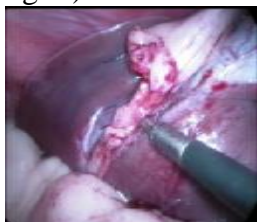

Fig.(1) Gall bladder dissection started from the neck upward, in subtotal Cholecystectomy

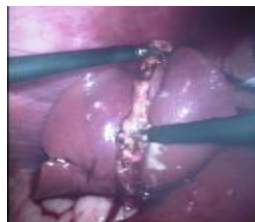

Fig. (2) mucosal cauterization by hook

Food and water were free to record the time of returned to eat and drink post operation. Penicillin streptomycin in a dose 20000 I.U., and 10 mg/Kg B.W. respectively, was administered intramuscularly for four days post-operatively. Rectal temperature, respiratory and heart rate were monitored once daily for seven days postoperatively. Skin sutures were removed ten days post-operatively. Biopsies about 1 square cm<sup>2</sup> were taken laparoscopically at the third, seventh and fifteenth day postoperatively. The specimens were fixed in 10% neutral buffered formalin, then routinely processed and embedded in paraffin which were cut at (5- 6) microns and

stained by hematoxyline and eosin stain (4, 5) and they were examined under light microscope. The operation periods were depended on the severity of the cholecystitis and other complications occurred during the operations, such as bleeding and visceral injury. The respiratory rate, heart rate and temperature were recorded along the length of the operation. The abdominal cavity of experimental animals was inspected laparoscopically at 3<sup>rd</sup>, 7<sup>th</sup> and 15<sup>th</sup> day postoperatively according to the period of subgroups in groups A and B to evaluate any pathological changes and to take biopsies for histopathological study.

### **Results**

In inducing cholecystitis the macroscopic and microscopic result showed that five days period was enough for inducing cholecystitis because of the severity of histopathological changes at the 7<sup>th</sup> day period which was showed severe necrosis, so the fifth day period was depended. The operation time was ranged between 50- 85 minutes (mean 67 min.); while the range of operative time for completes laparoscopic cholecystectomy were 25- 45 minutes (mean 35min.). The treated animals had returned to eat and drink within a short time post recovery from anesthesia and with normal activity, which had indicated less postoperative pain. No significant changes occurred in physiological activities post operations; the respiratory rate, heart rate and temperature were within normal rate. Two animals (one of each group) of twenty- four animals (8.3%) had shown pain few days postoperatively. This might be due to the adhesion occurred between gallbladder and adjacent omentum and viscera because of the experimentally induced cholecystitis which required long time during surgery for gallbladder identification and separation from the liver bed, that may lead to damage and post operative pain. Pneumoperitoneum with CO<sub>2</sub> was successfully produced in experimental goats with minimal complications such as that occurred at the beginning of the experiment that some cases showed pneumo-omentum at the onset of the insufflation (4 animals). At the 3<sup>rd</sup> postoperative day, mild adhesions observed between the omentum and the site of the operation, while at the 7<sup>th</sup> post operative day five animals (one from group A and two from group B) had showed severe adhesions (12.5%). Mostly the adhesions were circumscribed to the operation site and did not occur in other regions in the abdominal cavity. The incidence of adhesions occurred in this study was low in comparison with the rate of occurrence in open surgery and this result comes in agreement with result of adhesion in laparoscopic surgery. These adhesions may be a result of the liver bed damage in dissection of cystic duct, cystic artery and omentum which attached to the inflamed gallbladder. In cases where bleeding or injury to the liver bed occurred, adhesion formation occurred. In induced cholecystitis the microscopic findings at the fifth day post clipping showed congested blood vessels, mononuclear cells infiltration around the vessels, between muscle fibers (Fig.1). The histopathological findings were as following according to the period of biopsy: At the 3<sup>rd</sup> postoperative day microscopic picture the microscopic sections in group (B) showed neutrophils infiltration in the stroma, as well as neutrophils aggregation in dilated blood vessel (Fig.2). Neutrophils infiltration appeared in their lumen, around them, and around mucosal gland. There were network of fibrin deposition with neutrophils infiltration and fragmentation of muscle fibers in another section (Fig.3). There were congested blood vessels and a network of fibrin in group B, this is a sign of progress in healing. The histopathological examination in group (B) at the 7<sup>th</sup> postoperative day showed atrophy of the epithelial mucosa which become rounded and neutrophils infiltration in the sub epithelial layer and there was fibrin deposition in the stroma (Fig. 4 and 5). Dilated mucosal glands with inflammatory cells infiltrated in the connective tissue which found around glands. There was neutrophils aggregation in necrotized stroma. The epithelial layer become rounded and lined by cuboids or simple cells with inflammatory cells infiltration in the lamina propria. There was necrosis of mucosal gland, granulation tissue proliferation and fibrin deposition. At the 15<sup>th</sup> day the lesions in group (B) were characterized by severe proliferation of fibrous connective tissue, which was highly cellular with mononuclear cell infiltration.

The fibrous connective tissue was surrounding necrotized mucosal gland. In other section, there was mature fibrous connective tissue in the stroma, characterized by regular fibers direction with less fibroblast cells and more collagen deposition (Fig.6). The healing appeared in advance phases in group B at the fifteenth day postoperatively and this was evident from the proliferation of connective tissue, which was characterized by regular collagen fibers deposition and less fibroblast cells. These findings show that the survival of blood supply to the remaining piece of the gallbladder had helped in shortening the healing time. The results showed a significant ( $P < 0.05$ ) decline in the mean of the values of alkaline phosphatase (ALP) in group A for all time periods, compared with group B (Table, 1). In another way the liver injury which occurred during the cystic duct and artery dissection may be the cause of this increase in ALP titers. There were no significant differences in the mean values of the AST between the different groups A and B and in the different periods (Table, 2). And there was no significant difference at the level of ( $P > 0.05$ ) in the mean values of ALT between the different groups A and B and in different periods also (Table, 3). The results also showed a decline in the values of the mean of total bilirubin on the 5<sup>th</sup> and 7<sup>th</sup> day significantly in the level of ( $P > 0.05$ ) compared with other time periods in groups A and B (Table, 4). The results showed no significant differences ( $P > 0.05$ ) in C-reactive protein between different groups of different intervals in the number of negative and positive samples (Table, 5).

**Table (1) Alkaline phosphates (U/L) (ALP)**

Group \ Time	Zero day	1 hrs.	1st. day	3rd. day	5th. day	7th. Day
A	49.7 ± 4.6 b	46.7 ± 5.2 b	52.5 ± 4.2 b	55.3 ± 4.9 a	51.2 ± 4.1 a	49.1 ± 4.2 B
B	70.7 ± 9.6 a	69.6 ± 8.8 a	65.7 ± 5.7 a	66.8 ± 6.2 a	63.1 ± 6.8 a	67.5 ± 8.3 A

Different small letters vertically refers to the existence of significant differences ( $P < 0.05$ ).

**Table (2) Aspartate aminotransferase (GOT) (AST) (U/L)**

Group \ Time	Zero day	1hrs.	1 <sup>st</sup> .day	3 <sup>rd</sup> . day	5 <sup>th</sup> . day	7 <sup>th</sup> .day
A	127.6 ±14.0	138.5 ±15.4	132.7 ±14.2	131.7 ±15.6	126.7 ±15.8	129.4 ±14.3
B	117.25 ± 2.8	127.25 ±17.72	121.08 ±13.37	122.16 ±11.92	116.83 ±11.33	120.5 ±13.28

There are no significant differences in the mean value between the different groups A and B and in the different periods.

**Table (3) Alanine aminotransferase (ALT) (GPT) (U/L)**

Group \ Time	Zero day	1hrs.	1 <sup>st</sup> .day	3 <sup>rd</sup> . day	5 <sup>th</sup> . day	7 <sup>th</sup> .day
A	53.4 ±2.5	54.1 ±3.2	56.8 ±3.1	56.9 ±3.1	56.5 ±2.7	54.2 ±2.7
B	50.8 ± 2.8	51.3 ± 2.6	53.2 ±2.9	57.2 ± 3.3	53.2 ±2.0	50.8 ±2.2

There are no significant differences in the mean values between the different groups A, B in the different periods.

**Table (4) Total bilirubin (mg/dl)**

Time Group	Zero day	1hrs.	1 <sup>st</sup> .day	3 <sup>rd</sup> . day	5 <sup>th</sup> . day	7 <sup>th</sup> .day
A	0.011 ±0.002 B c	0.022 ±0.003 A b	0.029 ±0.005 A b	0.026 ±0.002 A b	0.023 ±0.003 A b	0.017 ±0.002 B a
B	0.029 ± 0.005 A a	0.033 ± 0.007 A a	0.039 ±0.007 A a	0.034 ± 0.005 A a	0.028 ±0.005 B a	0.022 ±0.002 B a

- \* Different small letters vertically refers to the existence of significant differences  $P < 0.05$ .
- \* Similar small letters vertically refers to the absence of significant differences  $P > 0.05$ .
- \* Different capital letters horizontally refers to the existence of significant differences.

**Table (5) C - reactive protein**

The Time Group	Total No.	Zerody		1hrs.		1 <sup>st</sup> .day		3 <sup>rd</sup> .day		5 <sup>th</sup> .Day		7 <sup>th</sup> .day	
		+	-	+	-	+	-	+	-	+	-	+	-
A	12	4	8	4	8	6	6	3	9	2	10	1	11
B	12	3	9	6	6	11	1	7	5	3	9	2	10

There is absence of significant differences in the mean values between the different groups A, B and C and in different periods.

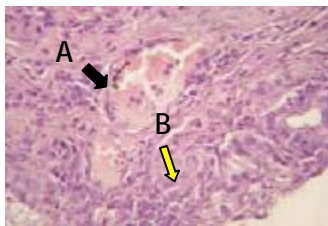


Fig.(1) Induced cholecystitis group, 5 days Pos. clipping shows congested blood vessel with neutrophils in their lumen (A) and neutrophils infiltration in the subepithelial layer and between mucosal gland (B)(H&E 40X).

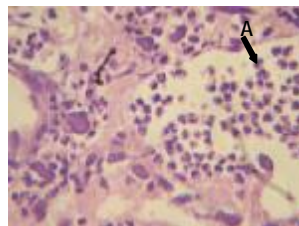


Fig.(4) Group B, three days postoperation show neutrophils aggregation in dilated blood vessel (A). (H&E40X)

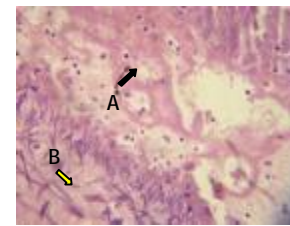


Fig.(5) Group B, three days p. op. there is fibrin network deposition with neutrophils infiltration (A), fragmented muscle fibers (B). (H&E

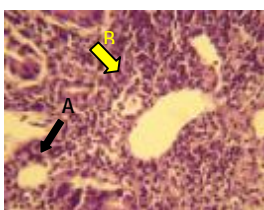

Fig.(8) Group B, seven days post op. shows atrophy of epithelial mucosa which become rounded (A), with neutrophils infiltration in subepithelial layer(B) (H&E 40 X).

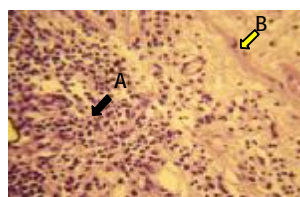

Fig.(9) Group B, seven days post op. there is neutrophils infiltration in subepithelial layer (A), and fibrin deposition in Stroma (B). (H&E 20 X).

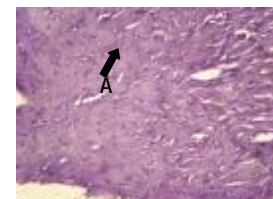


Fig.(11) Group B, fifteen days post op. there is mature fibrous connective tissue in the stroma (A). (H&E 20X).

## Discussion

Pneumo-omentum at the onset of the insufflation coincided with researchers (6); which found that when Veress needle placed blindly, there is a potential for its misplacement in the subcutaneous space, vascular space, viscera, omentum and mesentery or retroperitoneal. These complications could occur in human as mentioned by researchers (7) who found that the overall incidence of operative complications was 22 from 350 (6.29%), among them three of pneumo-omentum were related to

inappropriate CO<sub>2</sub> insufflation. The low intra-abdominal pressure used in present study (8-10 mm Hg) was enough for a good manipulation of the instruments in the abdominal cavity and allowed a good operation field and visualization. These results were consistent with what was reported by some researches (8), about the higher intra-abdominal pressure which may be incompatible at some degree with the respiration and vascular blood flow. Also using low-pressure pneumoperitoneum (7mmHg) had been shown to minimize adverse hemodynamic effects on hepatic portal blood flow and hepatic function due to the harmful effects of elevated intraabdominal pressure, it is recommended that the lowest possible intraabdominal pressure be used, allowing adequate exposure of the operative field, rather than a standard pressure (13-15 mmHg). This was consistent with findings (9) that the low-pressure technique could be employed in the majority of patients subjected to laparoscopic cholecystectomy and reducing the pressure of the pneumoperitoneum to (7 mmHg) tended to produce lower incidence of postoperative shoulder-tip pain in human. It may also prevent mortality due to CO<sub>2</sub> embolism (10). The operation time agreed with researchers (11) whom remembered that the median operating time for laparoscopic subtotal cholecystectomy was 92.5 min. (range, 50-140 min). And this result consistent with some researches (12), when they recorded the median operation time of laparoscopic subtotal cholecystectomy which was a 65.5± 15.2 minute. Similar results of the postoperative pain achieved by researchers (13), that visceral pain is predominant, especially during the first hours after the intervention, despite of laparoscopic surgery is associated with less postoperative wound pain and fewer complications than open procedures (2). Similar results of increase in ALP titers were recorded (14), as consequences hepatocytes pathology; cholecystitis should be regarded as an important additional cause of reactive hepatitis. These findings also agree with research (15) that showed gall stones and cholecystitis had abnormal liver histology, and the most sensitive indicator of clinically important liver pathology was a raised serum alkaline phosphates value, and liver changes associated with cholecystitis. Also they support the inference that reactive hepatitis might be the result of a recent episode of common bile duct obstruction in human. As a common disease, cholecystitis should be regarded as an important additional cause, so an obstructive pattern with raised alkaline phosphates values was the most frequent abnormality. Elevations of AST and ALT activities are associated with hepatocellular damage from any cause (16). While other (17) reported that ALT enzyme is not present in large enough amount in liver cells of horse, ruminant and pig. Increasing in total bilirubin could be a result of many causes, that hemolytic disease and hepatobiliary disease are the most common causes of hyperbilirubinemia (16). Bile salts that are reabsorbed by the enterohepatic circulation increase plasma bilirubin, which under normal levels, is excreted in the urine. However, when bile ducts are damaged, bilirubin accumulates in blood and can be used as an indicator of hepatic disease (18). Although there were difference in bilirubin values between all groups in this study, but these values were in the normal range. In a study on Nubian goats (19); they found that the values of total bilirubin were 0.55 to 1.86 in different experimental groups which treated with chemotherapy. This explains that the bilirubin values in present study were less than those of other study (19), which proved that they were in the normal range. This also supported by others (16) that a test result of 3.1 mg/dl was significantly elevated over values typical for his experimental animals, and it was interpreted to represent a real elevation. The abdominal cavity of experimental animals was inspected laparoscopically at 3<sup>rd</sup>, 7<sup>th</sup> and 15<sup>th</sup> day postoperatively to evaluate any pathological changes and to take biopsies for histopathological study. At the 3<sup>rd</sup> postoperative day, mild adhesions observed between the omentum and the site of the

operation, while at the 7<sup>th</sup> post operative day three animals (one from group A, and two from group B) had showed severe adhesions (12.5%). Mostly the adhesions were circumscribed to the operation site and did not occur in other regions in the abdominal cavity. The incidence of adhesions occurred in this study was low in comparison with the rate of occurrence in open surgery and this result comes in agreement with result of adhesion in laparoscopic surgery. These adhesions may be a result of the liver bed damage in dissection of cystic duct, cystic artery and omentum which attached to the inflamed gallbladder. Others (20) had found the same result about adhesions that the laparoscopic cholecystectomy has reduced rate of adhesion formation when compared with the open technique. This was supported by a study (21) that conventional cholecystectomy had seven times more adhesions than laparoscopic cholecystectomy, and far distant adhesions developed also. This observation is agree with another study (21) in which they found that liver bed adhesions developed in six of twenty laparoscopic cholecystectomies dogs, in which far adhesions developed only at the trocar site beyond the xyphoid and at the 5-mm trocar sites, and no other far adhesion was detected. In the laparoscopic cholecystectomy group, adhesions were localized only to the liver bed. Only two columnar adhesions were found, and they were localized in the epigastrium at the site of the operative trocar. Complications such as bleeding or injury to the liver substance during laparoscopic cholecystectomy can enhance adhesion formation. This observation was consistent with (22,23) and (23) that minimal manipulation of visceral organs distant from the operative site, reduce the formation of adhesions at these sites. In the cases where bleeding or injury to the liver bed occurred, adhesion formation occurred. At the 7<sup>th</sup> postoperative day, two from group B) had shown a sac contained serous fluid in the site of persistent part of gallbladder; this may be due to secretion from mucosa which may be still intact although it was coagulated with electrocautery, so the remaining gallbladder must be coagulated completely. This was also confirmed by (24) who recorded that destruction of the residual gallbladder mucosa with electro coagulation was optional. Also may be as a result of bile leak from bile ducts that in some cases enter from the liver into the gallbladder directly, this observation was supported by (25), who found that bile ductules in sheep and goat sometimes entering the gall bladder from the liver directly through its attached wall. And so found (26) that the biliary leak may be a minor one arising from small, accessory bile duct and clinically significant and that lesions of the accessory bile duct are the commonest cause of postoperative complication. In a study (27) on the laparoscopic cholecystectomy in dog, also found that laparoscopic surgery did not affect physiological parameters, except that the body temperature had temporarily decreased after operation and then returned to normal. The importance of blood supply to the inflammatory area is supported by researcher (28), that the circulatory disturbances could play a role in the pathogenesis of acute acalculous cholecystitis. The monocyte–macrophage system and neutrophils granulocyte activation are highly important in the inflammatory process. And the neutrophils granulocytes represent the earliest immune cell flow to the site of inflammation, and the terminal phase of tissue repair is fibrosis in the liver bed, which was well demonstrated by the histological investigation (29). The presence of granulation tissue formation and fibrous connective tissue in group B at the 7<sup>th</sup> day is supported in a study (30), that in case of blood supply presence, the expensive tissue defect becomes filled with granulation tissue, and in such injuries the repair filled by connective tissue replacement. While the presence of proteineus material may be due to interruption of blood supply in group A which led to red blood cells hemolysis and resulting in severe necrosis.

## **References**

1. Philips, J. A. E.; Lawes, D. A.; Cook, A. J.; Arulampalam, T. H.; Zaborsky, A.; Menzies, D. & Motson, R. W. (2008). The use of LSC for complicated cholelithiasis. *Surg. Endosc.*, 22: 1697- 1700.
2. Nakajima, J.; Sasaki, A.; Toru Obuchi, T.; Baba, S.; Nittaand, H. & Wakabayashi, G. (2009). Laparoscopic subtotal cholecystectomy for severe cholecystitis. *Surg. Tod.*, 39 (10): 870- 75.
3. Fulton, L. K.; Melody, S.; Clarke, B. S. & Harold, E. (1994). The goat as a model for biomedical research and teaching. *I. L. A. R. J.*, 36 (2).
4. Luna, L. G. (1968). *Manual of histological staining methods*. Armed forces institute of pathology. 3<sup>rd</sup> ed. New York. Mac Graw. Hill Bock Company. PP. 38 -76.
5. Humason, G. L. (1972). *Animal tissue technique*. 3<sup>rd</sup> ed. W. H. Freeman and Company. San Francisco, USA. PP. 148- 167.
6. Goshi, G. P. (2001). Complications of laparoscopic surgery. *Anesth. Clin. North. Am.*, 19: 1- 9.
7. Liu, Y.; Hui, N. & Gu, Q. (1996). Analysis of complications following laparoscopic surgery. *Zhonghua Fu Chan Ke Za Zhi.*, 31(6): 330- 333. Abstract.
8. Neudecker, J.; Sauerland. S.; Neugebauer, E.; Bonjer, H. J.; Fuchs. K. H.; Jacobi, C.; Jansen, F. W.; Lacy, A.; Millat, B. & Schwenk, W. (2002). European Association for Endoscopic Surgery clinical practice guideline on the pneumoperitoneum for laparoscopic surgery. *Surg. Endosc.*, 16: 1121- 1143.
9. Sandhu, T.; Yamada, S.; Ariyakachon, V. T. & Ko-iam, W. (2009). Low-pressure pneumoperitoneum versus standard pneumoperitoneum in laparoscopic cholecystectomy,a prospective randomized clinical trial. *Surg. Endosc.*, 23: 1044- 1047.
10. Beebe, D. S.; Zhu, S. & Kumar, M. V. (2002). The effect of insufflation pressure on CO<sub>2</sub> pneumoperitoneum and embolism in piglets. *Anesth. Analg.*, 94 (5): 1182–1187.
11. Beldi, G. & Glattli, A. (2003). Laparoscopic subtotal cholecystectomy in severe cholecystitis. *Surg. Endosc.*, 17: 1437-1439.
12. Wu, J.; Ling-Tang, L. & Jie-Shou, L. (2006). Role of laparoscopic subtotal cholecystectomy in the treatment of complicated cholecystitis. *Hepatobilia. Pancreat. Dis. Int.*, 5 (4): 584- 589.
13. Verma, G. R.; Lyngdoh, T. S. & Kaman, L. (2006). Placement of 0.5% bupivacaine-soaked Surgical in the GB bed is effective for pain after laparoscopic cholecystectomy. *Surg. Endosc.*, 20: 1560-1564.
14. Pulsipher, G. D.; Galyean, M. L.; Hallford, D. M.; Smith, G. S. & Kiehl, D. E. (1994). Effects of graded levels of bentonite on serum clinical profiles, metabolic hormones, and serum swainsonine concentrations in lambs fed locoweed (*Oxytropis sericea*). *J. Anim. Sci.*, 72: 1561- 1569.
15. Geraghty, J. M. & Goldin, R. D. (1994). Liver changes associated with cholecystitis. *J. Clin. Pathol.*, 47:457- 460.
16. Willard, M. D.; Tvedten, H. & Turnwald, G. H. (1999). *Small animal clinical diagnosis by laboratory methods*, 3rd ed. W.B. Saunders.
17. Hamel, J. (2003). *Clinical chemistry*. In: Tighe, M. M. and Brown, M. (eds.). *Mosby's comprehensive review for veterinary technicians*. Mosby, 2<sup>nd</sup>. ed. Chapter six. PP. 98-99.
18. Mena, H.; Santos, J. E. P.; Huber, J. T.; Tarazon, M. & Calhoun, M. C. (2004). The effects of varying gossypol intake from whole cotton seed and cotton seed meal on lactation and blood parameters in lactating dairy cows. *J. Dairy Sci.*, 87: 2506- 2518.

19. Fairouz, M. Y.; Elmalik, K. H. & Hassan, T. (2007). Effect of chemotherapy on liver enzymes levels in Nubian goats experimentally infected with *T. evansi*. Res. J. Pharmac., 1 (2): 40- 43.
20. Gamal, E. M.; Metzger, P.; Mikó, I.; Szabó, G.; Bráth, E. & Kiss, J. (1999). The judgement of adhesion formation following laparoscopic and conventional cholecystectomy in an animal model. Acta. Chir. Hung., 38 (2): 169- 172.
21. Szabo, G. Y.; Miko, P.; Nagy, E.; Brath, E. & Gamal, E. M. (2007). Adhesion formation with open versus laparoscopic cholecystectomy: an immunologic and histologic study. Surg. Endosc., 21: 253- 257.
22. Gutt, C. N.; Oniu, T.; Schemmer, P.; Kashfi, A.; Kraus, T. & Büchler, M.W.(2004).Circulatory and respiratory complications of carbon dioxide insufflation. Dig. Surg., 21: 95- 105.
23. Baakdah, H. & Tulandi, T. (2005). Adhesion in gynecology. Complication, cost, and prevention. Surg. Technol. Int., 14:185–90.
24. Tian, Y.; Shuo-Dong, W. U.; Yang, S. U.; Kong, J.; Hong, Y. U. & Ying, F. (2009). Laparoscopic Subtotal Cholecystectomy as an alternative procedure designed to prevent bile duct injury: Experience of a hospital in northern china .Surg. Today., 39: 510- 513.
25. Nickel, R.; Schummer, A. & Seiferle, E. (1979). The viscera of domestic mammals. Translation and revision by Wolfgang Otto Sack, by Verlag Paul Parey. Berlin. Hamburg. PP. 176- 178.
26. Balija, M.; Huis, M.; Szerda, F.; Bubnjar, J. & Stulhofer, M. (2003). Laparoscopic cholecystectomy accessory bile duct. Acta. Med. Croatica., 57: 105-109.
27. Al-Badrany, M. S. (2006). Cholecystectomy and liver biopsy achievement by laparoscopy in dogs. PhD. Thesis. Collage of Vet. Medicine. University of Mousel.
28. Laurila, J.; Laurila, P. A.; Saarnio, J.; Koivukangas, V. Syrjälä, H. & Ala-Kokko, T. I. (2006). Organ system dysfunction following open cholecystectomy for acute acalculous cholecystitis in critically ill patients. Acta. Anaesthesiol. Scand., 50: 173- 179.
29. Laurila, J.; Ala-Kokko, T. I. & Laurila, P. A. (2005). Histopathology of acute acalculous cholecystitis in critically ill patients. Histopath., 47: 485- 492.
30. Slauson, D. & Cooper, B. (1982). Healing and repair in mechanism of disease. William & Wilkins, Baltimore, U. S. A. PP. 223- 250.