

Diagnosis of *Cryptosporidium parvum* oocysts from it's natural sources

T. M. Finish and Z. M. Tawfeek

College of Veterinary Medicine\ University of Mosul

Abstract

The study was conducted for diagnosis of *Cryptosporidium parvum* oocysts in water, soil and calves. A total of 156 samples were collected from rural and urban areas in Mosul city, divided in to four groups. The first group 54 different water sample sources, 32 soil samples, 50 fecal samples from diarrheic calves and 20 fecal samples from non-diarrheic animals of different ages, sexes, breeds and areas. The overall percentage of oocysts that were identified was 26%, in water 24%, in soil 31%. Most significant commonly *Cryptosporidium parvum* oocysts has been associated with diarrheic calves 32%, than in (control group) non-diarrheic animals 15%, ($P \leq 0.05$). It was concluded that Modified Ziehl-Neelsen Stain was more sensitive and accurate for diagnosis of oocyst in all groups of samples in our study 27% as compared to Giem's Stain 23% and Lugol's Iodine stain 17%.

تشخيص الابواغ الخبيثة *Cryptosporidium parvum* في الماء والتربة والعجول في

مدينة الموصل

طلال محمود فنش وزهراء مصطفى توفيق

كلية الطب البيطري/ جامعة الموصل

الخلاصة

شملت الدراسة تشخيص وعزل الابواغ الخبيثة *Cryptosporidium parvum* oocysts في الماء والتربة وبراز العجول، واختيار الفحص والصبغة المناسبة لعزل الطفيلي، في الأنواع المختلفة من نماذج البحث في مدينة الموصل للفترة من (شباط - أيلول 2012). تم في هذا البحث جمع 156 عينة من الماء والتربة وبراز العجول من داخل المدينة والأرياف وقد وزعت النماذج إلى أربعة مجاميع: المجموعة الأولى 54 عينة ماء من جابيات الحيوانات، المياه الراكدة، البرك والمجاري. المجموعة الثانية 32 عينة من تربة الحدائق وحظائر تربية الحيوانات. المجموعة الثالثة 50 عينة براز عجول مصابة بالإسهال من مستشفى التعليمي البيطري في الكلية وسوق البقر. المجموعة الرابعة 20 عينة براز عجول غير مصابة بالإسهال من أجناس وأعمار مختلفة. كشفت الدراسة عن وجود طفيلي الابواغ الخبيثة في الماء بنسبة 24%، التربة 31%، وقد كانت نسبة وشدة الإصابة بالطفيلي في العجول المصابة بالإسهال 32% أكثر مقارنة بالعجول الطبيعية (التي لا تعاني من الإسهال) 15% مقارنة مع العجول الطبيعية عند مستوى ($p \leq 0.05$). وقد اتضح بأن استخدام طريقة الصبغ (زيل نيلسون المحورة) هي أحسن وأدق إذ اتضح بان استخدام الصبغة بلغت نسبة الإصابة 27% مقارنة مع الطرائق المخبرية للتشخيص مثل صبغة (كيمزا) 23%، وصبغة اليود 17%.

Introduction

Cryptosporidiosis is an enteric diarrheal disease world wide distribution (1,2). *Cryptosporidium parvum* is a zoonotic protozoan parasite causing diarrhea in different animal species among them are young calves, and it causes major economic losses directly through mortality and poor growth (2,3). *Cryptosporidiosis* is typically an acute short-term infection (3). The parasite is transmitted by contaminated water, food, soil or exposure to feces (4). The oocysts is ovoid or spherical and measure 4-6 μm across the oocysts 2-4 sporozoites that are bow-shaped (5). Water borne outbreaks of *cryptosporidiosis* have been reported the most infection is an outbreak in Milwaukee during spring 1993 (6). *Cryptosporidiosis* has no vectors and transmitted by the fecal-oral route (5). It is believed that *cryptosporidium* oocysts have always been presented to some degree in water (6). Also the diseases may spread through contamination of food

and soil (4, 6). Calves affected with *cryptosporidium* are usually one to four weeks of age (6). The *oocysts* is protected by an outer shell, referred to us thick-walled *oocysts*, which allows it to survive for long period of time outside the body in water, soil and can live in nature for 18 months (1). The aim of this study was to assess the incidence of *Cryptosporidium parvum oocysts* in water, soil and calves using different laboratory methods and stains and also to select the most sensitive and specific laboratory technique used for further diagnosis of *oocysts* in nature and calves.

Materials and Methods

- **Study Design:** A total of 156 samples including (water, soil and fecal samples from calves) were collected from urban and rural areas of Mosul city, (Telkeef, Kogjali, Cattle market, Hamma Al-ali, Muthana, College animal farm, Yarmook, Gayara) especially areas with animals husbandry and veterinary teaching hospital of the college (Mosul), also from cattle market in Mosul form February to September 2012.
- **Sample collection:** Water samples 54 were collected from water troughs, rainfall, sewage, stagnant water in volume (1-2L) from each different sources. Soil samples 32 from gardens animal yards, animals houses and from soil of veterinary teaching hospital in a weight 25-100 gm for each.
Fecal samples 70 from calves of different sexes, age (5 days to 9 month) breeds and areas, with and without diarrhea or intestinal illnesses.
- **Methods of Diagnosis:** *Cryptosporidium parvum oocysts* were detected in the above samples as follows:
 - A- Direct fecal microscopic examination two thin smears for each sample of feces stained by modified Zeihl-Neelsen stain and Lugol's iodine (7).
 - B- Sedimentation technique for detection of *oocysts* in water samples, and stained by modified Ziehl-Neelsen stain and Giemsa's stain (7, 8).
 - C- Floatation technique: using Sheathers sugar solution (Sp. gravity 1.2) for detection of *oocysts* in feces (7, 8).
 - D- Filtration technique: *oocysts* were isolated from different soil samples and examined microscopically as mentioned by (9).
 Calibration of detected *oocysts* to determine mean diameters of some *oocysts* by using ocular micrometers and photographed using digital camera. Statistical Analyses of the data is according to Chi-square test using test concerning several proportions(10).

Results

The definitive diagnosis of *oocysts* of *cryptosporidium parvum* in water, soil, and calves by finding the characteristic ovoid or spherical shape of *oocysts* using various laboratory parasitological tests and Stains. Table (1) shows the parasitological findings of *oocysts* diagnosed and estimated in water 24%, in soil 31.2%, in diarrheic calves 32% and in control group of animals 15%. Moreover on calibration of *oocysts* of different samples to estimate the mean diameter (Width × Length) of the *oocysts* detected. *Oocysts* in feces were larger than others, and some appear refractile, thick-walled and don't take the stain of Lugols' iodine (8).

Table (1) *Oocysts* recovery values in different samples in Mosul

Type of samples	No. of Samples	No. of Positive	%of Positive	Diameters of <i>oocysts</i>
Water	54	13	24%	3.8 × 5.2
Soil	32	10	31%	4.3 × 5.6
Diarrheic calves	50	16	32%	5.4 × 6.6
Non-diarrheic calves (feces)	20	3	15%	4.9 × 6.3
Total	156	42	26%	

Table (2) shows the *oocysts* burden of diarrheic calves in animals 32% and in non-diarrheic animals 15%.

Table (2) Parasitological Findings of *Cryptosporidium paravum* infection in Calves using different lab. stain

Samples	Stain	Mod. Z.N. stain		Lugol's iodine stain	
		No. of (+)	%	No. of (+)	%
Diarrheic calves (50).		16	32% *	10	20%
Non-diarrheic feces (20)		3	15% *	2	10%
Total 70		19	27% *	12	17%

* P ≤ 0.05

Table (3) *Cryptosporidium parvum* oocysts isolated from Water and Soil

Sample	Mod. Z.N. stain *		Giems Stain	
	No. of (+)	%	No of (+)	%
Water (54)	13	24% *	11	20%
Soil (32)	10	31% *	9	28%
Total (86)	23	26% *	20	23%

* P ≤ 0.05

The modified Z.N stain method proved and gave significant higher percentage of *oocyst* recovery in water 24%, in soil 31.2% and 32% in diarrheic calves, and 15% in non-diarrheic calves, than other stains (Lugol's iodine and Giems stain). Modified Ziehl-Neelsen stained *oocyst* appeared deep red to pink color spherical to ovoid, some containing black granules and mean average 3.2-6.6 µm across (Table 1, Fig. 1). Giems stained *oocysts* appeared bluish cytoplasm with reddish granules Fig (2). Lugol's iodine stained *oocysts* observed in fecal smear showed brownish color and some *oocysts* don't take the stain (Fig 3). Two types of *oocysts* were diagnosed thick-walled and thin-walled *oocysts*. The thick-walled type are passed in faeces. The thin-walled *oocysts* infect new enterocytes (Small intestine) causing autoinfection (11). In all samples that were examined microscopically the No. of isolated *oocyst*/field (Oil Immersion) is low ≤ 4.

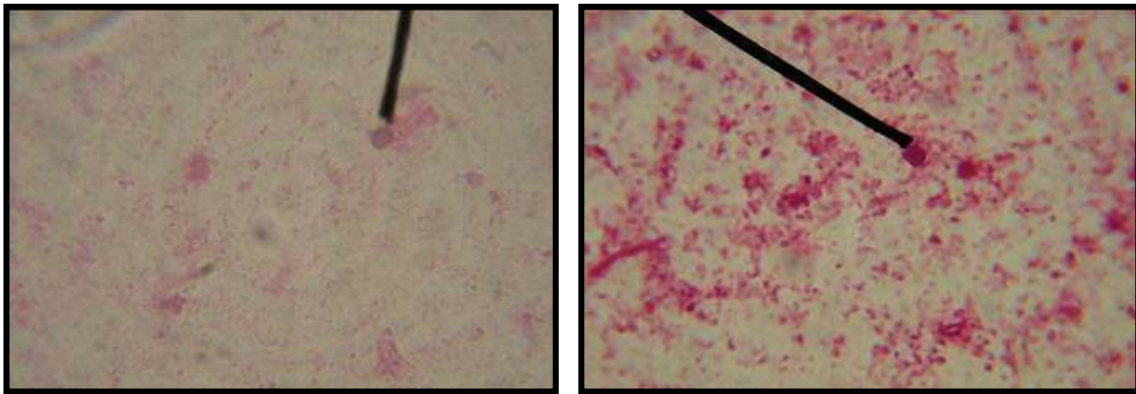


Fig (1) Modified Ziehl- Neelsen Stain *Oocysts* of *Cryptosporidium parvum*

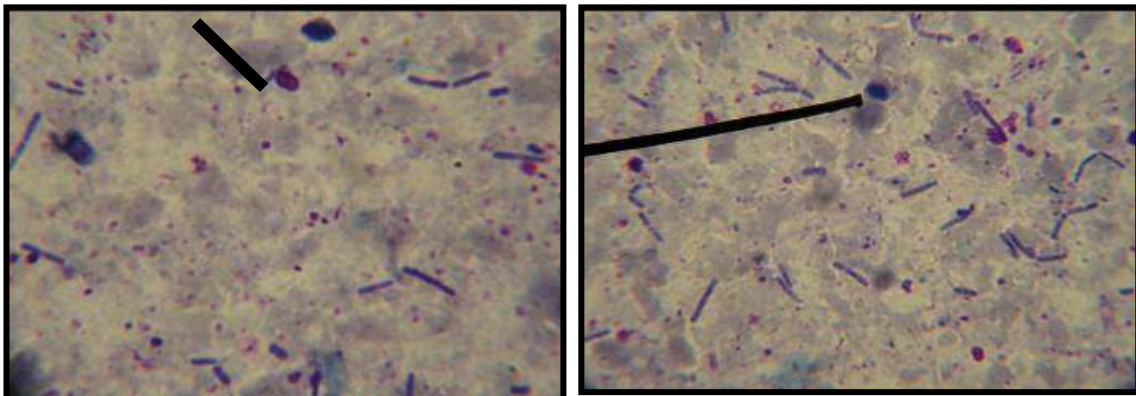


Fig (2) Giemsa' Stain *Oocysts* of *Cryptosporidium parvum*

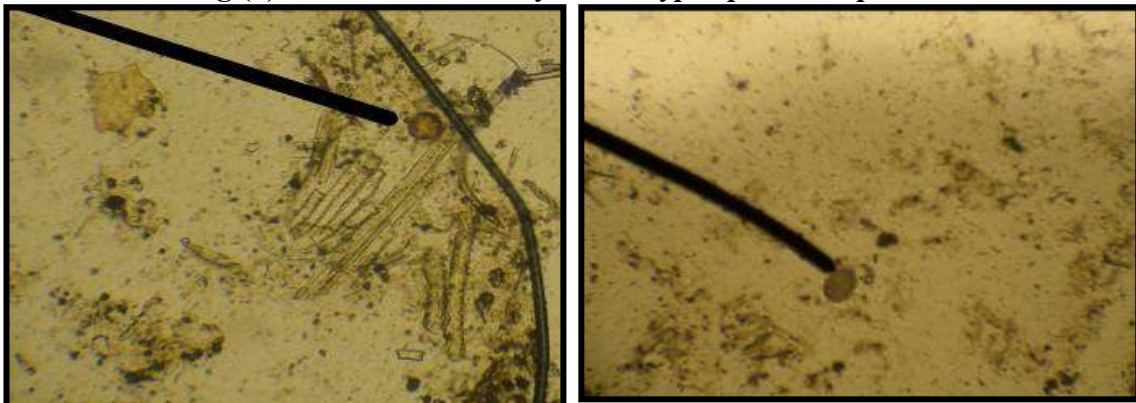


Fig (3) Lugols Iodine Stain *Oocysts* of *Cryptosporidium parvum*

Discussion

Cryptosporidiosis is primarily a water borne illness (2, 9). Infection through contact with contaminated fecal mater of cattle and calves carrying the *oocysts* to food, soil, raw water (5, 11). The results of this study revealed that *oocysts* recovery from water was 24%, this is in agreement with (12, 13, 14) who stated that the *oocysts* in different water samples and Tigers revere in Mosul city was 18.3%. *Oocysts* diagnosed in soil was 31.2%, this observation was supported by idea mentioned by (14, 15). In this study *Cryptosporidium parvum* *oocysts* detection is more in diarrheic calves 32% than in non-diarrheic calves 15% ($P \leq 0.05$), this finding are similar to reports previously mentioned by (17, 18, 19). The fact that the *oocysts* of this parasite have the ability to live in water and nature for long time, in a humid environment, cool and damp/ wet. Contaminated water with *oocysts*, sewage, manure, food, soil can infect calves (16). Our data showed that modified Ziehl- Neelsen stained *oocysts* of all samples (Table 2 and 3) (Fig 1) detection rate was higher and specific for diagnosis of this parasite, this is in agreement with the results reported by (17, 18, 19) and gave better diagnosis as compared with others stains used in this study. The morphology is related to the spp. nature of oocyst in different stained smears as shown in Fig. (1), (2) and (3).

References

1. Institute of food science and Technology (IFST). 2008. information statement. *Cryptosporidium* page 1 of 6.
2. Shultz, M. G. 1983. *Cryptosporidiosis*, a new zoonosis. J. Am. Vet. Med. Assoc., 183 (9): 962.
3. Sanford, S. E. & Josephson, G. K. 1982. Bovine *cryptosporidiosis*: clinical and pathology findings in forty-two scouring neonatal calves. Cand. Vet. J., 23: 343-347.
4. Nime, F. A. 1976. Cited by Tzipori, S. 1980: An outbreak of calf diarrhea attributed to cryptosporidial infection. Vet. Ref., 107:569-580.
5. Scott, C. A. H. V.; Smith, M. M.; Mtambo, A. & Gitts, H. A. 1995. An epidemiology study of *cryptosporidium parvum* in two herds of adult beef cattle. Vet. Parasitol., 37:277-288.
6. O'Donoghue, P. J. 1995. *Cryptosporidium* and *Cryptosporidiosis* of Man Animals Int. J. for Paras.; 25: 139- 195.
7. Garcia, L. S.; Brackner, D. A.; Brewers, T. C. & Shimizu, R. Y. 1983. Techniques recovery and identification of *Cryptosporidium Parvum* from stool specimens. J. Cl. Microboil., 18(1): 185-190.
8. Mtambo, M. M. A.; Nash, A. S. & Blewett, D. A. 1992. Comparison of staining and Concentration. Techniques for detection of *Cryptosporidium oocysts* in cat fecal specimen. Vet. Parasutol., 45: 49-57.
9. Kneen, B. M.; Darling, S. & Lemley, A. 2000. *Cryptosporidium*: a water borne pathogen. Internet, USDA water quality program, Cornell cooperation extension.
10. Steel, R. G. & Torrie, J. H. 1985. Principles and procedure of Statistics, 2^{ed} ed., McGraw-Hill Inc., P. 120.
11. Kazmierczak, D. A.; Addiss, K. R.; Fox, J.; Rose, R. & Devis, J. P. 1994. A massive outbreak of *Cryptosporidium* infection transmitted through the public water supply. N. Engl. J. Med., 331: 161-167.
12. بهنام سفیان نعمت. 2003. تواجد الطفيلي *Cryptosporidium* في مصادر المياه المختلفة في مدينة الموصل. رسالة ماجستير، كلية الطب البيطري/ جامعة الموصل.

13. الجرجري، سينا عبد الله. 2001. دراسة وبائية البويغيات الخبيثة ودور المياه في انتشار الطفيلي (*Cryptosporidium*). رسالة ماجستير، كلية التربية للبنات/ تكريت.
14. Freire-Santos, F.; Qteiza-Lopez, A. M. & Ares-Mazas, E. C. 2000. Study of the *Cryptosporidium Parvum*, environmental factors on viability of *Cryptosporidium Parvum* in water evaluated by fluorogenic vital dyes and excystation. Vet. Paras., 89 (4): 253-259.
15. Abdulrazak, A. M. & Jasm, G. A. 2011. Prevalence of *Cryptosporidium* In Calves and child in Al-Diwania city. Iraq. J. Vet. Med., 35 (1):190-194.
16. الزبيدي، محمد ثابت وعبد اللطيف. 1996. وبائية داء الابواغ الخبيثة في العجول. المجلة العراقية للعلوم البيطرية، 9 (2): 67-80.
17. Mohammad, T. S. & Baha, M. A. 1995. Epidemiology of *Cryptosporidium Parvum* In calves in Iraq. J. Vet. Sci., 8(1): 17-19.
18. يعقوب، عالية يوسف وشبر، إسماعيل كوان. 2004. دراسة وبائية داء الابواغ الخبيثة في العجول والإنسان في محافظة بغداد. المجلة الطبية البيطرية العراقية، 28 (1): 109-121.
19. Henriksen, S. A. J. & Pohlenz, F. L. 1981. Staining by modified Ziehl-Neelsen technique. Acta Vet. Scand, 22: 594-596.