

# CASE REPORT

---

## Isolated Unilocular Renal Hydatid Cyst

Dr. Fuad F. Alzubaidy\*

\* *Department of Surgery, Al-Hussein General Hospital, Karbala, Iraq.*

### Abstract

Hydatid disease is endemic in many parts of the world. The location of the cyst is mostly hepatic (75 %) and pulmonary (15 %), and only 10 % of the cysts occur in the rest of the body. Although hydatidosis can be present in all parts of the body, urinary tract involvement develops in only 2-4 % of all cases, and isolated renal cysts are extremely rare. There are no specific clinical symptoms or signs that will reliably confirm the diagnosis of renal echinococcosis. In addition, there is no laboratory finding that is pathognomonic for hydatid disease except for hydatiduria. Routine blood tests are generally normal except for eosinophilia which is found in only 50 % of the cases. Radiological studies have a more important place in the preoperative diagnosis of renal hydatid disease. We present herein a patient with isolated renal hydatid disease presented as left upper quadrant mass treated successfully with complete excision of the cyst and preservation of the kidney.

**Key words:** Hydatid disease, Kidney, Hydatiduria, Hydatidosis.

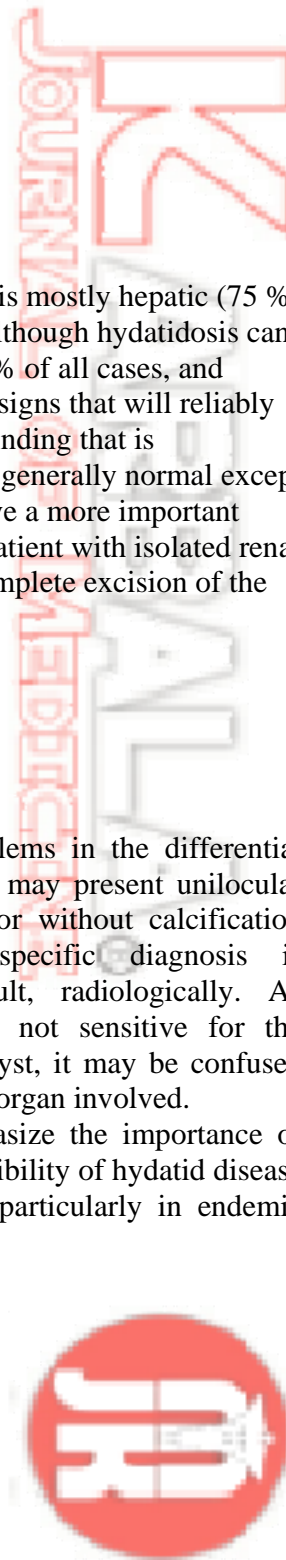
### Introduction

Hydatidosis is an endemic disease caused by the larval form of *Echinococcus granulosus* (1). It is mostly evident in liver and lungs, and renal hydatidosis is uncommon, comprising only 2-4% of all cases (2). The kidney is usually involved as part of disseminated disease, and isolated renal *Echinococcus* is extremely rare (1, 2). The kidneys are the most commonly affected organs in the genitourinary tract but hydatid cysts of the prostate, bladder, seminal vesicles and testis have been also reported (19).

The diagnosis of hydatidosis involving lungs and liver, which are specific organs for the disease, is easy with appropriate history, serological markers, and radiological imaging (3). Other than these commonly involved areas, hydatid cysts may rarely be located in other organs. Hydatid cysts with unusual localizations

may cause serious problems in the differential diagnosis. Also the cyst may present unilocular with a thin membrane or without calcification (4). Therefore, the specific diagnosis is sometimes very difficult, radiologically. As serological markers are not sensitive for the diagnosis of a hydatid cyst, it may be confused with a simple cyst in the organ involved.

We wanted to emphasize the importance of keeping in mind the possibility of hydatid disease in cystic renal lesions, particularly in endemic regions.

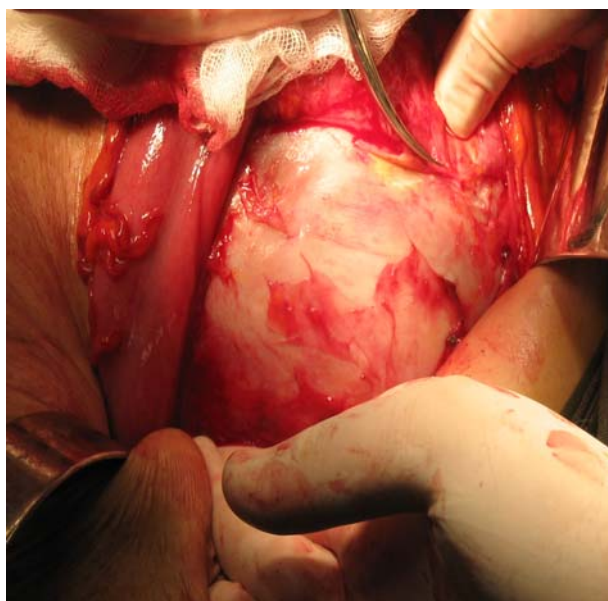


## Case Report

A 45 year old female patient was admitted to the surgical department complaining of gradual swelling of the left upper quadrant of the abdomen of about three months duration . The patients complained of heaviness in the upper abdomen and gradual abdominal distention in the upper part, otherwise the patient had no other complaint.

On examination , there was an asymmetrical upper abdominal distension with a 15 by 15 cm rounded mass located to the left side , that was immobile firm , and you can not get above it and it was dull to percussion. Two ultrasound examinations were performed and were inconclusive, one suggested probable hydatid cyst originating from the left lobe of the liver and the left kidney was displaced by the cyst and otherwise was normal. But both examiners advised for CT scanning which was unobtainable. .

The decision was made to explore the abdomen, on opening there was a big cyst in the retroperitonium pushing the descending colon anteriorly. The liver and the rest of the abdominal organs were normal. Kocherization of the descending colon was done to expose the cyst that was adherent to the spleen and pancreas from which it was successfully separated. After opening the Gerota's fascia, a thick walled and encapsulated cystic lesion, whitish in color of approximately 15 by 15 cm was located in the upper pole of the left kidney was seen .The cyst was carefully isolated from the retroperitonium and the cyst was packed with a lot of gauze soaked with betadine. The ectocyst was opened and the germinal membrane and hydatid cyst fluid and scolices were carefully removed and the cavity filled with betadine to prevent secondary infestation .Then the ectocyst was removed keeping only the part fused with the upper renal pole after making sure there was no communication with the collecting system and tube drain placed .The patient had a smooth postoperative period with the tube removed two days later and patient discharged home.



## Discussion

Hydatid disease is a parasitic infestation caused in humans by the larval forms of *E. granulosus*. Humans are intermediate hosts for hydatid cysts (5). The minute larval form of *E. granulosus* lives in the small intestine of dog species. The eggs are passed in the feces of an infected dog and can be passed to any mammal that ingests them. The eggs hatch in the duodenum; escaping embryos bore into the intestinal wall, gaining access to the mesenteric venules or lymphatics. The embryos are then carried to various parts of the body, where they develop into hydatid cysts. The most common location for development of a parasitic cyst is the liver (65-75 %), as the embryos are first carried there by mesenteric venules. Echinococcal larvae may reach the kidneys through bloodstream, lymph glands, or by direct invasion (1,5). Most affected patients are between the 3<sup>rd</sup> and 5<sup>th</sup> decades of life, and renal hydatidosis in children is rare (2, 3, 6). Our patient was 45 years old, consistent with the reported peak incidence. Infestation by *E. granulosus* can commonly be seen in individuals living in rural areas. It is endemic in parts of Africa, Latin America, Mediterranean countries, the Southeast, and Turkey, and it is attributed to close contact with dogs, sheep, and cattle.

Hydatid disease of the urinary tract is relatively uncommon and is likely to cause considerable diagnostic difficulties for clinicians and radiologists; therefore, it should be born in mind in the differential diagnosis of space-occupying lesions of the urinary tract. Evaluation of the previous medical history and current symptoms, together with the ultrasonographic and other radiological findings, is important for correct diagnosis and appropriate management (7). However, there are no specific signs or symptoms that will reliably confirm the diagnosis of renal echinococcosis, and the clinical presentation varies and usually results from compression of the adjacent structures by the cyst; hence, it depends heavily on the size and

anatomic localization of the cyst. Hydatid disease is often manifested by a slow-growing cystic mass. Cysts usually grow the most within the 1<sup>st</sup> year and can survive latently for years or decades. Thus, disease usually remains asymptomatic for years. The most common symptoms are palpable mass, flank pain, haematuria, malaise, fever, and hydatiduria. In our case, there was history of a slowly-growing mass and heaviness in the left upper abdomen. Complications of hydatid cysts, such as infection, abscess, hemorrhage, necrosis, and obstruction of the pelvicaliceal system, are also present in some cases (8, 9). None of these symptoms are specific for renal hydatidosis except hydatiduria. Although it is pathognomonic, it has been reported in 5-25 % of all renal hydatidosis cases. Hydatiduria was not detected in our patient (7-9).

On the other hand, there is no laboratory finding that is pathognomonic for hydatid disease except for hydatiduria. Routine blood tests are generally normal, except for eosinophilia which is found in only 20-50 % of the cases. Serological tests, such as the Casoni skin test, the complement fixation test, and the indirect hemagglutination test, even with a high incidence of false-negative and false-positive results, are helpful in some patients. The Casoni skin test produces positive results in about 25-50 % of the patients, while the Weinberg test yields about 40 % positive results. Although the indirect hemagglutination test has a higher positive rate of about 75 % for hydatid disease, it also shows false-negative results due to circulating immune complexes and false-positive data due to cross-reactivity with other parasitic infections, such as schistosomiasis and cysticercosis (2, 7-10, 19). Finally, although serological tests may be corroborative, none has shown high sensitivity and specificity. Therefore, it should be concluded that a negative serology does not exclude hydatid disease and a positive serology does not confirm the diagnosis.

Radiological studies have a more important place in the preoperative diagnosis of renal hydatid disease. These cysts are usually spherical or oval shaped, and they may be single or multiple, uniloculated or multiloculated and thin walled or thick walled. More specific signs include visualization or calcification of the cyst wall, the presence of daughter cysts, and membrane detachment (8, 11). Usually no rim enhancement is evident, unless the hydatid cyst is super infected. On plain X-ray, ring-shaped or peripheral curvilinear calcifications can be visualized, but they are nonspecific. Studies reported in the literature revealed calcifications on plain X-ray in 62 % of the patients (9). There was no calcification in our case. So, a hydatid cyst of the kidney may have an appearance indistinguishable from a benign cyst on US. CT scan can more easily detect calcifications and daughter cysts, and it is more sensitive and accurate than US. A CT scan shows a well-defined single or multiple cysts that may be uniloculated or multiloculated and either thin walled or thick walled. The diagnosis is easier, when the lesion has multiple locations involving other organs or when daughter cysts, germinal membrane detachment, and calcification are present (13).

However, sometimes the differentiation between hydatid cysts and simple cysts of the related organ is not always easy, especially if there is a unilocular cyst like in our case. For these reasons, hydatid disease may mimic benign or malignant cystic tumors, single or multiple metastases, congenital cysts, abscesses, pseudocysts, infarcts, hematomas, and other lesions. From the literature it was disclosed (13–

17, 19) that these cysts may be confused with cystic lesions such as pancreatic, ovarian, and breast lesions. In our case, the lesion had regular contours with a homogeneous intensity on US study. The preoperative differential diagnosis on the basis of imaging findings was simple renal cyst, complicated cyst, hydatid cyst of the left lobe of the liver, pancreatic cyst, e.t.c.

Although progress has been made in medical treatment and interventional radiology techniques, surgery is still the most effective therapy for hydatid disease which exists in any location. The principal objectives of the surgical treatment are total removal of all parasitic elements, avoidance of spillage of the contents of the cyst, and removal of the cyst with maximum conservation of the organ affected (7, 11–13, 18). Renal sparing surgery, cystectomy plus pericystectomy, is possible in most cases (75 %). Nephrectomy (25 % of cases) must be reserved for destroyed kidneys resulting from aged cysts opening into the excretory cavities and complicated by renal infection. Whether conservative or radical, the first surgery performed is cystectomy, with germinal membrane removal after controlled evacuation and opening of the cyst, making the subsequent steps of the surgery easier (20).

To conclude, this case emphasizes that hydatidosis should be considered in the differential diagnosis of any simple cystic lesion, especially in regions where it is endemic. To avoid misdiagnosis, careful examination of cystic lesions in kidneys should be carried out in endemic areas for the detection of hydatid cysts.

---

## References

1. Craig PS, Rogan MT: Echinococcosis: disease, detection and transmission. *Parasitology* 2003;127;5-20
2. Schoeneich G, Heimback D: Isolated echinococcal cyst of the kidney: case report and review of the literature. *Scand J Urol Nephrol* 1997; 31; 95-98.
3. Schipper HG, Kager PA: Diagnosis and treatment of hepatic echinococcosis: an overview. *Scand J Gastroenterol Suppl* 2004;241:50-55.
4. Col C, Col M: Unusual localizations of hydatid disease. *Acta M Austriaca* 2003; 30:61-64.
5. Bouree P, Hydatidosis: dynamics of transmission. *World J Surg* 2001;25;4-9
6. Limas C, Soultanidis C: Multifocal hydatid disease in a child. *Pediatr Surg Int* 2004;20;384-386.
7. Sayek I, Tirnaksiz MB: current trends in diagnosis and management. *Surg Today* 2004;34;987-996.
8. Umsal A, Cimentepe E: An unusual cause of renal colic; hydatiduria. *Int J Urol* 2001;8;319-321.
9. Angulo JC, Sanchez-Chapado M: Renal echinococcosis: clinical study of 34 cases. *J Urol* 1997;157;787-794.
10. Shetty SD, al-Saigh: Hydatid disease of the urinary tract: evaluation of diagnostic methods. *Br J Urol* 1992;69;476-480.
11. Savas L, Onlen Y: Hydatid disease with atypical localization: 4 case reports. *Scand J Infect Dis* 2004;36;613-615.
12. Gharbi HA, Hassine W: Ultrasound examination of hydatid liver. *Radiology* 1981; 139; 459-463.
13. Engin G, Acunas B: Hydatid disease with unusual localization. *Eur Radiol* 2000;10;1904-1912.
14. Erkan N, Haciyanli M: A case report of the unusual presence of hydatid disease in the pancreas and breast. *JOP* 2004;5;368-372.
15. Biyabani SR, Abbas F: Unusual presentations of hydatid disease of the urinary tract. *J Urol* 2000;163;896-898.
16. Gossios KJ, Kontoyiannis DS: Uncommon location of hydatid disease: CT appearance. *Eur Radiol* 1997;7;1303-1308.
17. Gupta RS, Raghavendran M: Isolated type 1 renal hydatid cyst presenting as a peripelvic cyst. *Urology* 2003;61;835-836.
18. Safioleas M, Misiakos EP: Surgical treatment of human echinococcosis. *Int Surg* 2000;85;358-365.
19. Cagatay G, Mut S: Isolated renal hydatidosis: Experience with 20 cases. *The J of Urol* 2003;169;186-189.
20. Krasimira K, Nicolai U: Primary Renal Echinococcosis. experience with 14 cases. *Journal of IMAB* 2007, book 1.