

## **Study Of Histopathological Effect Of Staphylococcus aureus In Female Albino Mice**

**دراسة التأثيرات النسيجية المرضية لجرثومة المكورات العنقودية الذهبية Staph aureus في اناث الفئران.**

Zainab.R.Z;Salema.L.H;Hana.A.K.

Zoonotic diseases Department/Pathology and Poultry Department/Collage of  
VeterinaryMedicin/ Baghdad University.

### **Summary**

This experiment was designed to study histopathological changes in internal organs: liver,spleen,heart,lung,kidney,intestine,stomach,pancreas,ovary,uterus,and oviduct of white female mice after ingectable with *Staphylococcus aureus* dose  $1 \times 10^6$  .Thirty white female mice aged from (one month-two months), and weighted from (25-30) grams, and this study was worked in Pthology department\college of Veterinary Medicine\Baghdad University/.The mice were randomly divided into 6equal groups. Group1 ingected intra mammary gland with  $1 \times 10^6$  *S.aureus* & killed after 24 hr.Group2 injected intra mammary with  $1 \times 10^6$  *S.aureus* & killed after48hr. Group 3 injected intra mammary with  $1 \times 10^6$  *S.aureus* & killed after 72 hr. Group 4 injected intra mammary with  $1 \times 10^6$  *S.aureus* & killed after one week. Group 5 injected intra mammary with  $1 \times 10^6$  *S.aureus* & killed after two weeks. Group 6 injected with normal saline along the period of experiment and considered as control group. The histopathological findings for liver, kidney, spleen, stomach, intestine, pancrease, ovary, uterus, mammary gland and oviduct showed infiltration of mononuclear cell with the liver paranchyma &portal area and pancreas interstitial tissue of the kidney with perivascular lymphocytic cuffing &mild degeneration changes represented by acute cellular swelling of hepatocytes and epithelial cell lining .The cortical renal tubules.In addition to sever congestion &dilatation of central vein and sinusoid. In addition to coagulation material in the in the lumen and small abscess in the parenchyma & thrombus. Necrosis of the hepatocyte. Spleen showed lymphoid hyperplasia of white pulp with sever congestion of blood vessels with infiltration of neutrophil in the blood sinus and proliferation of megacarocyte. Lung showed edema with congestion of blood vessels & haemorrhge and infiltration of mononuclear cell in the alveoli wall and thickening of the alveoli septa. Heart showed sever congestion with heamorrhge &infiltration of poly morphonuclear cells (PMN` S) between muscle fibers and losse of muscle straight .Intestine &stomach showed sloughing of epithelial lining the mucosal layer with congestion of blood vessels & infiltration of (PMNS) diagnostic as chronic suppurative enteritis and gastritis. Ovary showed congestion of blood vessels with tiny aggregated abscess consist of dead and live neutrophil &tissue debris diagnosis as oophilitis. Uterus showed congestion of blood vessels with infiltration of neutrophl in wall of uterus &proliferation of endometritis layer diagnostic as endometrosis. Oviduct showed congestion of blood vessels with infiltration of neutrophil in the epithelial lining & proliferation of epithelial lead to stenosis. Mammary gland showed congestion of blood vessels, with infiltration of neutrophil between smooth muscle fiber &present of portentous material pink cooler in the lumen.

### **الخلاصة**

صممت هذه الدراسة لغرض دراسة التغيرات المرضية النسيجية للاعضاء الداخلية (الكبد والطحال والقلب والرئة والكلية والامعاء والمعدة والبنكرياس والمبايض والرحم وقناة البيض) لاناث الفئران بيضاء اللون بعد من حقنها بجراثيم المكورات العنقودية الذهبية وجرعة مقدارها (  $10^6$  ) , ثلاثون فارة بيضاء اللون تراوحت اعمارها من (شهر-

شهرين) واوزانها من (25-30) غرام, حيث اجريت الدراسة في فرع الامراض\ كلية الطب البيطري\ جامعة بغداد, قسمت عشوائيا الى ستة مجاميع. المجموعة الاولى حقنت داخل متن الغدة الثديية وقتلت بعد 42 ساعة. المجموعة الثانية حقنت داخل متن الغدة الثديية وقتلت بعد 48 ساعة. المجموعة الثالثة حقنت داخل متن الغدة الثديية وقتلت بعد 72 ساعة. المجموعة الرابعة حقنت داخل متن الغدة الثديية وقتلت بعد 1 اسبوع. المجموعة الخامسة حقنت داخل متن الغدة الثديية وقتلت بعد 2 اسبوع. المجموعة السادسة حقنت المحلول الملحي الطبيعي داخل متن الغدة الثديية وقتلت بعد 2 اسبوع وعدت مجموعة سيطرة. التغيرات النسيجية تميز الكبد في كافة الحيوانات المحقونة بحصول النزف والاحتقان وحصول تغيرات تنكسية مختلفة الشدة مع وجود بؤر من الخلايا متعددة الانوية (PMNS) خصوصا العدلات. احتقان الوريد المركزي وتمدده واحتقان الجيبانيات بالإضافة الى خراجات صغيرة متعددة ومتناثرة في متن الكبد. اما البكرياس فقد لوحظ احتقان الاوعية الدموية فيه وارتشاحه بخلايا العدلات. اما الطحال لوحظ في الاوعية الدموية وارتشاح خلايا العدلات في المجاميع (1, 2, 3) وارتشاح خلايا البلعمات في المجاميع (4,5), مع وجود تجمعات لخلايا وحيدة النواة حول الاوعية الدموية. اما الكلية فقد لوحظ تورم الخلايا المبطنة لقسم من النبيبات واحتقان الاوعية الدموية وتنخر قسم من الخلايا الظهارية وارتشاح خلايا العدلات مع وجود نزف مع وجود بؤر من التجمعات لخلايا وحيدة النواة واحتقان الاوعية الدموية للثة الكبيبية, اما الرئة تميزت بوجود خبز واحتقان الاوعية الدموية ونزف مع ارتشاح خلايا وحيدة النواة في جدار الاسناخ. اما القلب تميز بوجود نزف واحتقان الاوعية الدموية كما لوحظ ارتشاح خلايا وحيدة النواة في الطبقة الداخلية والعظمية اي بين الالياف العظمية. اما بالنسبة للمعدة والامعاء فقد لوحظ انسلاخ الظهارة والارتشاح بالخلايا الالتهابية لطبقة المخاطية وتحت المخاطية مع احتقان الاوعية الدموية وشخصت الافة على انها التهاب المعى القيحي المزمن والتهاب المعدة. اما بالنسبة للمبيض تميز بوجود احتقان الاوعية الدموية مع وجود خراجات صغيرة الحجم مكونة من اعداد هائلة من خلايا (PMNS) مثل العدلات وخلايا البلاعم الكبيرة حلت محل النسيج وشخصت الافة على انها التهاب المبيض القيحي. اما الرحم فقد اظهر وجود نزف واحتقان الاوعية الدموية مع ارتشاح الخلايا الالتهابية خصوصا العدلات في جميع الطبقات الرحم مع وجود فرط التنسج في الطبقة الداخلية لرحم وشخصت الافة على انها التهاب الرحم القيحي. اما بالنسبة لقناة البيض فقد اظهرت وجود احتقان الاوعية الدموية مع حصول فرط التنسج للخلايا الظهارية المبطنة للعضو مما ادى الى تضيق تجويف العضو. اما بالنسبة للغدة الثديية فقد اظهرت احتقان الاوعية الدموية مع ارتشاح خلايا العدلات مع وجود مواد متجينة وردية اللون داخل تجويف الغدة.

## **Introduction:**

*Staphylococcus aureus* was discovered in Aberdeen, Scotland in 1880 by the surgeon Sir Alexander Ogston in pus from surgical abscesses (1). About 20% of the population is long-term carriers of *S. aureus*, each year, some 500,000 patients in American hospitals contract a staphylococcal infection (2).

*Staphylococcus aureus*, is a facultative anaerobic, Gram-positive coccus, and is the most common cause of staph infections. It is frequently part of the skin flora found in the nose and on skin. The carotenoid pigment staphyloxanthin is responsible for its characteristic golden colour, which may be seen in colonies of the organism. This pigment acts as a virulence factor with an antioxidant action that helps the microbe evade death by reactive oxygen species used by the host immune system. Staphylococci which lack the pigment are more easily killed by host defenses. *S. aureus* can cause a range of illnesses from minor skin infections, such as pimples, impetigo, boils (furuncles), cellulitis folliculitis, carbuncles, scalded skin syndrome, and abscesses, to life-threatening diseases such as pneumonia, meningitis, osteomyelitis, endocarditis, toxic shock syndrome( 3 ). *S. aureus* is capable of secreting several exotoxins, which can be categorized into three groups. Many of these toxins are associated with specific diseases.(4) Staphylococcal toxins that act on cell membranes include alpha toxin, beta toxin, delta toxin, and several bicomponent toxins. The bicomponent toxin Pantone-Valentine leukocidin (PVL) is associated with severe necrotizing pneumonia in children. Exfoliative toxins EF toxins are implicated in the disease staphylococcal scalded-skin syndrome (SSSS), which occurs most commonly in infants and young children. It also may occur as epidemics in hospital nurseries. The protease activity of the exfoliative toxins causes peeling of the skin observed with SSSS. Protein A is anchored to staphylococcal peptidoglycan pentaglycine bridges (chains of five glycine residues) by the transpeptidase sortase A(5) Protein A, an IgG-binding protein, binds to the Fc region of an antibody. In fact, studies involving mutation of genes coding for protein A resulted in a lowered virulence of *S. aureus* as measured by survival in blood, which has led to speculation that protein A-contributed virulence requires binding of antibody Fc regions.(6) Protein A in various recombinant forms has been used for decades to bind and purify a

wide range of antibodies by immunoaffinity chromatography. Transpeptidases, such as the sortases responsible for anchoring factors like Protein A to the staphylococcal peptidoglycan, are being studied in hopes of developing new antibiotics to target MRSA infections.(7) *S. aureus* infections can be spread through contact with pus from an infected wound, skin-to-skin contact with an infected person by producing hyaluronidase that destroys tissues, and contact with objects such as towels, sheets, clothing, or athletic equipment used by an infected person. Deeply penetrating *S. aureus* infections can be severe. Prosthetic joints put a person at particular risk for septic arthritis, and staphylococcal endocarditis (infection of the heart valves) and pneumonia, which may be rapidly spread at slow rates. The Translational Genomics Research Institute showed that nearly half (47%) percent of the meat and poultry in U.S. grocery stores were contaminated with *S. aureus*, with more than half (52%) of those bacteria resistant to antibiotics.(8). This study aimed to know the effect of *s.aureus* on the internal organs during the severity and progress of the mastitis disease.

## **Materials and Methods:**

**1- Bacterial isolates:** after the isolation of *Staphylococcus aureus* bacteria on the blood agar and then on mannitol salt agar, the bacterial suspension ( $1 \times 10^6$ ) was prepared as the method in (9). The mice mammary glands were injected by *Staph aureus* bacteria (0.1cc) for each teat from two to four teats for each one female. The female mice aging from (one month –two months) and weight from (25-30) grams were divided into 6 groups and each group consists of 5 animals:

**A-** The first group was killed after 24 hours from the injection by the bacteria.

**B-** The second group was killed after 48 hours from the injection.

**C-** The third group was killed after 72 hours from the injection.

**D-** The fourth group was killed after one week from the injection.

**E-** The fifth group was killed after two weeks from the injection.

**F-** The sixth group was stayed as control group without infection.

## **2- Histopathology:**

After one day mice were sacrificed under anesthesia. Tissue specimens from liver, pancreas, kidney, spleen, heart, lung, intestine, stomach, uterus, ovary, oviduct and mammary gland were taken for histopathological examination using 10% neutral buffered formalin as a fixative, then processed routinely in histokinette, cut at 5 mm thickness by microtome and stained with hematoxylin and eosin stain then examined under light microscope (10). After 2,3 days and 1-2 weeks animals of group 2, 3, 4, 5 and 6 were dissected in the same manner as those sacrificed after 1 day.

## **Results:**

### **Histopathological changes:**

#### **1- Liver:**

After 1 day. showing congestion of central vein & swelling of hepatocyte lead to stenosis the lumen of the sinusoid. After 2-3 days. showing swollen of hepatocyte with vascular degeneration of hepatocyte and infiltration of neutrophil in the sinusoid and dilatation of the sinusoid. After 1-2 weeks. Showing congestion, hemorrhage and necrosis of hepatocyte. Also foci aggregation of neutrophil in the parenchyma and infiltration of lymphocyte in the sinusoid. (Figure 1).

#### **2- Pancreas:**

Mild congestion of blood vessels and mild infiltration of neutrophil. After 2-3 days. Similar lesion in the 1 day period. (Figure 2). After 1-2 weeks. Showing severe congestion & focal aggregation of neutrophil.

#### **3- Kidney:**

After 1 day. showing mild congestion of the blood vessels to the glomeruli tuft. Degeneration of epithelial lining renal tubule lead to stenosis of lumen or closed (cloudy swelling). After 2-3 days. Showing severe congestion of blood vessels of renal tubule and glomeruli tuft. Swelling & degeneration of epithelial lining of renal tubule. Also foci aggregation of neutrophil in the cortex & medulla. (Figure 4). After 1-2 weeks. Similar lesion as in the 2-3 days period.

**4-Spleen:**

After 1day.Showing congestion of blood vessels & mild infiltration of neutrophil in the blood sinuses. After 2-3 days.Similar lesion in the 1 day period.

After 1-2weeks.showing sever congestion with moderat infiltration of neutrophil .Also proliferation of megacarocyte and hyperplasia of lymphoid follicle.(Figure 3).

**5- Heart:**

After 1day.showing mild congestion of blood vessels between muscle fiber and endo cardial lumen.Also mild infiltration of neutrophil between muscle fiber. After 2-3days.Similar lesion in the 1day period.

After 1-2weeks.Showing sever congestion & haemorrhage of blood vessels between muscle fiber.Infiltration of neutrophil between muscle fiber and losse of striation of the muscle fibers.(Figure 6).

**6- Lungs:**

After 1day.Thicking in the wall of the alveoli due to congestion of blood capillary .Infiltration of neutrophil in the interstitial tissue with emphysema. After 2-3day.Similar 1day period. After 1-2weeks.Showing haemorrhage & congestion of blood capillary .Sever thickening of alveoli wall and inter alveoli septa.Infiltration of neutrophil in the lumen of the alveoli,bronchiol,bronchus&emphysema. (Figure 5).

**7- Intestine:**

After 1-2days.Showing desquamations of epithelial lining mucosal layer. With infiltration of mucosa sub mucosa by neutrophil .Congestion of blood vessels(Figure 8). .Lumen of intestine contain exudates consists of large number of neutrophil and debris cells of mucosa & sub mucosa. After 3days.Similar lesion in the 1-2days but severity. After 1-2weeks.Showing larg number of dead&live neutrophil also macrophage replase the exhibit tissue .These abscesses diagnosis as chronic suppurative enteritis.

**8- Stomach:**

After 1-2-3days.Desquamation of partial mucosal layer&diltation of mucosal gland. After 1-2weeks.Showing desquamations all mucosal layer&distracted due to degeneration with infiltration of neutrophil,lymphocyte&macrophage in the muscular layer.(Figure 7).

**9- Uterus:**

After 1-2-3days.Showing congestion of blood vessels edema in endometrium with infiltration of neutrophil in endometrium ,myometrium &stroma. After 1-2weeks,Showing sever congestion of blood vessels in endometrium with infiltration of neutrophil & monocyte cells In the myometrium and hyperplasia of endometrium epithelial .(Figure 9).

**10- Ovary:**

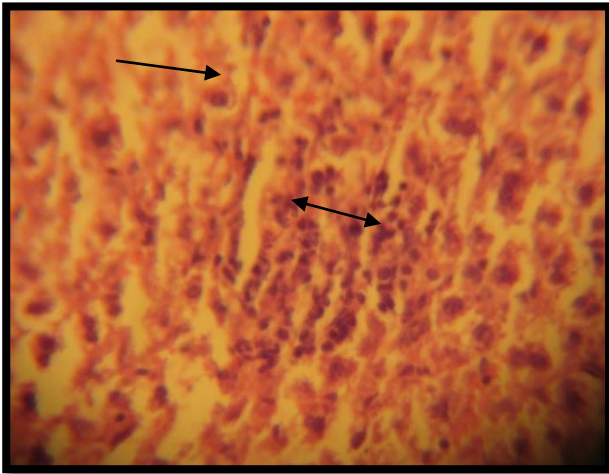
After 1-2-3days.Showing mild to moderate congestion of blood vessels & infiltration of neutrophil.After 1-2weeks.Showing sever congestion of blood vessels & foci aggregation of neutrophil.

**11- Oviduct:**

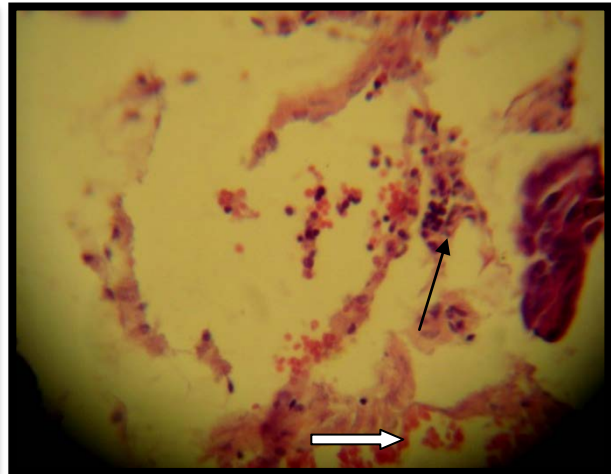
After 1-2-3days.Showing mild to moderate congestion of blood vessels infiltration of neutrophil. After 1-2weeks.Showing sever congestion of blood vessels with infiltration of neutrophil with hyperplasia of epithelial lining projection lead to present papillary in the lumen.(Figure 11).

**12- Mammary gland:**

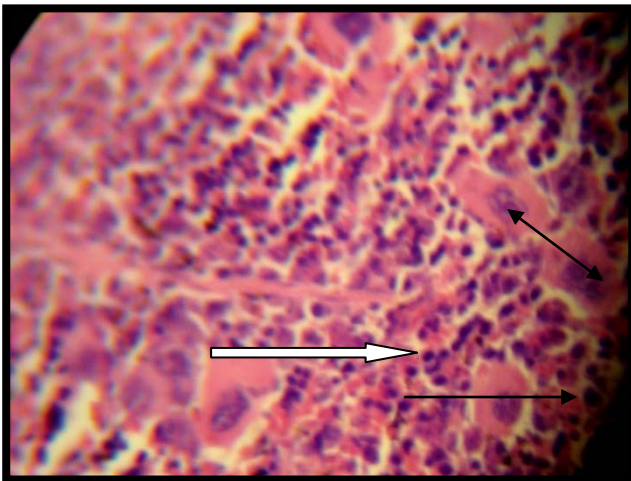
After 1-2-3days.Showing congestions of blood vessels with infiltration of neutrophil between interstitial tissue .(Figure 12). After 1-2weeks.Showing sever infiltration of neutrophil with thickening of interstitial tissue between glandular alveoli & necrosis.



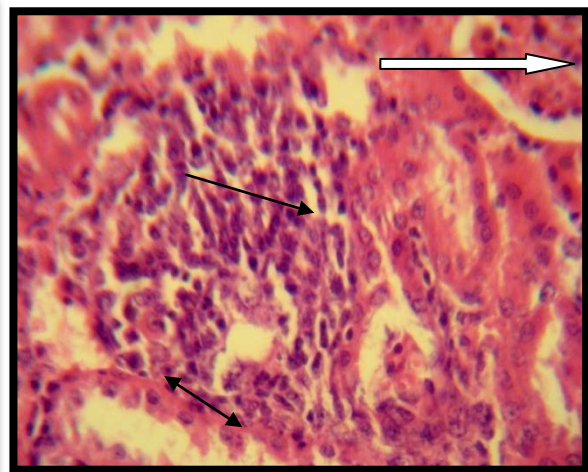
**Fig1:Histopathological section in liver of one animal 2weeks showed necrosis of hepatocyte ( → ) with foci infiltration of neutrophils ( ←→ ) in the sinusoid diltation .(H&EX400).**



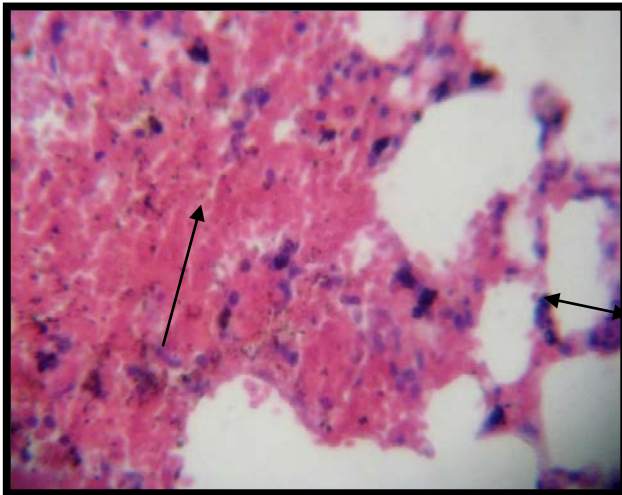
**Fig2:Histopathological section in pancrease of one animal at 2-3 3days showed infiltration of neutrophils(→)& congestion of blood vessels ( ⇨ ) .(H&EX400).**



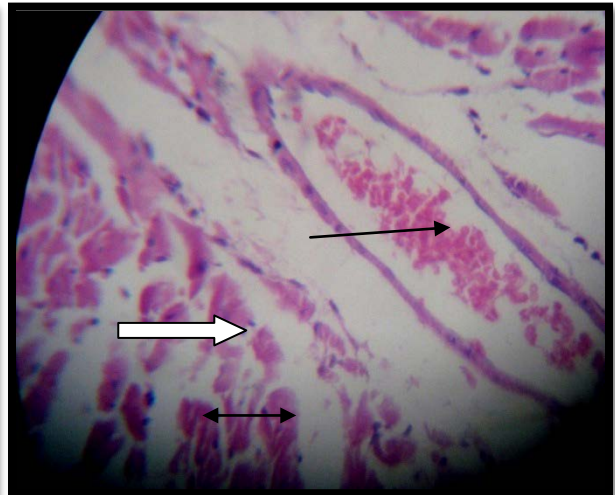
**Fig 3 :Histopathological section in spleen of one animal at 2 weeks showed infiltration of neutrophils ( ⇨ ) &congestion of blood sinuses ( → ) with hyperplasia of lymphoid follicles &proliferation of megacarocyte ( ←→ ) .(H&EX400)**



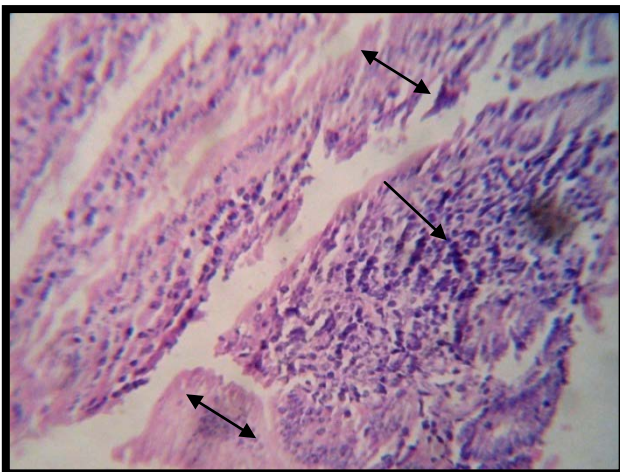
**Fig 4 :Histopathological section in kidney of one animal at 3 days showed focal infiltration of neutrophils(→) In interstitial tissue &in the cortex and medulla& sever congestion of blood vessels of glomeruli tuft( ⇨ ) with degeneration of epithelial lining of renal tubule(cloudy swelling( ←→ ).(H&EX400).**



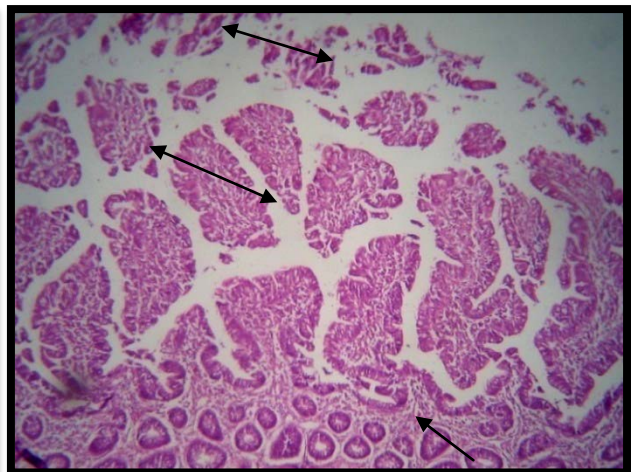
**Fig5 :** Histopathological section in lung of one animal at 1-2 weeks showed haemorrhage (→) of blood capillaries .Sever thickening of alveoli wall and inter alveoli septa. Infiltration with neutrophil ( ↔ ) (H&EX400).



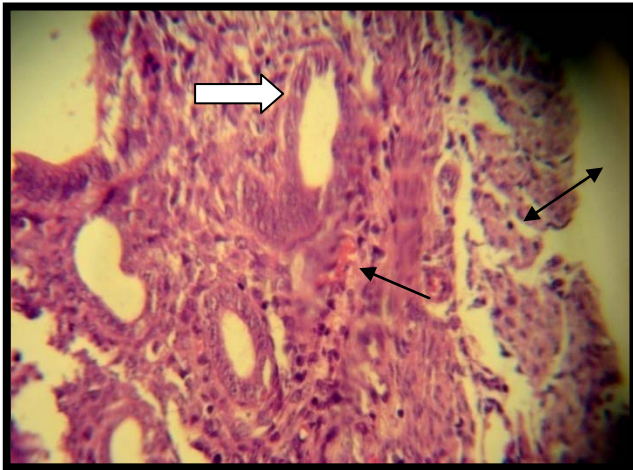
**Fig6 :** Histopathological section in heart of one animal 1-2 weeks showed haemorrhage (→) of blood vessels between muscle fiber. Infiltration of neutrophil between muscle fiber ( ↔ ) and losse of striation of the muscle fibers ( ↔ ).(H&EX400).



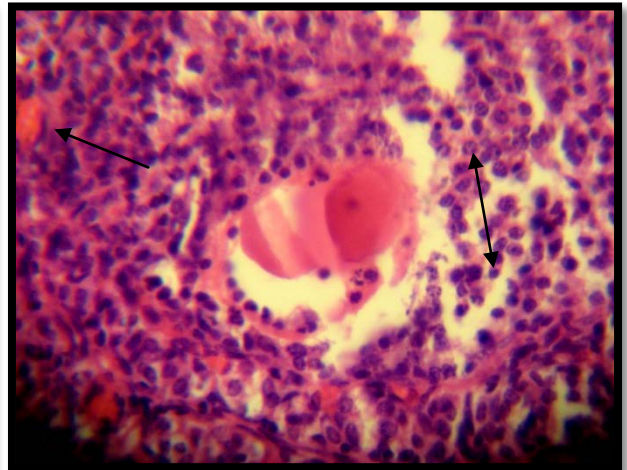
**Fig 7:** Histopathological section in stomach of one animal at 1-2 weeks showed desquamations all mucosal layer & distraction due to degeneration ( ↔ ) with infiltration of neutrophil, lymphocyte & macrophage in the muscular layer ( → ). (H&EX400).



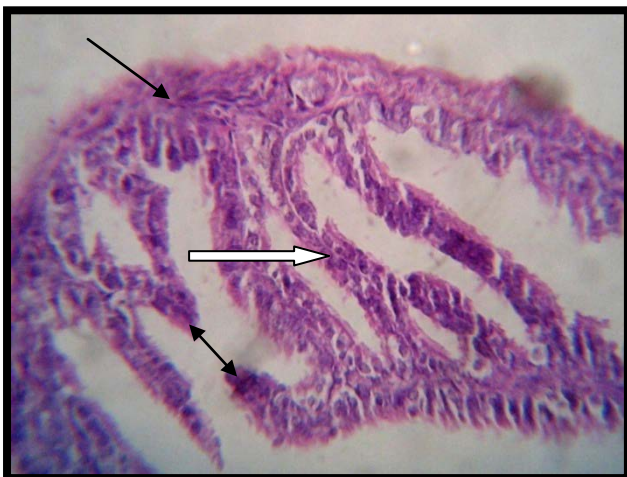**Fig 8 :** Histopathological section in intestine of one animal at 1-2 days showed desquamations of epithelial lining mucosal layer ( ↔ ) . With infiltration of mucosa sub mucosa by neutrophil ( → ). (H&EX40).



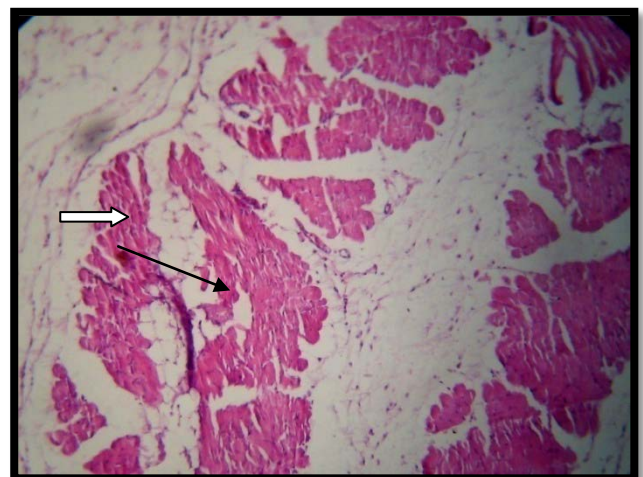
**Fig 9 :** Histopathological section in uterus of one animal at 1-2 weeks showed severe congestion of blood vessels (→) in endometrium with infiltration of neutrophil & monocyte cells in the myometrium (⇨) and hyperplasia of endometrium epithelial lining (↔). (H&EX400).



**Fig 10 :** Histopathological section in ovary of one animal at 1-2 weeks showed severe congestion of blood vessels (→) & foci aggregation of neutrophil (↔). (H&EX400).



**Fig 11:** Histopathological section in oviduct of one animal at 1-2 weeks showed severe congestion of blood vessels (→) with infiltration of neutrophil (⇨) hyperplasia of epithelial lining projection lead to present papillary in the lumen (↔). (H&EX400).



**Fig 12 :** Histopathological section in mammary gland of one animal at 3 days showed congestions of blood vessels (→) with infiltration of neutrophil between interstitial tissue (⇨). (H&EX100).

### **Discussion:**

All examined organs showed suppurative reaction. These results agreed with (11) who showed that *S.aureus* infections are often acute pyogenic and spread to surrounding deeper tissues or metastasize to other sites involving other organs, resulting disseminated or deep-seated infections which are life threatening disease. Also (12) explained that both localized infection, such as soft tissue abscess, and life threatening system i.e factors that decrease

phagocytosis and factors that interact with anti staphylococcal antibodies and elaborate protease, exotoxins and enzymes, factors that specifically cause cell and tissue damage.

The severe congestion of blood vessels and degeneration in most organs were due to septicemia and endotoxemia, indicating that *S.aureus* induces septic shock. Shock defined as inadequate perfusion of tissue resulting in cell dysfunction and death. Sepsis result in much more complex form of shock. This evident was reported by (13,10) who explained that cell wall secreted protein A, hemolysins ( $\alpha$ ,  $\beta$  and  $\delta$ -toxine), and cell wall components such as PGN and alanylated LTA acid were involved in the synthesis of inflammatory cytokines by monocytes/macrophages and these cytokines may contributed to sepsis. Degeneration in some organs were seen in liver, kidney, intestine, stomach, probably due to cytotoxic effects of *S.aureus* products. These explanation were agree with investigation of (14) who discussed the cytotoxic action of  $\alpha$ -toxin produced by *S.aureus* is reflected in a rapid depletion of cellular ATP with 30 minutes and these toxin lead to release of IL- $1\beta$ , TNF- $\alpha$  from monocytes, TNF- $\alpha$  and IL- $1\beta$  induce cardiac depression in sepsis, also the recruitment and activation polymorphonuclear cell (PMNs) may also contribute to the development of septic myocardial failure (15).  $\alpha$ toxin may initiate cellular events that are relevant to the quantities of cysteinyl-Leukotriene, LTB<sub>4</sub> and 5-OH-ecosatetraenoic acid lead to neutrophils accumulation and coronary vasoconstriction and dysfunction (16) *S. aureus* can express a toxin that specifically acts on polymorphonuclear leukocytes. Phagocytosis is an important defense against staphylococcal infection so leukocidin should be a virulence factor (17).

The suppurative lesion is in agreement with (18) Liver X receptors (LXRs) a and b belong to a group of nuclear receptors which, after ligand binding, regulate gene transcription. Activation of LXRs inhibits inflammation and autoimmune reactions. Animals lacking LXRA develop more severe infection, as demonstrated by a greater amount of bacteria in macrophages, more neutrophil abscesses in the liver, and higher mortality. The expression of LXRA, but not LXRB, is strongly stimulated in macrophages infected with intracellular pathogens such as *Listeria* and *Shigella flexneri*, but it is only weakly stimulated by extracellular pathogens such as *E. coli* or *Staphylococcus aureus* (18). When macrophages phagocytose bacteria or other pathogens which contain little or no cholesterol, LXRs are not stimulated, which allows the inflammatory reaction to develop; this reaction is desirable to protect against pathogens (19). Hyperplasia of splenic white pulp and lymphatic aggregation around blood vessels and hyperplasia of epithelial lining of internal organs in 1-2 weeks correlated with a good acquired immunity (20)

The endocarditis lesion agreed with (21) these bacteria enter the blood stream and establish themselves in the damaged heart valves (especially in prosthetic heart valves). They can produce adhesins, dextran and fibronectin binding proteins, attach to the heart valves. Visible abscess, collapse in lung & cloudy swelling, degeneration of cortical renal tubule reported agree with (22) the reactions described as being due to *Staphylococcus* toxin. Also agree with (21) who explained that *Staphylococcus* is a commonly occurring disease resulting in a fatal generalized septicemia or in a localized suppurative inflammation. *Staph aureus* is common disease in both domestic and wild rabbits (10). The disease is usually sporadic and of little economic importance for commercial rabbitries. Most often, suppurative lesions with *Staphylococcal* infection, often lead to chronic abscessation in affected sites. The acute septicemia from occurs mostly in neonatal kits and can have lesions ranging from few and nonspecific to multifocal and suppurative in various organs, including the lung, kidney, spleen, heart and liver. Also lesion in lung agree with (23) isolated *Staph* from all 5-month old New Zealand four rabbit with mild mucosuppurative discharge. (24) found that *Staphylococcosis* caused by *Staph. aureus* may be manifest as fat pneumonia in rabbits (25) isolated *Staph.aureus* from upper respiratory tract of healthy rabbits with an incidence of 100%. The suppurative lesion in reproductive organs agree with (26) who explained that *Staphylococci* produce many extracellular proteins that add to their pathogenicity: surface proteins that promote adherence, enzymes that degrade host compounds, and toxins that damage host cells. *Staphylococci* induce platelet aggregation, and *S. aureus* specifically produces coagulase, both properties which promote thrombosis of small vessels, as seen in the uterine submucosa of this rabbit. There is a high

correlation between those Staphylococci that produce coagulase and those that produce toxins. Since the uterine infection was so acute and severe, it was likely that a staphylococcal toxin was also involved, most likely alpha-toxin which selectively damages the endothelial layer of blood vessels by forming hexameric pores within the plasma membrane. The experimental appears Uterus. Diffuse caseous necrosis of the endometrium with bacterial colonies on the surface and dense fibrin thrombi in the lamina propri. Endometritis, necrotizing, acute, diffuse, severe, with fibrin thrombi, edema, numerous cocci, and transmural lymphoplasmacytic, neutrophilic and histiocytic inflammation. Also agree with few cases endometritis with mucopurulent inflammation of uterus in female pregnant does. Exactly more or less the same observation was recorded (27).

## **References**

- 1. Ogston A** (1984). "On Abscesses". *Classics in Infectious Diseases*. Rev Infect Dis 6 (1): 122–28.
- 2- Kluytmans J**, van Belkum A, Verbrugh H (1997). Nasal carriage of *Staphylococcus aureus*: epidemiology, underlying mechanisms, and associated risks. *Clin. Microbiol. Rev.* 10 (3): 505–20.
- 3. Wardenburg J. B.** and Schneewind O. (2007). Vaccine protection against *Staphylococcus aureus* pneumonia. *J. of Exp. Med.* 205 (2): 287-294.
- 4. Wardenburg, J.B.,** Bae T., Otto M., DeLeo F.R. and Schneewind O.(2007). Poring over pores: alpha-hemolysin and Panton-Valentine leukocidin in *Staphylococcus aureus* pneumonia. *Nat. Med.* 13:1405–1406.
- 5. Schneewind O,** Fowler A, Faull KF (1995). "Structure of the cell wall anchor of surface proteins in *Staphylococcus aureus*". *Science (journal)* 268 (5207): 103–6.
- 6. Patel AH,** Nowlan P, Weavers ED, Foster T (December 1987). "Virulence of protein A-deficient and alpha-toxin-deficient mutants of *Staphylococcus aureus* isolated by allele replacement". *Infect. Immun.* 55 (12): 3103–10.
- 7. Zhu J,** Lu C, Standland M, *et al.* (2008). "Single mutation on the surface of *Staphylococcus aureus* Sortase A can disrupt its dimerization". *Biochemistry* **47** (6): 1667–74.
- 8. Craven N. and Anderson J. C.** (1982). Experimental acute staphylococcal mastitis in the mouse: The influence of pathological changes on the kinetics and therapeutic action of cloxacillin. *J. of Comparative Patho.* 92 (4): 579-588.
- 9. Quinn, P.J;** Carter, M.E; Markey, B. & Carter, C,R.(1998). *Clinical Veterinary Microbiology*. Pp 261-267. M. Wolfe. London.
- 10. Fournier, B.** and Philpott, D.J. (2005). Recognition of *Staphylococcus aureus* by the innate immune system. *Clin. Microbiol. Rev.*, 18(3): 521-540.
- 11. Lowy, F.D.** (1998). *Staphylococcus aureus* infections. *New Engl. J. Med.*, 339: 520-532.
- 12. Projan, S.J.** and Novick, R.P. (1997). The molecular basis of pathogenicity. In: Crossly KB, Archer GL, editors. *The Staphylococci in human Disease*. New York: Churchill Livingstone, Pp: 55-81.
- 13. Flatt, R.E.** (1974): The biology of the laboratory rabbit. Eds. Weisbroth, S.H. Flatt, R.E. and Kraus, New York. Academic Press. P, 227..
- 14. Bhakdi, S.;** Muhly, M. ; Korom, S. and Hugo, F. (1989). Release of interleukin-1 beta associated with potent cytotoxic action of staphylococcal alpha-toxin on human monocytes. *Infect. Immun.*, 57: 12-3519.
- 15. Guidry , A.J.;** Oliver, S.P. ; Squiggins, K.E. ; Erbe, E.F. ; Dowlen, H.H. ; Hambleton, C.N. and Berning, L.M. (1991). Effect of anti-capsular antibodies on neutrophil phagocytosis of *S. aureus*. *J. Dairy Sci.*, 74: 3360-3369.
- 16. Peterson, P.K.;** Kim, Y. ; Wilkinson, B.J. ; Schmeling, D. ; Michael, A.F. and Quie, P.G. (1978b). Dichotomy between opsonization and serum complement activation by encapsulated staphylococci. *Infect. Immun.*, 20: 770-5.
- 17. Kenneth. T.** (2011). *Staphylococcus*. [textbookofbacteriology.net](http://textbookofbacteriology.net)
- 18. Joseph S.B.,** Bradley M.N., Castrillo A., Bruhn K.W., Mak P.A., Pei L., Hogenesch J., O'connell R.M., Cheng G., Saez E., Miller J.F., Tontonoz P. (2004). LXR-dependent gene expression is important for macrophage survival and the innate immuneresponse. *Cell*, 299-309.

19. **Joseph S.B.**, Castrillo A., Laffitte B.A., Mangelsdorf D.J., Tontonoz P.( 2003). Reciprocal regulation of inflammation and lipid metabolism by liver X receptors. Nat. Med. 9
20. **Owbald B.B.** (2008). Delvelopment of T cell immune response in B cell a deficient mice with enteric .Infection.Infect.Immun.71:6808-6819.
21. **Prabhu. P.** (2010). How *staph aureus* in the blood can cause fatal infections. Copyright © 2002-2011 Helium, Inc. All rights reserved. 200 Brickstone Square Andover, MA 01810 USA
22. **Lyle A. W.**, Amos C. M. and Rolla N. H. (1943). Fatal Staphylococcus Intoxication from Goat Milk. Indianapolis, Ind.Pp:1314-1318.
23. **Richard M.** (1997): Results AFIP Wednesday Slide Conference. No. 13-15 January. Diplomat, ACVP Department of pathology National Zoological Park Washington, D. C. 20008.
- 24.**Renquist, D.** and Soave, O. (2001): Staphylococcal pneumonia in laboratory rabbit: Israel Vet. Med. Vol. 56.
- 25.**Ajuwape, T.P.** and Aregbesola, E.A. (2002): The bacterial flora of the upper respiratory tract of normal rabbits Israel Vet. Med. Assoc. Vol. 57 (2).
26. **Michael A. E.**(1979). Results AFIP Wednesday Slide Conference - No. 10. The American Veterinary Medical Association and the American College of Veterinary Pathologists are co-sponsors of the Registry of Veterinary Pathology.
27. **Dalia, O.** Girgis; Joseph J. Dajcs and Richard J. O. Callaghan (2003): Phospholipase A2 activity in normal and staphylococcus infected rabbit eyes. Investigative ophthalmology visual science. 44:197-202.