

Case report: the First Diagnosis of Rabies in Iraq by using Direct Immunofluorescence Antibody Test

Majida Saeed Abdullah and Mazin Mahdi Naji

Iraqi Central Veterinary Laboratories, Veterinary Directorate, Ministry of agriculture, Iraq

E-Mail: majida.abdullah3@gmail.com

Accepted on: 29/1/2013

Summary

Rabies was diagnosed for the first time in Iraq in clinically suspected rabid ewe and dog (from Al-Basra governorate) by using the Direct Immunofluorescence Antibody Test (DFA). Fluorescent microscope inspection showed positive Rabies virus inclusions ranged between +3 to +4 scales, fluorescence, green apple in color, and dust or stars like particles scattered all over the tissue impression. Also the viral inclusions appeared round to oval in shape with different sizes which represent the typical morphology of the Rabies virus- antibody conjugates in DFA.

Keywords: Iraq, Rabies, FAT.

Introduction

During the late 1950s, diagnostic improvements allowed direct intervention and observation of brain material from the suspected animal without the need to wait for the development of histopathologically observable Negri bodies. Application of the direct fluorescence antibody technique (DFA) according to the current national standard protocol is rapid, sensitive, specific and inexpensive and eliminates the need for animal confinement to obtain reliable diagnostic result (1). The DFA test is based on the observation that animals infected by rabies virus have rabies virus proteins (antigen) present in their tissues. Because rabies is present in nervous tissue (and not blood like many other viruses), the ideal tissue to test for rabies antigen is brain (2). The most important part of a DFA test is fluorescently-labeled anti-rabies antibody. When labeled antibody is incubated with rabies-suspect brain tissue, it will bind to rabies antigen. Unbound antibody can be washed away and areas where antigen is present can be visualized as fluorescent-apple-green areas using a fluorescence microscope and if rabies virus is absent there will be no staining (3). The rabies antibody used for the DFA test is primarily directed against the nucleoprotein (antigen) of the Rabies virus replicates in the cytoplasm of cells, and infected cells may contain large round or oval inclusions containing collections of nucleoprotein or smaller collections of antigen that appear as dust-like

fluorescent particles if stained by the DFA procedure (4). Different immune-chemical methods have been developed to detect the virus or its antigens, but the most widely used method for diagnosing rabies infection in animals and humans and recommended by both World Health Organization (WHO) and World Organization for Animal Health (OIE) is the fluorescent antibody test. In this test brain tissue samples, smears or cells are treated with antirabies serum or globulin labelled with fluorescein isothiocyanate (FITC), preferentially polyclonal conjugates with fluorescence - labelled antibodies are used, and specific aggregates of rabies virus antigen are detected by their fluorescence using a reflected light (incident light) fluorescence microscope. The FAT is accurate, sensitive, rapid, and results can often be obtained within 1 to 2 hours of receipt of the specimen (5). As it's the recommended test by the reference laboratories, using of such test in the Iraqi once is so important and it must replace the histopathology which is the old method of diagnosis.

Materials and methods

Brain samples of clinically suspected rabid ewe and a Wolf dog were brought from Al-Basra governorate. Rabies DFA Kit: FITC Anti-Rabies Monoclonal Globulin (FDI-Fujirebio Diagnostics Inc. USA) kit were used

The Centers of Disease Control and Prevention protocol for Direct Fluorescence

Antibody Test was followed (3) for diagnosis cut sections were made in the brain stem, cerebellum and hippocampus. Pieces of 10-15 mm were taken from those specimens. Tissue impressions were made from the pieces of the brain stem, cerebellum, and hippocampus (duplicates of each cross section) on Teflon coated slides. Blotting of slides on paper towels was made to remove excess brain tissue, and then slides were air dried completely. Each set of slides from a specimen was placed in a separate container. Fixation was made in fresh acetone at -20°C for 1 hour. A set of negative control slide was fixed at the same time in separate containers (The negative control slides were made from a normal mouse brain). A set of positive control slide was fixed at the same time in separate container (The positive control slides were brought from Morocco Rabies Diagnosis Laboratory for conformation). Conjugates were prefiltered through low protein binding 0.45 μm filters.

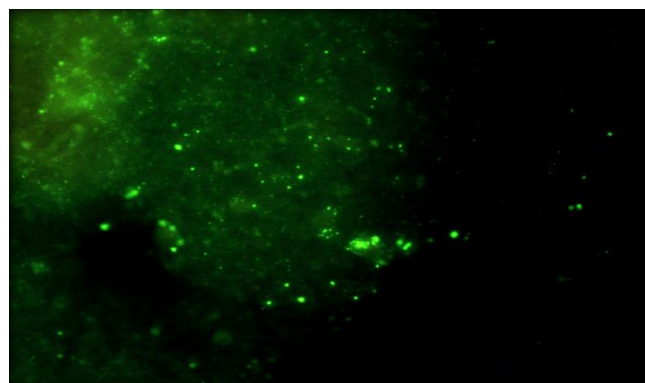
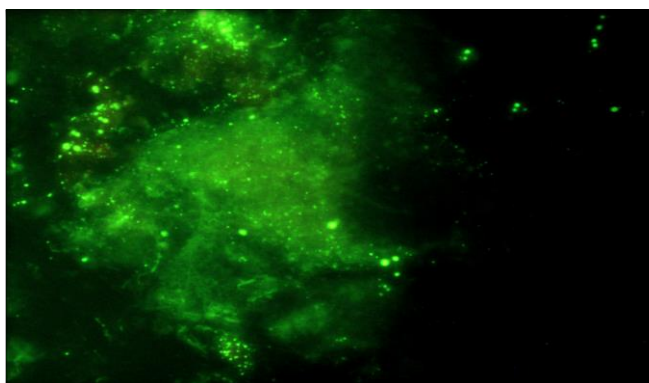
The conjugate was added to the test slides first, and then the negative control slides to insure that specific antibodies are not adsorbed by the filter in the initial drops. Test and control slides were incubated in a moist chamber at 37°C for 30 minutes. Each set of samples were placed in separate container for washes (coplin jars, centrifuge tubes or staining dishes). Immersing and soaking were made to slides in phosphate buffered saline (PBS) for 3-5 min, and then PBS is discarded

and replaced for additional 3-5 min. Then coverslips were blotted and mounted with 20 % Glycerol Tris Buffered Mounting Medium pH 9.0, and ultimately slides were examined with fluorescence microscope within 2 hours.

Results and Discussion

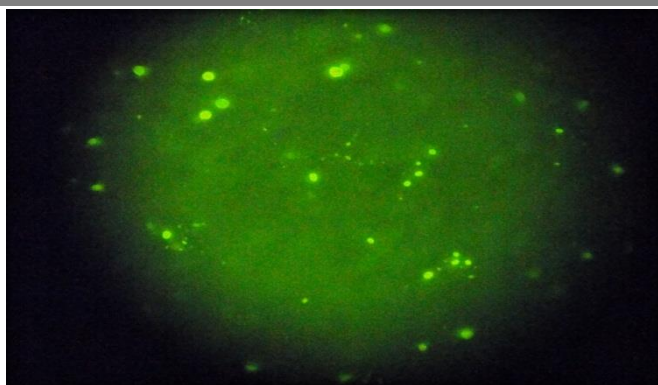
Impression slides (control and test) are judged on the basis of the following criteria (3): Intensity of the specific Rabies virus staining.

Fluorescence intensity (specific and non-specific) is graded on a negative to 4+ scales as follows: 4+ = brilliant apple-green fluorescence, 3+ = bright apple-green fluorescence, 2+ = dull apple-green fluorescence, 1+ = very dim detectable apple-green fluorescence, Negative = no apple-green fluorescence (3). Quantity of Rabies virus antigen stained is also rated on the negative to 4+ scales as follows: 4+ = antigen present in approximately 100% of the microscopic fields examined per impression, 3+ = antigen present in approximately 75% of the microscopic fields examined per impression, 2+ = antigen present in approximately 50% of the microscopic fields examined per impression, 1+ = antigen present in approximately 25% of the microscopic fields examined per impression, Negative = Rabies virus antigen absent in all fields examined per impression (3).



Figure, 1: DFA staining in cerebellum tissue impression of a rabid dog showed 4+ positive Rabies virus conjugates, brilliant apple green in color, star shape distribution and round to oval in shape.

Figure, 2: DFA staining in brain stem tissue impression of a rabid ewe showed 3+ positive Rabies virus conjugates, bright apple green in color, star shape distribution and round to oval in shape.



Figure, 3: DFA staining in brain tissue impression of the (+) control showed Rabies virus conjugates, bright apple green in color, star shape distribution and round to oval in shape.

Figure, 4: DFA staining in brain tissue impression of the (-) control showed dark field with no fluorescent activity.

The direct fluorescence antibody test is gold standard test and the recommended one for the diagnosis of Rabies mainly in the clinical laboratories. Studies have shown that the fluorescent antibody method for detection of Rabies may be more sensitive than the mouse inoculation test; however the result of the two tests is 99 - 100% correlative. This higher percentage of success comes from the phenomenon of Antigen-Antibody reaction, i.e. monoclonal anti - rabies antibodies conjugated with fluorescein isothiocyanate (FITC) are incubated with suspected virus infected tissue (6), and in the presence of Rabies virus, antigen-antibody complexes will form, but, if the tissue being examined contains no viral antigen, specific complexes will not be formed. Rabies virus-anti - rabies antibody complexes are visualized using a fluorescence microscope. Positive reactions demonstrate bright apple - green fluorescence of particles ranging in size and morphology from dust particles to prominent cytoplasmic inclusion Negri bodies (that seen as round to oval, eosinophilic bodies in light microscope) (7). The use of monoclonal antibodies in the FDI - FITC anti-rabies monoclonal globulin provides specific and uniform staining with reduced background staining (8).

Several tests are necessary to diagnose rabies antemortem (before death) in humans; no single test is sufficient. Tests are performed on samples of saliva, serum, spinal fluid, and skin biopsies of hair follicles at the nape of the neck. Saliva can be tested by virus isolation or reverse transcription followed by

polymerase chain reaction (RT-PCR). Serum and spinal fluid are tested for antibodies to rabies virus. Skin biopsy specimens are examined for rabies antigen in the cutaneous nerves at the base of hair follicles (9 and 10).

The direct fluorescent antibody test (DFA) is the test most frequently used to diagnose rabies and this test requires brain tissue from animals suspected of being rabid. The test can only be performed post-mortem (after the animal is dead). Histologic examination of biopsy or autopsy tissues is occasionally useful in diagnosing unsuspected cases of rabies that have not been tested by routine methods. In the recent research (our work) this method was used to detect Negri body in these two cases and to confirm the results of the FAT (11). Before current diagnostic methods were available, rabies diagnosis was made using this method and the clinical case history. In fact, most of the significant histopathologic features of rabies infection were described in the last quarter of the 19th century. After Louis Pasteur's successful experiments with rabies vaccination, scientists were motivated to identify the pathologic lesions of rabies virus (1). In regard to Immunohistochemistry (IHC) methods for rabies detection, these provide sensitive and specific means to detect rabies in formalin -fixed tissues. These methods are more sensitive than histologic staining methods, such as Hematoxylin and Eosin, and Sellers stains. Like the DFA test, IHC procedures use specific antibodies to detect rabies virus inclusions. While the other methods for Rabies virus detection such as the

techniques that use enzyme - labeling systems has increase the tests' sensitivity; in addition, the methods that use monoclonal antibodies may be used to detect rabies virus variants (12 - 14).

References

1. Jackson, A.C. and William, H.W. (2007). Rabies. 2nd .ed. Academic Press, Elsevier, San Diego, CA. USA.
2. Shankar, B.P. (2009). Advances in diagnosis of Rabies. Vet. World, 2 (2):74-78.
3. Centers of Diseases Control and Prevention, Department of Health and Human Services. Standard DFA Protocol for Rabies. Rabies Diagnosis in Animals. 2011.
4. Manual of Diagnostic Tests and Vaccines for Terrestrial Animals. Rabies. Chapter 2.2.5, 2010.
5. The WHO Collaboration Center for Rabies Surveillance and Research (2006). Diagnosis of Rabies in Animals. Rabies-Bulletin- Europe, 2:1-15.
6. Centers of Diseases Control and Prevention, Department of Health and Human Services. Standard DFA Protocol for Rabies. Rabies Diagnosis in Animals, 2012.
7. Protocol for postmortem diagnosis of rabies in animals by direct fluorescent antibody testing. A minimum standard for rabies diagnosis in the United States [cited 11 Jan 2006]. Available from <http://www.cdc.gov/ncidod/dvrd/rabies/>
8. Professional/publications/DFA_diagnosis/DFA_protocol-b.htm.
9. Tiziana L., Michael N., Andrés Velasco-Villa., Sarah C.E., and Rupprecht, C. E. (2006). Evaluation of a direct rapid immunohistochemical test for Rabies diagnosis. Emerging Infectious Diseases. 12: 2.
10. World Health Organization. Rabies Diagnosis in Humans. WHO Technical Report Series, Geneva, 2011.
11. Chiraz,T.; Phillip, L.; Marc. A.; Mehdi, E.; Nourlil,J.; and Abdellah, F.(2010). Phylodynamic and human-mediated dispersal of a zoonotic virus. PLOS Pathogens, 6 (10):156-167.
12. Abdullah, M.; Ensayf, T.; and Ouda, A. (2011). Case report: Histopathological diagnosis of Rabies in Iraqi cows and ewes. The Iraqi J.V.Med. 35(1).
13. Hamir, A.N.; Moser, Z.F.; Dietzschold, B. and Rupprecht, C.E. (1995). Immunohistochemical test for Rabies: identification of a diagnostically superior monoclonal antibody. Vet. Rec., 139: 295-296.
14. Centers of Diseases Control and Prevention, Department of Health and Human Services. Standard Operating Procedure, Direct Rabid Immunohistochemistry Test (DRIT) for the Detection of Rabies Virus Antigen, 2011.
15. Durr, S.; Naissengar, S.; Mindekem, R.; Diguimbye, C. and Niezgodá, M. (2008). Rabies Diagnosis for Developing Countries. PLOS Neglected Tropical Diseases, 2 (3): 206-211.

تقرير حالة مرضية: التشخيص الأول بالعراق لداء السعار بتقنية الأستشعاع المناعي المباشر

ماجدة سعيد عبدالله ومازن مهدي ناجي

المختبر المركزي- دائرة البيطرة - وزارة الزراعة - العراق

الخلاصة

تم تشخيص داء السعار في العراق لأول مرة في نعجة و كلب (من محافظة البصرة) مشكوك سريريا بإصابتها بداء السعار باستخدام تقنية الأستشعاع المناعي المباشر. أظهر الفحص بجهاز المجهر المشع (الفلورسنت مايكروسكوب) نتيجة موجبة لتواجد معقدات التفاعل المكونة من حمه داء السعار والأضداد الخاصة به بدرجات تتراوح ما بين +3 و +4. وكانت المعقدات بشكل دائري الى بيضوي مختلفة الأحجام وذات لون كلون التفاح الأخضر ومشعة ومنتشرة على كل المقاطع النسيجية بشكل مشابه لذرات الغبار أو النجوم وهي الصفات المميزة للمعقدات المكونة كنتيجة للتفاعل بين المستضدات (حمه داء السعار) والأضداد (الأضداد الخاصة بحمه داء السعار) في فحص الأستشعاع المناعي المباشر.

الكلمات المفتاحية: العراق, داء السعار, فحص الأستشعاع المناعي المباشر.